

**Sarcocystis AND RELATED ORGANISMS IN
AUSTRALIAN WILDLIFE: III. Sarcocystis murinotechis
SP.N. LIFE CYCLE IN RATS (Rattus, Pseudomys and
Mastocomys SPP.) AND TIGER SNAKES (Notechis ater).**

Authors: MUNDAY, B. L., and MASON, R. W.

Source: Journal of Wildlife Diseases, 16(1) : 83-87

Published By: Wildlife Disease Association

URL: <https://doi.org/10.7589/0090-3558-16.1.83>

BioOne Complete (complete.BioOne.org) is a full-text database of 200 subscribed and open-access titles in the biological, ecological, and environmental sciences published by nonprofit societies, associations, museums, institutions, and presses.

Your use of this PDF, the BioOne Complete website, and all posted and associated content indicates your acceptance of BioOne's Terms of Use, available at www.bioone.org/terms-of-use.

Usage of BioOne Complete content is strictly limited to personal, educational, and non - commercial use. Commercial inquiries or rights and permissions requests should be directed to the individual publisher as copyright holder.

BioOne sees sustainable scholarly publishing as an inherently collaborative enterprise connecting authors, nonprofit publishers, academic institutions, research libraries, and research funders in the common goal of maximizing access to critical research.

Sarcocystis AND RELATED ORGANISMS IN AUSTRALIAN WILDLIFE: III. *Sarcocystis murinotrichis* SP.N. LIFE CYCLE IN RATS (*Rattus*, *Pseudomys* and *Mastacomys* SPP.) AND TIGER SNAKES (*Notechis ater*).

B. L. MUNDAY and R. W. MASON, Mt. Pleasant Laboratories, P.O. Box 46, Launceston South, Tasmania, Australia.

Abstract: Sporocysts from tiger snakes (*Notechis ater*) produced thick-walled sarcocysts in laboratory rats (*Rattus norvegicus*). Ultrastructurally these organisms were identical with sarcocysts found in native rats, but were different from *Sarcocystis singaporensis*. *Sarcocystis murinotrichis* sp.n. is proposed for this parasite of rodents and tiger snakes.

When naturally-infected rats were fed to kittens (*Felis domestica*), quolls (*Dasyurus viverrinus*) and a masked owl (*Tyto novaehollandiae*) no sporocysts were detected in the faeces of these animals. Also, sporocysts from owls (*T. novaehollandiae* and *Ninox novaeseelandiae*) were not infective for rats (*R. norvegicus*).

INTRODUCTION

Both Rzepczyk³ and Zaman and Colley⁵ have described thick-walled *Sarcocystis* of rats which have pythons as definitive hosts. Originally, Zaman and Colley⁵ named their organism *Sarcocystis orientalis*, but subsequently changed this to *S. singaporensis* sp.n.⁶ Electron-microscopic examination of this organism and Rzepczyk's type A *Sarcocystis* revealed that they had similar cyst walls composed of villi approximately $4.8.7 \times 0.3.1.4 \mu\text{m}$.^{4,5} Thick-walled sarcocysts were also found in Tasmanian rats (*Rattus lutreolus*, *R. rattus*, *R. norvegicus*, *Pseudomys higginsii* and *Mastacomys fuscus*)² but the walls on these had villi measuring $6 \times 4 \mu\text{m}$ and, in contrast to those seen in *S. singaporensis*, the villi did not have basal necks.¹ As a consequence of these morphological differences and the fact that pythons do not occur in Tasmania an attempt was made to elucidate the life cycle of this organism.

MATERIALS AND METHODS

Carnivore Studies

Two kittens (*Felis domestica*), two quolls (*Dasyurus viverrinus*) and a

masked owl (*Tyto novaehollandiae*) were fed naturally-infected rats. Each kitten and each quoll was fed half an eastern swamp rat (*R. lutreolus*) and half a long-tailed rat (*P. higginsii*) whilst the masked owl was fed four swamp rats and one long-tailed rat.

The kittens were derived from experimental groups which had not been fed raw meat. The quolls and owls were captive animals.

All examinations for sporocysts typical of *Sarcocystis* or *Frenkelia* were performed on the material obtained by subjecting the animals' faeces to flotation on sugar solution (sp.g. 1.15) followed by a single washing. Flotations were examined daily for a week prior to feeding and for three weeks after feeding (weekend samples were pooled).

Studies using *R. norvegicus* and *Mus musculus*

Laboratory rats (*R. norvegicus*) and mice (*M. musculus*) known not to harbour sarcocysts were used in these studies.

In the first series of experiments sporulated oocysts and sporocysts collected from the intestines of three tiger snakes (*Notechis ater*) were used. These were stored in antibiotic solution until

needed, when they were washed, suspended in physiological saline and counted in a haemocytometer.

For the first experiment, three rats were each given 30,000 sporocysts orally and an unquantified dose was administered to a fourth. Three rats were caged separately as uninoculated controls. In the second experiment, five rats and five mice were given graded, but unquantified, doses of sporocysts. Five rats and five mice were kept in separate cages as controls. All animals, except those which died early in the course of the experiments, were killed and examined 12 weeks post-inoculation (p.i.). Post-mortem examinations were performed and a range of tissues fixed in 10% buffered formalin for histologic examination. Sections 10 μm thick were cut from paraffin-embedded tissues selected from brain, lungs, liver, kidneys, tongue, oesophagus, heart, diaphragm and skeletal muscle. These were stained with haematoxylin and eosin for light microscopic examination. Electron microscopic examination of *Sarcocystis*-infected muscle was undertaken after post-fixing in osmium, embedding in Spurr's medium and staining with uranyl acetate and lead citrate.

In the second series of experiments, sporulated oocysts and sporocysts collected from the intestines of a masked owl (*Ninox novaeseelandiae*) and a spotted owl (*Ninox novaeseelandiae*) were used as inocula. Large, unquantified doses of sporocysts from the masked owl were given to 17 mice and seven rats. Similarly, large numbers of sporocysts from the spotted owl were given to six mice and four rats. Equal numbers of control animals were caged separately. The same examination protocol was used as in the first series of experiments.

RESULTS

Carnivore Studies

Sporocysts were not found in the faeces of animals fed native rats infected with *Sarcocystis*.

Studies Using *R. norvegicus* and *M. musculus*

First series of experiments. The sporocysts obtained from the tiger snakes averaged $11.0 \times 7.25 \mu\text{m}$ (range $10.5\text{--}11.5 \times 7\text{--}8 \mu\text{m}$) and contained four sporozoites and numerous residual granules.

Three of the nine rats died at seven to 13 days p.i. At necropsy, they had excessive pleural fluid and oedematous lungs. Histopathologic examination revealed pulmonary oedema, focal non-suppurative myocarditis and anoxic hepatopathy. Schizonts (Figure 1) measuring $9 \times 9 \mu\text{m}$ to $29 \times 11.5 \mu\text{m}$ were found in varying numbers in the different rats. In the heaviest infection the order of density was myocardium = skeletal muscle > lung > kidney glomerulus. The remaining inoculated rats had thick-walled sarcocysts in the tongue, diaphragm and skeletal muscles, but not in the heart at 12 weeks p.i. These sarcocysts were 60–90 μm in diameter and up to 300 μm in length, although as none

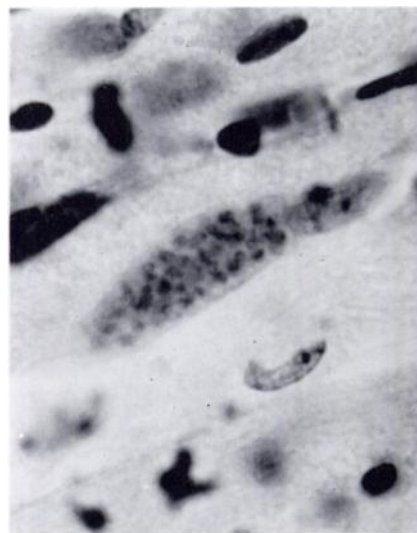


FIGURE 1. Schizont in tongue of laboratory rat (*Rattus norvegicus*). H&E $\times 3750$

were cut perfectly longitudinally they were probably longer. With the light microscope, the cyst wall appeared striated and electron-microscopy revealed the presence of short, broad ($6 \times 4 \mu\text{m}$) protrusions with many in-

vaginations, but without necks at their bases (Figure 2). Sarcocysts were not detected in the control rats.

Two of the five mice died at 14 days p.i. and showed similar lesions to the rats except that there was significant

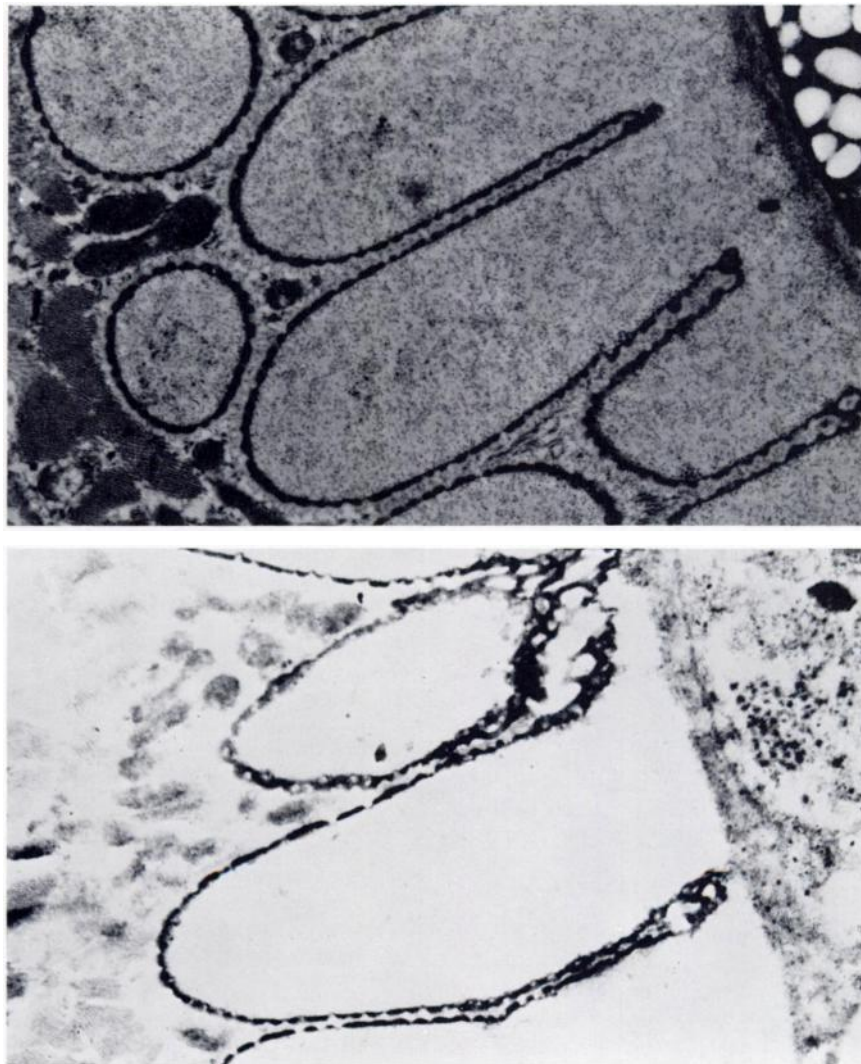


FIGURE 2. Wall of *Sarcocystis murinotechis* sp.n. in laboratory rat (*R. norvegicus*) (above) and southern bush rat (*R. fuscipes*) (below). Note short, broad protrusions. Electronmicrograph $\times 13500$

myositis in the skeletal muscles. A single, thick-walled sarcocyst, 95 μm in diameter was found in the skeletal muscles of one mouse 12 weeks p.i.

Second series of experiments. The sporocysts obtained from the owls averaged $13 \times 8 \mu\text{m}$ (range $12\text{--}16 \times 7.5\text{--}8.5 \mu\text{m}$).

No sarcocysts, nor developmental stages, were found in the experimental rats and mice dosed with owl sporocysts.

DISCUSSION

In this series of experiments it has been shown that sporocysts from tiger snakes (*N. ater*) produce sarcocysts in laboratory rats (*R. norvegicus*). These sarcocysts are histologically identical to those found in eastern swamp rats (*R. lutreolus*), southern bush rats (*R. fuscipes*), black rats (*R. rattus*), Norway rats (*R. norvegicus*), long-tailed rats (*P. higginsii*) and broad-toothed rats (*Mastacomys fuscus*) in Tasmania and south-eastern Australia.² In addition, the experimental sarcocysts are ultra-microscopically identical to those from *R. lutreolus*² and *R. fuscipes* (Munday, unpubl.) but distinct from *S. singaporensis*⁶ and Rzepczyk's type A organism.⁴ On the basis of these differences in morphology and definitive host, it is suggested that it is a new species and the name *Sarcocystis murinotechis* sp.n. is proposed.

The specificity of this parasite for reptiles as definitive hosts was at least partially demonstrated by the fact that feeding of infected rats did not lead to sporocyst production in quolls, kittens and a masked owl, nor were sporocysts from owls infective for rats.

Although this particular *Sarcocystis* has not been found in wild mice (*Mus musculus*)² it can develop to some extent in this rodent possibly suggesting an even wider intermediate host range than has already been found. The relationship of *S. murinotechis* to Rzepczyk's type A sarcocyst (? *S. singaporensis*) is of in-

terest. Limited evidence² suggests that the distribution of the latter organism is related to the range of its python hosts² (Munday, unpubl.). The occurrence of *S. murinotechis* outside this range suggests that it is principally carried by tiger snakes and possibly other elapid snakes.

Diagnosis of *Sarcocystis murinotechis*

Type locality: South eastern Australia.

Type definitive host: Tiger snake, *Notechis ater*.

Type intermediate hosts: Eastern swamp rat, *Rattus lutreolus*; southern bush rat, *R. fuscipes*; black rat, *R. rattus*; Norway rat, *R. norvegicus*; long-tailed rat, *Pseudomys higginsii*; broad-toothed rat, *Mastacomys fuscus*.

Experimental intermediate host: Norway (laboratory) rat, *R. norvegicus*.

Habitats: Asexual forms in *Rattus*, *Pseudomys* and *Mastacomys* spp. Sexual stages in the intestines of tiger snakes (*N. ater*). Sporocysts in snakes' faeces contaminating wilderness and farming areas frequented especially by native rats (*R. lutreolus*, *R. fuscipes*, *P. higginsii*, *M. fuscus*).

Description: Early sexual stages unknown. Sporocysts occur in pairs or singly, $11.0 \times 7.25 \mu\text{m}$, containing four sporozoites and numerous residual granules. Schizogony in heart and other tissues followed by sarcocyst production in tongue, diaphragm and skeletal muscles. Cysts at least 300 μm in length, 60-90 μm in diameter with a wall composed of protrusions $6 \times 4 \mu\text{m}$. Muscle cysts are not infective for cats, quolls (*Dasyurus viverrinus*) or masked owls (*Tyto novaehollandiae*). Sporocysts are easily infective for *R. norvegicus*.

Type material: Slides of natural and experimental infections in rats are lodged with the Queen Victoria Museum, Launceston, Tasmania registered numbers 1979/22/1-6, Q.V.M. types 351-6.

Acknowledgements

The author wishes to thank Mr. R.H. Green, Queen Victoria Museum, Launceston, Dr. D. Spratt, CSIRO, Canberra and Messrs. G. Goodsall, M. Kelp and M. Tyson, Tasmanian Department of Agriculture, Launceston for providing specimens and/or giving technical assistance. Dr. W.J. Hartley, University of Sydney and Mr. D. Munro, Newtown Research Laboratories, Hobart supplied the electronmicrographs. Publication of this paper was funded by the Australian Meat Research Committee.

LITERATURE CITED

1. MELHORN, H., W.J. HARTLEY and A.O. HEYDORN. 1976. A comparative ultrastructural study of the cyst wall of 13 *Sarcocystis* species. *Protoplastologia* XII: 451-467.
2. MUNDAY, B.L., R.W. MASON, W.J. HARTLEY, P.J.A. PRESIDENTE and D. OBENDORF. 1978. *Sarcocystis* and related organisms in Australian wildlife: I. Survey findings in mammals. *J. Wildl. Dis.* 14: 417-433.
3. RZEPCZYK, C.M. 1974. Evidence of a rat-snake cycle for *Sarcocystis*. *Int. J. Parasit.* 4: 447-449.
4. ——— and E. SCHOLTYSECK. 1976. Light and electron microscope studies on the *Sarcocystis* of *Rattus fuscipes*, an Australian rat. *Z. Parasitenk.* 50: 137-150.
5. ZAMAN, V. and F.C. COLLEY. 1975. Light and electron microscopic observations on the life cycle of *Sarcocystis orientalis* sp.n. in the rat (*Rattus norvegicus*) and the Malaysian reticulated python (*Python reticulatus*). *Z. Parasitenk.* 47: 169-185.
6. ——— and ———. 1976. Replacement of *Sarcocystis orientalis* Zaman and Colley, by *Sarcocystis singaporensis* sp.n. *Z. Parasitenk.* 51: 137.

Received for publication 6 March 1979