

TUBERCULOSIS IN A RED-TAILED HAWK (BUTEO JAMAICENSIS)

Author: SYKES, G.P.

Source: Journal of Wildlife Diseases, 18(4) : 495-499

Published By: Wildlife Disease Association

URL: <https://doi.org/10.7589/0090-3558-18.4.495>

BioOne Complete (complete.BioOne.org) is a full-text database of 200 subscribed and open-access titles in the biological, ecological, and environmental sciences published by nonprofit societies, associations, museums, institutions, and presses.

Your use of this PDF, the BioOne Complete website, and all posted and associated content indicates your acceptance of BioOne's Terms of Use, available at www.bioone.org/terms-of-use.

Usage of BioOne Complete content is strictly limited to personal, educational, and non - commercial use. Commercial inquiries or rights and permissions requests should be directed to the individual publisher as copyright holder.

BioOne sees sustainable scholarly publishing as an inherently collaborative enterprise connecting authors, nonprofit publishers, academic institutions, research libraries, and research funders in the common goal of maximizing access to critical research.

TUBERCULOSIS IN A RED-TAILED HAWK (*BUTEO JAMAICENSIS*)

G.P. SYKES, Department of Pathology, New York State College of Veterinary Medicine, Cornell University, Ithaca, New York 14853, USA.

Avian tuberculosis (ATB) has been sporadically reported in birds of prey both from zoological collections and the wild. Members of the order Falconiformes which have been reported to have mycobacterial infections include the common kestrel (*Falco tinnunculus*) (Wilson, 1960, Br. Vet. J. 116: 380-393; Kronberger et al., 1976, In: *XVIII Internationalen Symposiums uber die Erkrankungen der Zootiere*, Innsbruck, Germany, pp. 167-169), European sparrow hawk (*Accipiter nisus*) (Harrison, 1948, J. Pathol. Bacteriol. 60: 583-586), brown falcon (*Falco berigora*) (Rac, 1951, Aust. Vet. J. 27: 209), lanner falcon (*Falco biarmicus*) (Halliwell and Graham, 1978, In: *Zoo and Wild Animal Medicine*, Fowler (ed.), W.B. Saunders Co., Philadelphia, Pennsylvania, pp. 265-273), red-tailed hawk (*Buteo jamaicensis*) (Emerson et al., 1970, J. Am. Vet. Med. Assoc. 157: 606), "vulture" (Wilson, op. cit.) and golden eagle (*Aquila chrysaetos*) (Wilson, op. cit.). Affected species of the order Strigiformes include the barn owl (*Tyto alba*) (Bucke and Mawdesley-Thomas, 1974, Vet. Rec. 95: 373) and the long-eared owl (*Asio otus*) (Kronberger et al., op. cit.). Most of these cases were not cultured and only two reports mention serotypes.

This paper describes the lesions associated with *Mycobacterium avium* serotype 2 infection in a red-tailed hawk.

A mature female red-tailed hawk was found in a wooded area near Watkins Glen, New York on September 7, 1981. The bird could not fly, was depressed and markedly cachectic. It was admitted to the avian clinic of the New York State College of Veterinary Medicine at Cor-

nell University and given supportive treatment until it died 4 days later.

At necropsy the carcass weighed 710 g and was emaciated with serous atrophy of fat stores. The pectoral muscles were severely atrophied producing a prominent keel. The liver contained many firm pale tan granulomas which ranged in size from less than 1mm to 8mm in diameter (Fig. 1). The larger granulomas had caseous centers which were crumbly and easily removed. In no instance was there cavitation or mineralization of the granulomas. The spleen was large, pale tan and spherical and measured 40mm in diameter. Except for a thin connective tissue capsule, the spleen was completely necrotic (Fig. 2). The small intestine was palpably and visibly thickened in some areas and there were multiple irregular soft tan granulomas in the adjacent mesentery.

Several granulomas, similar to those in the mesentery, were present beneath the parietal pleura of the sternum. The lungs and air sacs appeared uninvolved. Both thyroids were surrounded by granulomas. A single discrete nodule measuring 3mm in diameter was present in the ventro-medial border of the retobulbar space. Several small granulomatous plaques up to 2mm in diameter were visible in the meninges and on the surface of the cerebrum. The cut surface of the cerebrum had multiple slightly darkened malacic foci. A single 3mm diameter granuloma was present in the endocardium at the apex of the right ventricle.

Histological examination of the liver revealed typical mycobacterial granulomas (tubercles) (Fig. 3). The

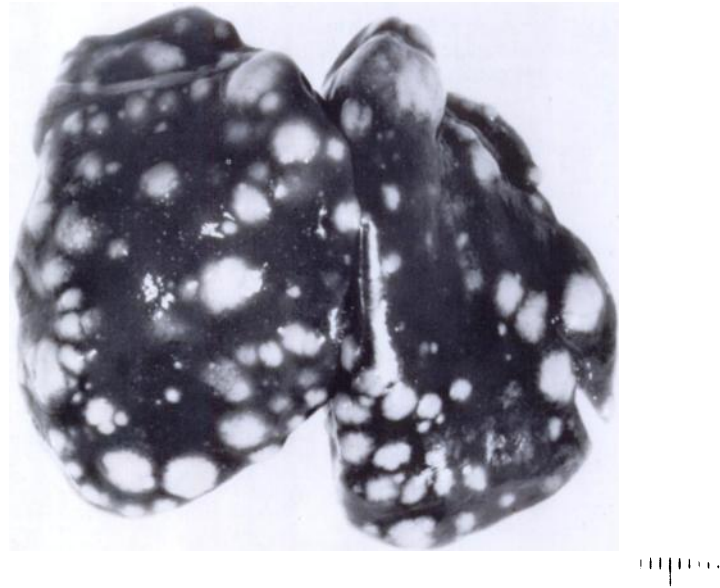


FIGURE 1. Liver. Multiple granulomas (tubercles) are present throughout the parenchyma. Bar = 10mm.

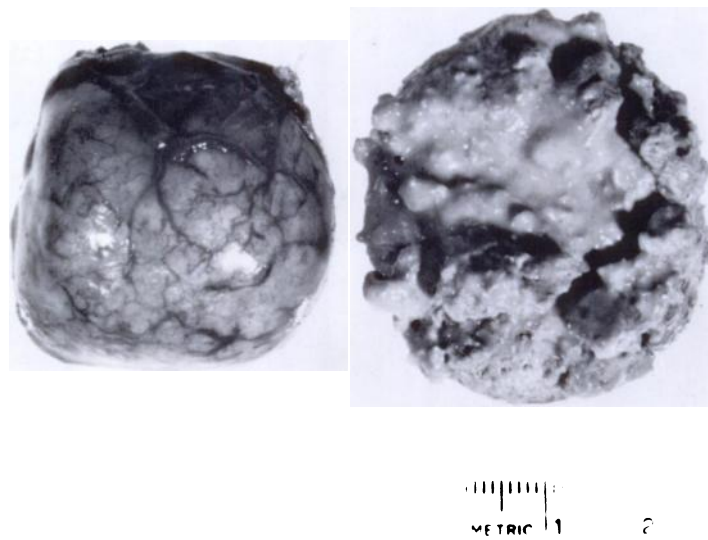


FIGURE 2. Spleen. The cut surface is on the right and the serosal surface is on the left. The organ is markedly enlarged and the normal parenchyma is completely replaced with confluent necrotic granulomas.

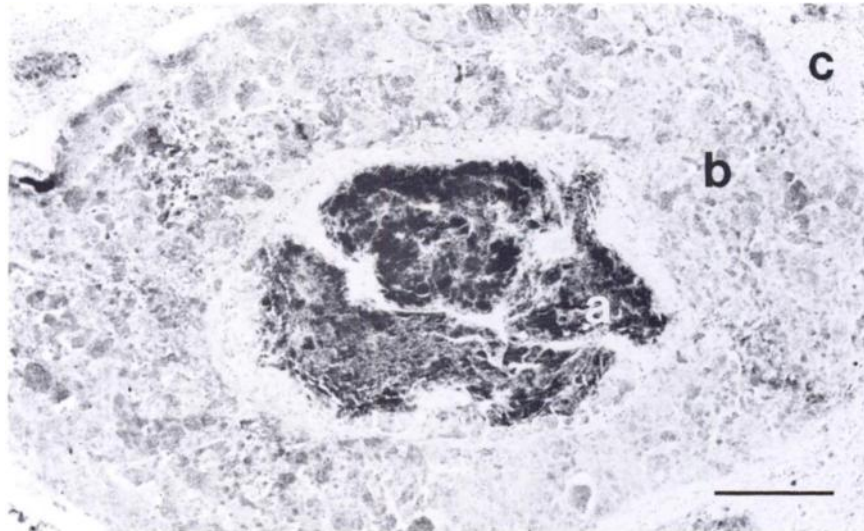
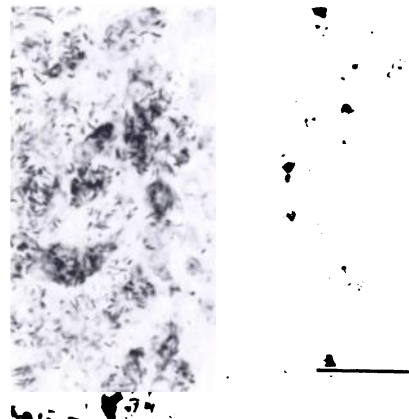


FIGURE 3. Hepatic granuloma. A. This acid-fast stain demonstrates the massive numbers of acid-fast bacilli within the necrotic central core (a). This core is surrounded by a mass of viable histiocytes laden with bacilli (b). Normal hepatocytes (c) surround the granuloma. Ziehl-Neelsen stain. Bar = 200 μ m. B. This higher magnification of the edge of a granuloma shows the acid-fast bacilli within histiocytes. Normal hepatocytes are to the right. Ziehl-Neelsen stain. Bar = 20 μ m.



smaller granulomas consisted of islands of histiocytes with abundant finely granular cytoplasm. Their nuclei, which were often multiple, were displaced to the cell periphery. The granular particles in the cytoplasm were identified as acid-fast bacilli with Ziehl-Neelsen stain (Fig. 3b). The caseous center of the larger granulomas was composed of sheets of acid-fast bacilli and occasional remnant plasma membranes from necrotic histiocytes. All granulomas were surrounded by normal hepatic parenchyma. Scattered histiocytes containing acid-fast organisms were present throughout the parenchyma. Several histiocytic

aggregates of different sizes were also present in the walls of the hepatic veins (Fig. 4). Larger aggregates caused proportionately greater vascular occlusion and resembled the smaller parenchymal granulomas.

The splenic parenchyma was totally replaced by confluent necrotic granulomas that were surrounded by a thin fibrovascular capsule. The intestinal mucosa was thickened by a patchy infiltration of the lamina propria by histiocytes laden with acid-fast bacilli (Fig. 5). Affected

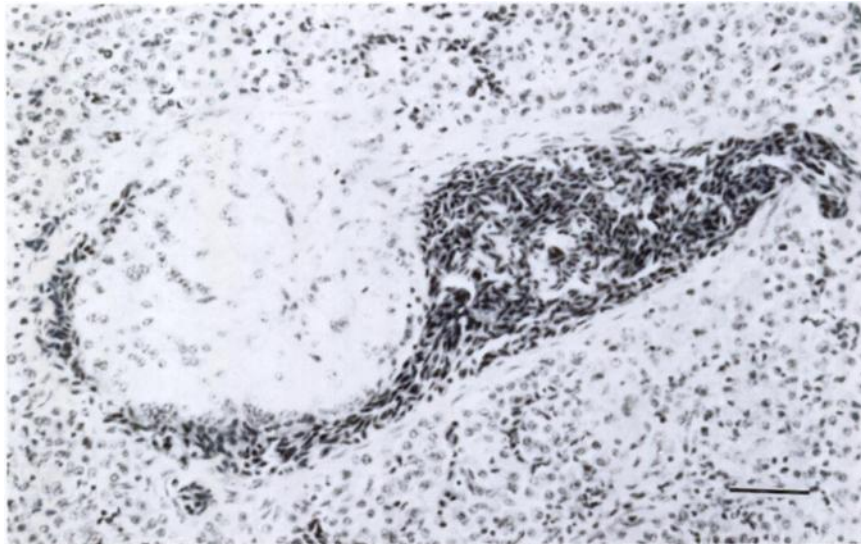


FIGURE 4. Hepatic vein. A granuloma consisting of typical foamy histiocytes is forming in the intima. These masses eventually obliterated vessels and acquired the necrotic core of parenchymal tubercles. H & E stain. Bar = 50 μ m.

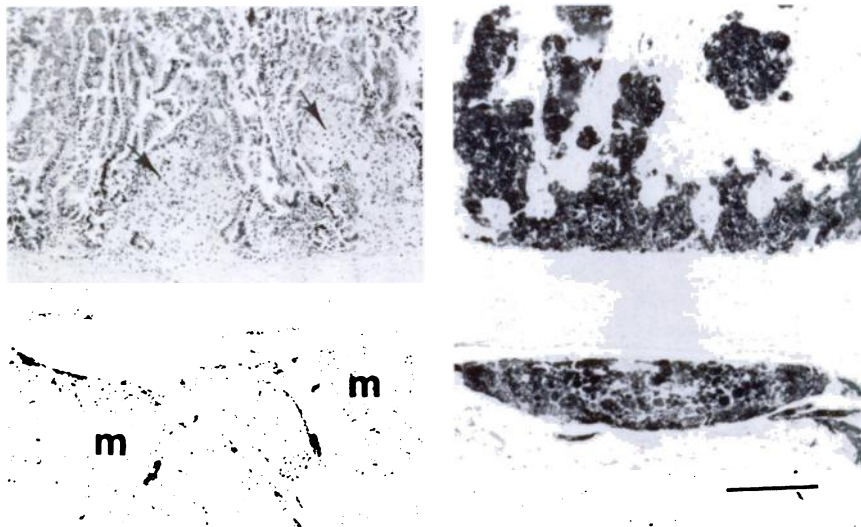


FIGURE 5. Small intestine. A. Foamy histiocytes demonstrate patchy infiltration of the lamina propria (arrows). Numerous granulomas in the attached mesentery are composed of the same cell type (m). H & E stain. B. The acid-fast stain demonstrates the massive number of mycobacteria within the foamy histiocytes. Ziehl-Neelsen stain. Bar = 200 μ m.

villi were usually blunted and the lesions closely resembled those of Johne's Disease in cattle. The granulomatous infiltrate in this case was not observed to extend beyond the muscularis mucosae. Serosal granulomas were confined to the mesenteric border and extended into the mesentery. The larger mesenteric granulomas often had small necrotic centers.

Tuberculous granulomas were also seen in the brain, meninges, bone marrow, sternal subpleura, retrobulbar space and thymic lymphoid tissue surrounding the thyroid glands. A very small granuloma was histologically identified in the pecten of the left eye.

A small piece of liver tissue was cultured on Sabouraud's dextrose agar. After 5 wk at 30 C no growth was apparent. However, after an additional 3 wk at room temperature (24 C), acid fast bacilli were present in gross colonies. The slant was submitted to the NADL at Ames, Iowa where the organism was identified as *Mycobacterium avium*, serotype 2. Sabouraud's dextrose agar is not the medium of choice for isolation of *Mycobacterium avium* and the isolation in this case was fortuitous. Most laboratories are not equipped for the isolation and identification of mycobacteria and immediate submission to a reference laboratory such as the NADL is advised when tuberculosis is suspect. Thoen (1978, In: *Mycobacterial Infections of Zoo Animals*, Montali (ed.).

Smithsonian Inst. Press, Washington, D.C., pp. 99-101) recommends that mailed specimens be placed in a saturated solution of sodium borate to minimize the growth of contaminants.

The lesions of ATB reported here in a red-tailed hawk are similar to those described in captive exotic birds by Montali et al. (1976, J. Am. Vet. Med. Assoc. 169: 920-927). Although involvement of the pecten and brain is unique in this case, it is not surprising considering the multi-organ distribution of the granulomas in most cases. The brief note on tuberculosis in a red-tailed hawk by Emerson et al. (op. cit.) only described gross lesions in the liver, intestine and mesentery. In this latter case the mesenteric granulomas were so extensive that "the intestines were entwined in a mass of sac-like nodules that contained a thick brown exudate". *M. avium* serotype 2 was also the isolate in this red-tailed hawk as it was in a lanner falcon (Halliwell and Graham, op. cit.). The isolation of serotype 2 from all three birds of prey reported thus far contrasts with the isolation of only serotype 1 in the 31 exotic birds cultured by Montali et al. (op. cit.). This difference in the serotype may be significant in the epidemiology of the disease or represent different species susceptibility.

The author thanks Christopher Gibbons and Barbara Dimock for their assistance and the NADL, Ames, Iowa for identification of the mycobacteria.

Received for publication 9 April 1982