

## **PARASITES OF THE BALD EAGLE (HALIAEETUS LEUCOCEPHALUS) OF NORTH AMERICA**

Authors: Tuggle, Benjamin N., and SCHMELING, SHEILA K.

Source: Journal of Wildlife Diseases, 18(4) : 501-506

Published By: Wildlife Disease Association

URL: <https://doi.org/10.7589/0090-3558-18.4.501>

---

BioOne Complete ([complete.BioOne.org](https://complete.BioOne.org)) is a full-text database of 200 subscribed and open-access titles in the biological, ecological, and environmental sciences published by nonprofit societies, associations, museums, institutions, and presses.

Your use of this PDF, the BioOne Complete website, and all posted and associated content indicates your acceptance of BioOne's Terms of Use, available at [www.bioone.org/terms-of-use](https://www.bioone.org/terms-of-use).

Usage of BioOne Complete content is strictly limited to personal, educational, and non - commercial use. Commercial inquiries or rights and permissions requests should be directed to the individual publisher as copyright holder.

---

BioOne sees sustainable scholarly publishing as an inherently collaborative enterprise connecting authors, nonprofit publishers, academic institutions, research libraries, and research funders in the common goal of maximizing access to critical research.

## PARASITES OF THE BALD EAGLE (*HALIAEETUS LEUCOCEPHALUS*) OF NORTH AMERICA

BENJAMIN N. TUGGLE and SHEILA K. SCHMELING, National Wildlife Health Laboratory, 6006 Schroeder Road, Madison, Wisconsin 53711, USA.

Information concerning parasites of the bald eagle (*Haliaeetus leucocephalus*) in North America is relatively sparse. Since the bald eagle in parts of the United States is an endangered species, collection of eagles for parasitological study is difficult. There have been several singular reports of parasites found in or on bald eagles in the literature. However, Kocan and Locke (1974, J. Wildl. Dis. 10: 8-10) reported the first survey of helminths collected from dead and moribund bald eagles they examined from 1963-1971.

Since dead and moribund eagles are collected and submitted to the National Wildlife Health Laboratory (NWHL) for necropsy to determine factors that contribute to their mortality, the opportunity was provided to collect and identify endoparasites and ectoparasites observed during routine necropsy. This paper summarizes the parasites found in bald eagles examined from 1979-1981.

Parasite specimens were obtained from a total of 84 bald eagles collected from 18 states. All helminth parasites were fixed in AFA (alcohol-formalin-acetic acid). Trematodes and acanthocephala were stained with Semichon's carmine and mounted. Nematodes were cleared in glycerine. Ectoparasites were fixed in 70% alcohol and cleared in 10% KOH before being mounted. Wet smears made from intestinal scrapings were examined at 140 and 1000 $\times$  magnification to detect the presence of protozoan parasites. Bald eagle specimens submitted to NWHL were not used exclusively for parasitological examinations, thus metazoan parasite specimens were collected by sight. Fine-mesh screens were not used.

Parasites recovered from bald eagle hosts are shown in Table 1. One protozoan, two genera of Trematoda, one genus of Acanthocephala, seven genera of Nematoda, and three genera of Mallophaga were reported. New host records are indicated in the table by an asterisk. Female *Contracaecum* found without males or those that were found as larval stages were identified only to genus. Helminths of the genera *Eustrongylides*, *Paracuarina*, and *Tetrameres* were also reported as genera since only females were found.

Kocan and Locke (op.cit.) reported nine genera of helminth parasites from bald eagles from North America and Canada. Five parasite species (*Phagicola longus*, *Neodiplostomum banghami*, *Neogogatea pandionis*, *Cladotaenia banghami*, and *Capillaria contorta*) found in their study were not observed in our survey; however, six genera not previously reported are listed.

The protozoan parasite found in several of the eagles in our study is reported as a *Sarcocystis*-like species (Fig. 1). The oocysts observed in intestinal smears were sporulated and disporocystic; however, single sporocysts were observed without oocyst walls. This was probably due to the thin wall ( $< 1 \mu\text{m}$ ) of the oocysts rupturing under pressure and releasing the solitary sporocysts. Each sporocyst, lacking steidia bodies, contained four elongated sporozoites and numerous rounded granules (Figs. 2 and 3).

Mean length and width measurements of 80 oocysts were  $20.1 \pm 0.7 \mu\text{m}$  (range 18.9-21.7) and  $15.8 \pm 0.7 \mu\text{m}$  (range 14.5-16.9) and for sporocysts,  $15.4 \pm 0.5 \mu\text{m}$

TABLE 1. Parasites recovered from *Haliaeetus leucocephalus* from 1979-1981.

Parasite	Site in Host <sup>a</sup>	Age <sup>b</sup>	Sex	Cause of Death	State of Collection <sup>c</sup>
<b>PROTOZOA</b>					
* <i>Sarcocystis</i> -like sp.	SI	I	M	Enteritis	CA
	SI	I	?	Undetermined	AK
	SI	A	M	Trauma	AK
	SI	A	M	Emaciated	AK
	SI	A	F	Lead poisoning	CO
<b>TREMATODA</b>					
<i>Clinostomum complanatum</i> (76991) <sup>d</sup>	T	I	M	Shot	MI
	T	I	M	Blunt trauma	WI
	T	I	F	Shot	MN
	T	I	F	Peritonitis	WI
	T	I	F	Undetermined	WI
	T	I	F	Electrocution	IA
	T	I	F	Emaciated	IA
	T	S	F	Electrocution	FL
	T	S	F	Electrocution	FL
	T	A	M	Enteritis	WI
	T	A	F	Aspergillosis	WI
	S	N	F	Pneumonia	OR
	SI	A	F	Shot	FL
<b>*<i>Ribeiroia ondatrae</i> (76992)</b>					
<b>ACANTHOCEPHALA</b>					
<i>Centrorhynchus</i> sp. (76993)	P	A	F	Strychnine	AK
<b>NEMATODA</b>					
* <i>Eustrongylides</i> sp. (76994)	S	I	M	Shot	AZ
<i>Contracaecum</i> sp. (76995)	S	I	M	Blunt trauma	MN
	S	I	F	Hit by car	FL
	S	I	F	Blunt trauma	FL
	S	I	F	Undetermined	SD
	S	I	?	Shot	MO
	S	?	?	Aspergillosis	FL
	S	S	M	Pneumonia	MI
	S	S	F	Trapped	WI
	S	A	M	Shot	ME

TABLE 1. (continued)

<i>*Contracaecum microcephalum</i> (76996)	S	A	M	Trapped	VA
	S	A	M	Emaciated	AK
	S	A	M	Aspergillosis	FL
	S	A	F	Emaciated	CA
	S	A	F	Shot	FL
	S	N	F	Airsacculitis	OR
	S	I	M	Lead poisoning	ME
	S	I	M	Emaciated	AK
	S	I	F	Undetermined	SD
	S	I	?	Shot	MO
	S	S	M	Pneumonia	MI
	S	A	M	Blunt trauma	FL
	S	A	M	Emaciated	AK
	S	A	F	Emaciated	AK
<i>*Contracaecum multipapillatum</i> (76997)	S	S	M	Blunt trauma	AK
	S	N	M	Trauma	MT
	S	I	F	Shot	MN
<i>*Contracaecum rudolphii</i> (76998)	S	I	F	Trapped	MN
	S	I	F	Shot	WI
	S	I	F	Electrocuted	ME
	S	I	F	Electrocuted	IA
	S	I	F	Aspergillosis	MA
	S	I	F	Blunt trauma	FL
	S	I	F	Shot	IL
	S	A	F	Electrocuted	WI
	S	A	M	Strychnine	AK
	S	A	M	Undetermined	OR
	S	A	F	Emaciation	CA
	P	I	F	Avian pox	AK
	P	A	F	Shot	AK
	P	A	F	Emaciated	AK
<i>*Tetrameres</i> sp. (77001)	P	I	F	Shot	SD
	P	I	F	Aspergillosis	FL
<i>*Paracuaria</i> sp. (77002)	P	I	F	Aspergillosis	FL
	P	I	F	Aspergillosis	FL

*\*Porrocaecum depressum*  
(76999)*Procyanea* sp. (77000)*\*Tetrameres* sp. (77001)*\*Paracuaria* sp. (77002)

TABLE 1. (continued)

Parasite	Site in Host <sup>a</sup>	Age <sup>b</sup>	Sex	Cause of Death	State of Collection <sup>c</sup>
<i>*Cosmocephalus obvelatus</i> (77003)	E	A	M	Shot	AK
<i>Serratospiculum amaculata</i> (77004)	A	A	M	Aspergillosis	FL
MALLOPHAGA					
<i>Colpocephalum flavescens</i> (77005)	B	I	M	Emaciated	AK
	B	I	M	Trauma	AK
	B	I	F	Emaciated	GA
	B	I	F	Peritonitis	WI
	B	I	?	Pneumonia	AK
	B	S	F	Avian pox	AK
	H	I	M	Avian pox	AK
	H	I	M	Hit by car	AK
	H	I	M	Lead poisoning	MN
<i>Craspedorrhynchus halioti</i> (77006)	H	I	M	Trauma	AK
	H	I	F	Hit by car	FL
	H	I	F	Electrocuted	FL
	H	I	F	Blunt trauma	FL
	H	I	F	Septicemia	AK
	H	I	F	Avian pox	AK
	H	S	F	Electrocuted	CA
	H	S	F	Electrocuted	FL
	H	A	M	Shot	AK
	H	A	M	Shot	UT
	H	A	M	Emaciated	AK
	H	A	F	Blunt trauma	AK
	H	A	F	Emaciated	AK
	H	A	F	Emaciated	FL
	H	I	M	Avian pox	AK
	H	I	M	Hit by car	AK
	H	I	M	Shot	MO
	H	I	M	Lead poisoning	MN
<i>Degeeriella discocephalus discocephalus</i> (77007)	H	I	F	Septicemia	AK



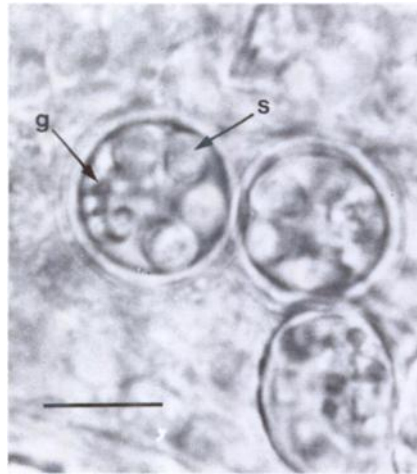


FIGURE 3. Cross sectional view of *Sarcocystis*-like oocyst showing four sporozoites and numerous granules within sporocysts. Scale bar = 7  $\mu$ m.

(range 14.8-16.2) and  $10.5 \pm 0.5 \mu$ m (range 9.7-11.2). Sporozoites mean length and width measurements were  $10.1 \pm 0.4 \mu$ m (range 9.5-11.0) and  $2.6 \pm 0.3 \mu$ m (range 2.2-3.1), respectively. The intestines of each of the infected eagles were swollen, hyperemic, and the lumina were filled with a reddish exudate. The poor post-mortem condition of the intestines, however, did not permit satisfactory histological examinations to determine if this protozoan parasite was responsible for this condition.

Using the classification proposed by Frenkel (1977, *J. Parasitol.* 63: 611-628), the oocysts we found in the eagles would belong to the family Sarcocystinae, which contains two genera, *Sarcocystis* and *Frenkelia*. The actual genus and species of the protozoan are unknown

because the oocysts were not fed experimentally to appropriate intermediate hosts. These two genera differ in location of the cysts in the intermediate hosts, therefore, the parasite is referred to only as a *Sarcocystis*-like species. This is the first report of sarcosporidian oocysts in bald eagles.

Isoporan oocysts were found in bald eagles examined by McDonald and Locke (pers. comm.). They originally thought the oocysts were of the genus *Isospora*. The descriptions of the oocysts observed in eagles they examined resembled the sarcosporidian oocysts reported here, however, no measurements or other morphologic descriptions that would permit detailed comparison are available. Since their oocysts were fully sporulated in the intestine and resembled the protozoan reported here, it is probable that the oocysts were not an enteric *Isospora*, but rather a *Sarcocystis*-like species.

No mortality and minimal pathology can be directly attributed to the presence of any of the parasites found in or on the bald eagles examined. However, the biological significance of parasitic infections in these raptors should not be ignored, particularly since infections with parasitic species such as *Serratospiculum*, *Eustrongylides* and *Capillaria* have been reported as significant pathogens in other birds (Clausen and Gudmundsen, 1981, *J. Wildl. Dis.* 17: 105-109; Kocan and Gordon, 1976, *J. Am. Vet. Med. Assoc.* 169: 908; Winterfield and Kazacos, 1977, *Avian Dis.* 21: 448-451).

We wish to thank Dr. Ronald Fayer for his comments regarding *Sarcocystis* and Dr. Louis Locke for his suggestions during the preparation of this manuscript.

Received for publication 28 August 1981