



Androgenic Gland Cell Structure and Spermatogenesis during the Molt Cycle and Correlation to Morphotypic Differentiation in the Giant Freshwater Prawn, *Macrobrachium rosenbergii*

Authors: Okumura, Takuji, and Hara, Motoyuki

Source: Zoological Science, 21(6) : 621-628

Published By: Zoological Society of Japan

URL: <https://doi.org/10.2108/zsj.21.621>

BioOne Complete (complete.BioOne.org) is a full-text database of 200 subscribed and open-access titles in the biological, ecological, and environmental sciences published by nonprofit societies, associations, museums, institutions, and presses.

Your use of this PDF, the BioOne Complete website, and all posted and associated content indicates your acceptance of BioOne's Terms of Use, available at www.bioone.org/terms-of-use.

Usage of BioOne Complete content is strictly limited to personal, educational, and non - commercial use. Commercial inquiries or rights and permissions requests should be directed to the individual publisher as copyright holder.

BioOne sees sustainable scholarly publishing as an inherently collaborative enterprise connecting authors, nonprofit publishers, academic institutions, research libraries, and research funders in the common goal of maximizing access to critical research.

Androgenic Gland Cell Structure and Spermatogenesis during the Molt Cycle and Correlation to Morphotypic Differentiation in the Giant Freshwater Prawn, *Macrobrachium rosenbergii*

Takuji Okumura* and Motoyuki Hara

National Research Institute of Aquaculture, Fisheries Research Agency,
Nansei, Mie 516-0193, Japan

ABSTRACT—The freshwater prawn *Macrobrachium rosenbergii* shows three male morphotypes: blue-claw males (final stage having high mating activity), orange-claw males (transitional stage showing rapid somatic growth), and small males (primary stage showing sneak copulation). This morphotypic differentiation is considered to be controlled by androgenic gland hormone, which is probably a peptide hormone. However, its physiological roles are not fully understood. In the present study, we examined the correlation of androgenic gland cell structure to spermatogenic activity and morphotypic differentiation histologically in *M. rosenbergii*. Spermatogenic activity showed close correlation to the molt cycle in orange-claw males and small males. Spermatogonia increased in number in the late premolt stage, becoming spermatocytes in the postmolt stage, and spermatocytes differentiated into spermatozoa in the intermolt and early premolt stages. Ultrastructure of the androgenic gland was additionally compared among the molt stages, but, distinct histological changes were not observed in relation to spermatogenesis during the molt cycle. On the other hand, among the three morphotypes, the androgenic gland was largest in the blue-claw males, containing developed rough endoplasmic reticulum in the cytoplasm. These results suggest that, during spermatogenesis which is related to the molt cycle, the androgenic gland hormone is at rather constant levels and plays a role in maintaining spermatogenesis rather than directly regulating the onset of a specific spermatogenesis stage and that, during the morphotypic differentiation, the androgenic gland is most active in the blue-claw males and plays a role in regulating the observed high mating activity in *M. rosenbergii*.

Key words: androgenic gland, Crustacea, molt cycle, morphotypic differentiation, spermatogenesis

INTRODUCTION

The androgenic gland was determined as a source of a masculinizing hormone first in the amphipod, *Orchestia gammarella* (Charniaux-Cotton, 1954) and later in the isopod, *Armadillidium vulgare* (Legrand, 1955; Katakura, 1961), although the gland is differently situated according to species: It is found attached to the subterminal region of the sperm duct in amphipods and at the end of each testicular utricule in isopods. The existence of the gland has been confirmed in many crustacean species, and it is widely accepted that the androgenic gland secretes the hormone responsible for male sex differentiation in Crustacea (reviewed by Charniaux-Cotton and Payen, 1985; Katakura 1989). Recently androgenic gland hormone was purified as a peptide hormone and its cDNA sequence was determined in *A. vulgare* (Martin *et al.*, 1999; Okuno *et al.*, 1999).

In decapod crustaceans, the role of the androgenic gland has been studied by organ-ectomy and implantation. It has been revealed that it functions in male sex differentiation, e.g., gonadal sex differentiation and development of sex-specific appendages in the giant freshwater prawn, *Macrobrachium rosenbergii* (Nagamine *et al.*, 1980a, b), the red swamp crawfish, *Procambarus clarkii* (Nagamine and Knight, 1987; Taketomi and Nishikawa, 1996), and the crayfish, *Cherax quadricarinatus* (Khalaila *et al.*, 1999, 2001).

In decapods, the androgenic gland hormone has not yet been purified, but it is considered to be a protein based on analogy with the isopod androgenic gland hormone and the histological characteristics of the gland in decapods (Sagi and Khalaila, 2001). The development of rough endoplasmic reticulum (rER) in the cytoplasm of the androgenic gland has been correlated to male reproductive activities in several decapod species (King, 1964; Taketomi 1986; Taketomi *et al.*, 1990; Taketomi *et al.*, 1996; Kim *et al.*, 2002). These ultrastructural characteristics can be used as an index of secretory activity of the androgenic gland, as immunological

* Corresponding author: Tel. +81-599-66-1830;
FAX. +81-599-66-1962.
E-mail: takuji@affrc.go.jp

and molecular biological methods to detect the androgenic hormone in decapods are not available thus far.

In male *M. rosenbergii*, three distinctive morphotypes have been recognized according to the color and length of claw and reproductive behavior: small males, orange-claw males, and blue-claw males (Ra'anán and Sagi, 1985; Kuris *et al.*, 1987). Each morphotype has been shown to exhibit a different reproductive strategy. Small males have short claws, employ a sneak copulation strategy, and grow into orange-claw males. Orange-claw males show rapid somatic growth and do not mate. Orange-claw males further grow to become blue-claw males, which actively mate with mature females. Spermatogenic activity changes with morphotypic differentiation; it is high in small males and orange-claw males, but low in blue-claw males, the testes of which are filled with mature sperm and used for sperm storage (Sagi *et al.*, 1988). This morphotypic differentiation has been shown to be under the control of the androgenic gland based on experiments using androgenic gland ablation (Sagi *et al.*, 1990).

In addition to during the morphotypic differentiation, spermatogenesis activity is known to change during the molt cycle in *M. rosenbergii*. Thymidine incorporation rate (an index of DNA synthesis) in testes was high in premolt orange-claw males but low in intermolt orange-claw males and blue-claw males (Sagi *et al.*, 1991). Treatment with 20-hydroxyecdysone (molting hormone) increased the rate of testicular thymidine incorporation, indicating that 20-hydroxyecdysone plays a role in regulating spermatogenesis (Sagi *et al.*, 1991). However, the involvement of androgenic gland hormone and its relationship to spermatogenesis and the molt cycle has not yet been examined.

The main purpose of the present study was to determine whether the secretory activity of the androgenic gland changes during spermatogenesis in relation to the molt cycle in *M. rosenbergii*. For this purpose, we observed the development of rER in the androgenic gland, as an index of the secretory activity, at differing molt stages in the three morphotypes, and examined the correlation of the androgenic gland cell structure to the molt cycle and morphotypic differentiation.

MATERIALS AND METHODS

Animals

Male *M. rosenbergii* (118 prawns, 28–60 mm in carapace length) were obtained from local culture farms in Suphanburi, Thailand. The three morphotypes, small males, orange-claw males, and

blue-claw males were determined by coloration, spination, and shape of cheliped (claw) according to previously reported criteria (Kuris *et al.*, 1987). Body weight, carapace length, cheliped length, and propodus (claw) length and width were measured. Indexes of the chelipeds were calculated as follows: cheliped length (mm) / carapace length (mm) for relative cheliped length, propodus length (mm) / carapace length (mm) for relative propodus length, and propodus width (mm) / propodus length (mm) for relative propodus width. Testis and sperm duct samples were weighed in order to calculate gonadosomatic index (GSI) as 100 × testis and sperm duct combined weight (g) / body weight (g).

Molt stages were determined by observing the setal development of the pleopods under a light microscope (Okumura *et al.*, 1992). The molt cycle was divided into 5 stages: postmolt (Stages A and B), intermolt (Stages C₀ and C₁), early premolt (Stages D₀ and D₁), late premolt (Stages D₂ and D₃), and ecdysis (Stage E). Ecdysis stage samples were not obtained due to the short duration of this stage. Blue-claw males at the premolt stages were not observed, as it is known that blue-claw males do not molt (Kuris *et al.*, 1987).




Fig. 1. Male morphotypes in *Macrobrachium rosenbergii*. BC, blue-claw males; OC, orange-claw males; SM, small males. Bar=10cm.

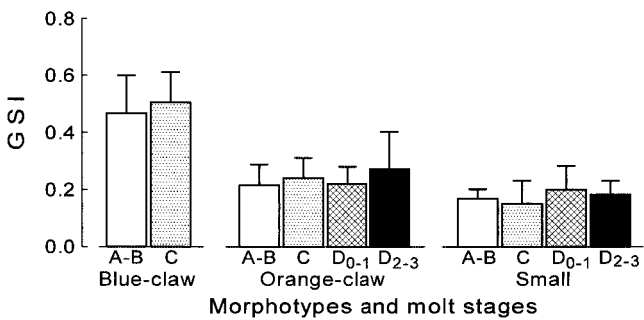


Fig. 2. Gonadosomatic index (GSI) during the molt cycle for each male morphotype in *Macrobrachium rosenbergii*. Mean±SD.

Table 1. Body weight (BW), carapace length (CL), relative cheliped length (RCL), relative propodus length (RPL), relative propodus width (RPW), and gonadosomatic index (GSI) of the male morphotypes in *Macrobrachium rosenbergii* (mean±SD)

Morphotypes	Animal No.	BW (g)	CL (mm)	RCL	RPL	RPW	GSI
Blue-claw males	40	70.2±21.3	52.0±5.5	4.12±0.41	1.80±0.20	0.16±0.01	0.49±0.12
Orange-claw males	46	56.5±17.3	50.3±5.3	2.98±0.18	1.29±0.11	0.14±0.01	0.24±0.08
Small males	32	14.7± 3.9	32.0±2.8	2.22±0.18	0.82±0.10	0.09±0.01	0.18±0.11

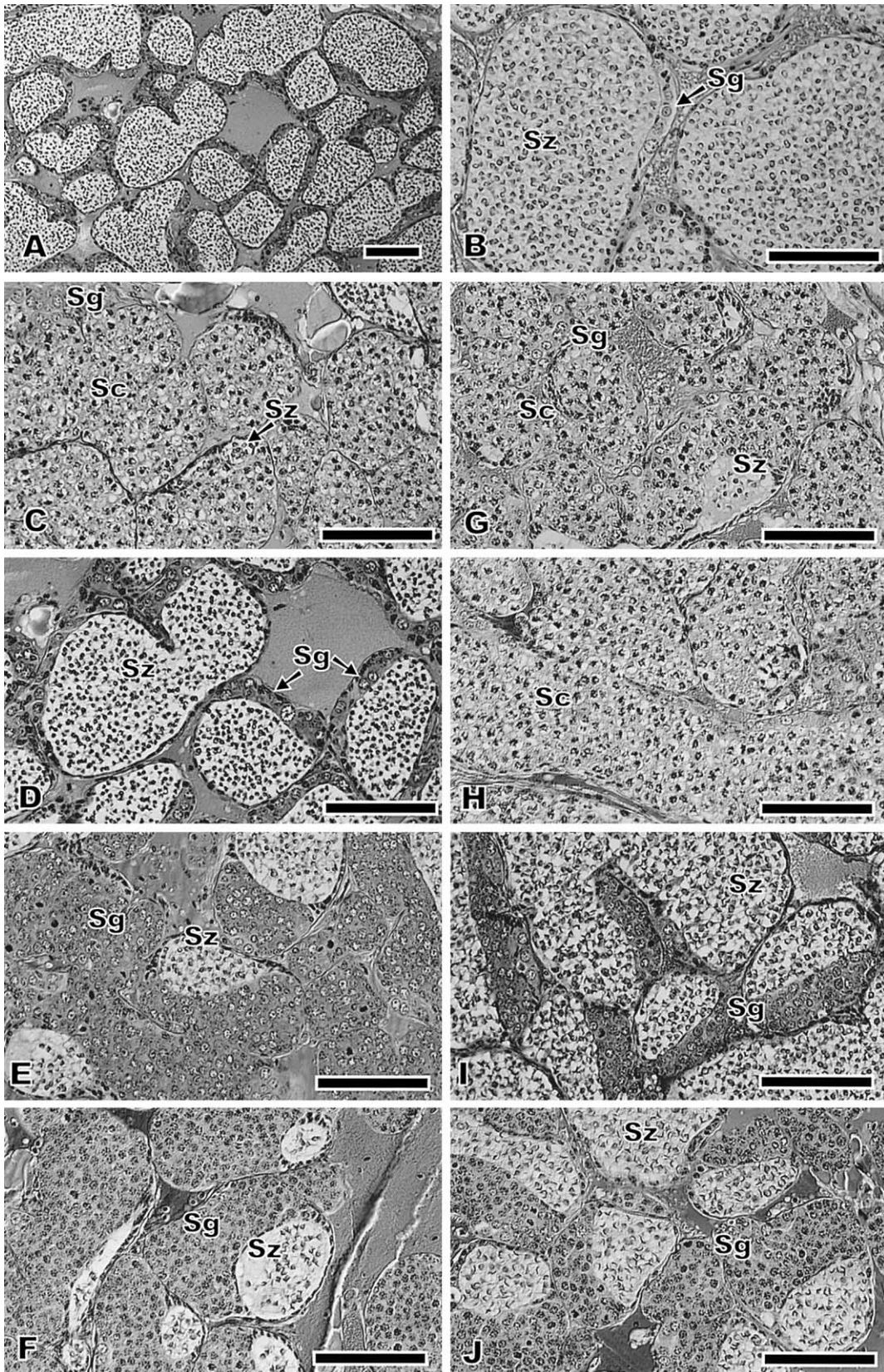


Fig. 3. Cross-sections of testes in *Macrobrachium rosenbergii*. A, B, blue-claw male at molt stage C; C, orange-claw male at stage A; D, orange-claw male at stage C; E, orange-claw male at stage D₁; F, orange-claw male at stage D₂; G, small male at stage B; H, small male at stage C; I, small male at stage D₁; J, small male at stage D₂. Bar=0.1mm. Sc, spermatocytes; Sg, spermatogonia; Sz, spermatozoa.

Histological procedures

Testes were dissected from the 118 males, and fixed with Bouin's solution for 24 hours. After dehydration through an ethanol and xylene series, the fixed samples were embedded in paraffin, and sectioned at 4 μ m thickness. Sections were stained with hematoxylin-eosin for histological observation under light microscopy.

The androgenic gland in this species is associated with the posterior region of the sperm duct (Nagamine *et al.*, 1980a). Glands from half of the 118 males were fixed with Bouin's solution for light microscopy, and glands from the other half were fixed in ice-cold 2.25% paraformaldehyde and 2% glutaraldehyde buffered with 75 mM sodium cacodylate for transmission electron microscopy. For light microscopy, the fixed glands were embedded in paraffin as above. For transmission electron microscopy, the fixed glands were post-fixed with 1% osmium tetroxide, and embedded in epon 812 after dehydration through a series of ethanol, propylene oxide, and QY-1. Ultra-thin sections were stained with uranyl acetate and lead citrate. The sections were observed under a Hitachi H-7100 electron microscope at 75 kV or a JEOL JEM-100CX electron microscope at 80 kV.

Statistical analysis

Quantitative data are presented as the mean \pm SD (standard deviation). Data were examined by one-way ANOVA, and differences between the means were assessed by the Tukey-Kramer multiple range test. Probability values of $P < 0.05$ were considered statistically significant.

RESULTS

Morphotypes and gonadal development

Blue-claw males showed large blue claws, orange-claw males had relatively short, orange-blue claws, and small

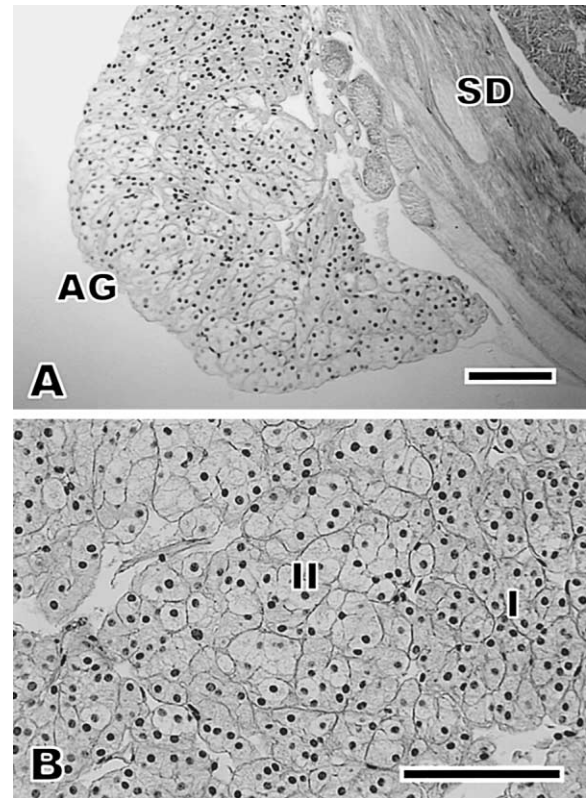


Fig. 4. Androgenic gland morphology in blue-claw male *Macrobrachium rosenbergii*. AG, androgenic gland; SD, sperm duct; I, type I cells; II, type II cells. Bar=0.1mm.

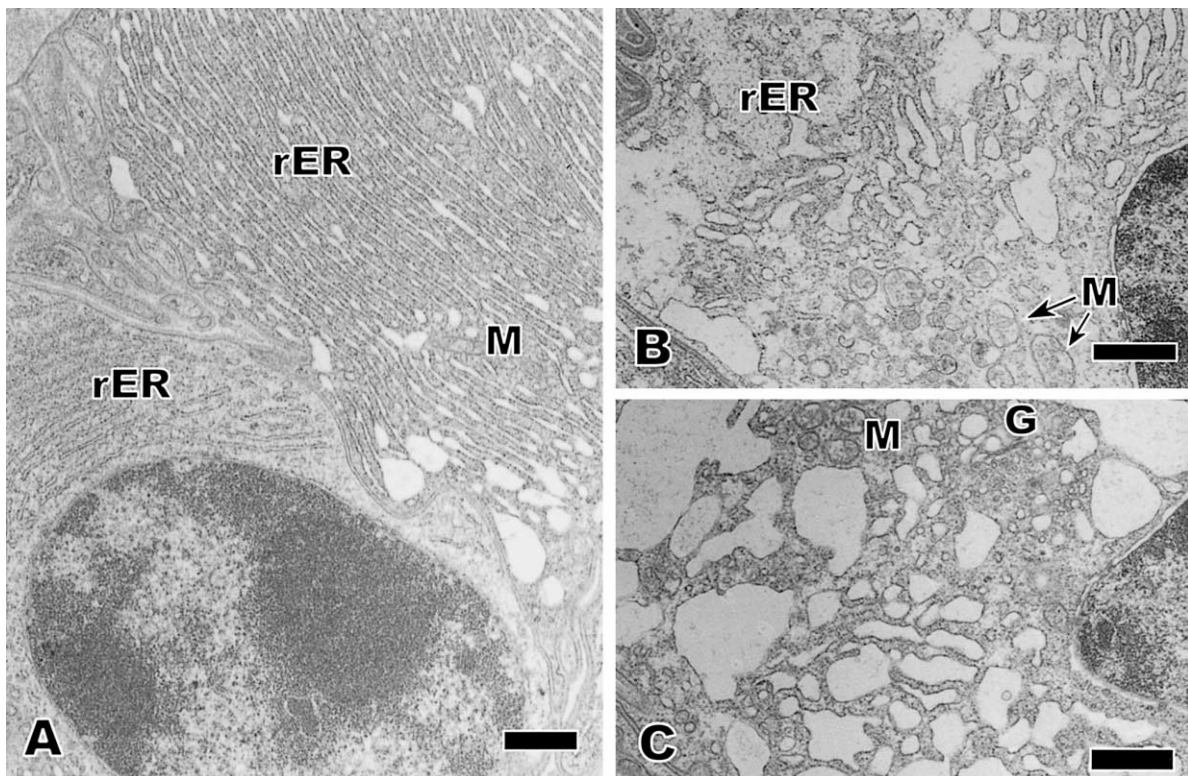


Fig. 5. Androgenic gland cells in blue-claw male *Macrobrachium rosenbergii*. A, type I cell; B,C, type II cells. G, Golgi complex; M, mitochondria; rER, rough endoplasmic reticulum. Bar=1 μ m.

males had short and relatively unpigmented claws (Fig. 1). Among the three morphotypes used in this study, blue-claw males were of the greatest body weight and carapace length, and small males showed the lowest ($P<0.05$, Table 1). Relative cheliped length, relative propodus length, and relative propodus width were highest in blue-claw males and lowest in small males ($P<0.05$), indicating that the development of the chelipeds occurred during morphotypic differentiation.

In blue-claw males, the reproductive system comprised of the testes and sperm ducts, was developed and GSI was significantly higher ($P<0.05$, Table 1). In all three morphotypes, GSI did not change significantly in relation to the molt cycle ($P>0.05$, Fig. 2).

Testes were composed of multiple lobes, and each lobe consisted of testicular seminiferous tubules (Fig. 3A). In blue-claw males, the testicular tubules were replete with mature spermatozoa and contained a small amount of spermatogonia (Fig. 3B). These histological characteristics of the testes did not differ between the postmolt and intermolt stages.

On the other hand, in small males and orange-claw males, the testes showed distinct histological changes during the molt cycle. In the postmolt stages A–B, spermatocytes occupied the major part of the testicular tubules, and the area occupied by spermatogonia were small (Fig. 3C, G). In the intermolt stage C, spermatocytes still occupied the major part of the testicular tubules in small males (Fig. 3H), while spermatozoa filled the testicular tubules in orange-claw males (Fig. 3D). In the early premolt stages (D_0 – D_1), the area occupied by spermatogonia became larger in small males and orange-claw males (Fig. 3E, I). The remaining space in the testicular tubules was occupied by spermatozoa, and almost no spermatocytes were observed. In the late premolt stages (D_2 – D_3), spermatozoa and spermatogonia still occurred in the testicular tubules (Fig. 3F, J).

Androgenic gland cell structure during morphotypic differentiation

The androgenic gland is an organ attached to the sperm duct (Fig. 4A). The glands consisted mainly of two kinds of cells, which are referred to here as type I and II (Fig. 4B). The type I cells were relatively small, and their cytoplasm was deeply stained by hematoxylin. The type II cells were relatively large, and their cytoplasm was lightly stained by hematoxylin. Under electron microscopy, the cytoplasm of the type-I and II cells was filled with rER, indicating that these cells were active in producing proteins. In the type I cells, the rER in the cytoplasm was more condensed (Fig. 5A). On the other hand, in the type II cells, the rER in the cytoplasm was less and often expanded. Electron density in the cytoplasm was low in some type II cells (Fig. 5B, C). The two cell types are likely indicative of different phases of cell activity. Mitochondria were observed in both cell types, but distinct secretory granules were not observed.

The androgenic glands contained both cell types in all three morphotypes (Fig. 6). The glands were largest in blue-

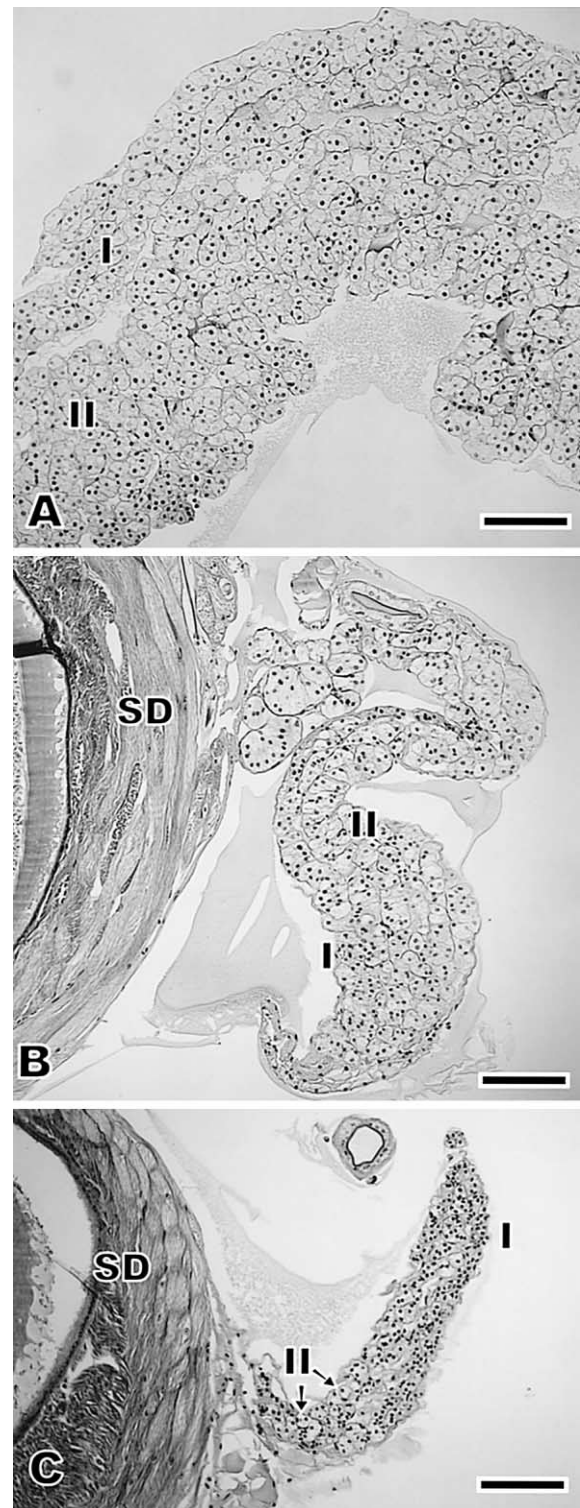


Fig. 6. Androgenic gland morphology for each male morphotype in *Macrobrachium rosenbergii*. A, blue-claw male; B, orange-claw male; C, small male. SD, sperm duct; I, type I cells; II, type II cells. Bar=0.1mm.

claw males and smallest in small males. The ultrastructure of the type I cells was compared among the three morphotypes; type I cells showed a more typical protein-producing

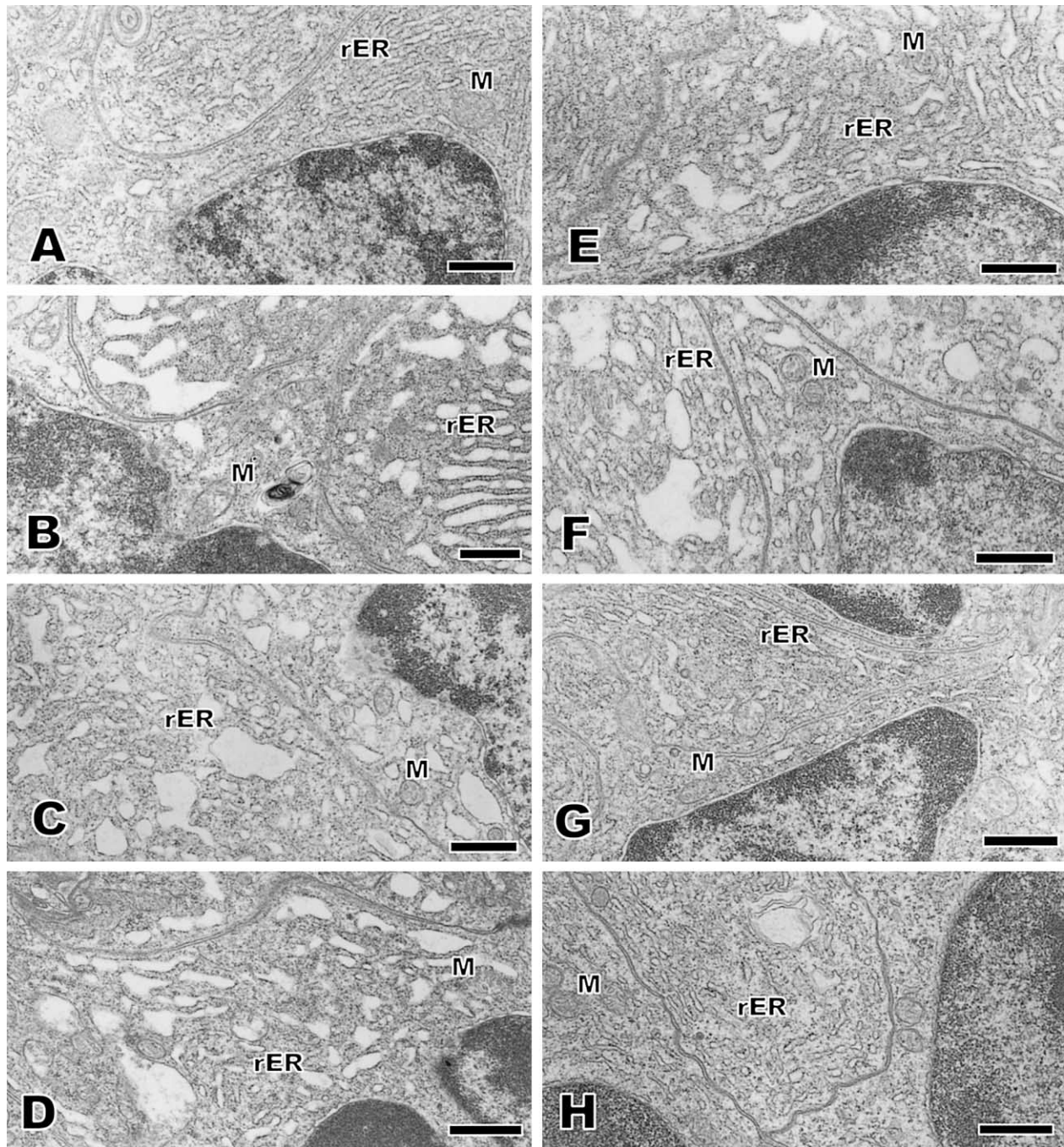


Fig. 7. Androgenic gland structure during the molt cycle in *Macrobrachium rosenbergii*. A, orange-claw male at molt stage A; B, orange-claw male at stage C; C, orange-claw male at stage D₁; D, orange-claw male at stage D₂; E, small male at stage B; F, small male at stage C; G, small male at stage D₁; H, small male at stage D₂. M, mitochondria; rER, rough endoplasmic reticulum. Bar=1 μ m.

cell structure than did type II cells.

In blue-claw males, the rER in the cytoplasm of the type I cells was well-developed and consisted of developed lamellar membrane systems (Fig. 5A), whereas it was less developed in orange-claw males and small males (Fig. 7). Ultrastructural characteristics did not differ during the molt cycle in orange-claw males and small males (Fig. 7).

DISCUSSION

The main finding of the present study is that the secretory activity of the androgenic gland does not show distinct changes during spermatogenesis related to the molt cycle in *M. rosenbergii*. This is shown by the result that the androgenic gland cells did not change in the development of rER in their cytoplasm during spermatogenesis in orange-claw males and small males. The lack of change in the ultrastruc-

ture of androgenic gland cells suggests that androgenic gland hormone is at rather constant levels during spermatogenesis and plays a role in maintaining spermatogenesis rather than directly regulating the onset of a specific spermatogenesis stage during the molt cycle.

This hypothesis for the androgenic gland functions on spermatogenesis agrees with organ-ectomy and implantation experiments in this species. Androgenic gland ablation in males caused atrophy of testes, and androgenic gland implantation to juvenile females initiated spermatogenesis (even to spermatozoa) in the ovaries (Nagamine *et al.*, 1980a,b), suggesting that androgenic gland hormone does not regulate a specific spermatogenesis stage but plays a role in preparing the testes structure and maintaining active spermatogenesis. On the other hand, as suggested by Sagi *et al.* (1991), 20-hydroxyecdysone may stimulate the onset of spermatogenesis, induction of DNA synthesis, in spermatogenic tissue prepared under the control of androgenic gland hormone.

In blue-claw male, rER in the androgenic gland cell cytoplasm developed most highly, and the gland was largest, indicating that the activity of the gland is highest in such males. Similar results were reported previously (Okumura *et al.*, 1997; Sun *et al.*, 2000). These previous reports observed ultrastructure of androgenic gland cells in intermolt animals, while the present study observed the ultrastructure in animals from postmolt stage to late premolt stage to provide a better understanding of androgenic gland functions during morphotypic differentiation. Blue-claw males show the most developed reproductive systems filled with mature spermatozoa, the highest mating activity, and the largest claws among the three morphotypes (Ra'anani and Sagi, 1985; Sagi *et al.*, 1988). Furthermore, the androgenic gland is known to affect male behavior in decapod crustaceans (Barki *et al.*, 2003). Along these lines, the androgenic gland may be involved in changes in reproductive activity and claw development during morphotypic differentiation.

The present study found that the spermatogenic activity in testes histologically changed during the molt cycle in small males and orange-claw males. This result confirms and extends the previous study with orange-claw males (Sagi *et al.*, 1991). This histological change in spermatogenesis suggests that mating activity becomes high in intermolt animals having testes filled with spermatozoa, although only small males actively mate.

Androgenic gland hormone is considered to be a protein; however, the secretory granules were indistinct in *M. rosenbergii* androgenic gland cells. Similar observations were reported in other decapod species and isopods (Hasegawa *et al.*, 1993). Recently, in *A. vulgare* it was reported that the rapid-freezing and freeze-substitution method is suitable for fixation and dehydration of the gland because of the vulnerable structures of the cells (Negishi *et al.*, 2001). This technique may also improve the ability to reduce damage to the fine structure of the androgenic gland in *M. rosenbergii*, although it was not attempted in the present study.

A relationship between the androgenic gland cell structure and spermatogenesis in the reproductive season have been reported in *P. clarkii* (Taketomi *et al.*, 1996) and *Macrobrachium nipponense* (Kim *et al.*, 2002). These results seem to be inconsistent with those of the present study. In these species, spermatogenic activity is high during spring-fall and low in winter. Environmental factors such as temperature and nutrition change seasonally, and may affect androgenic gland activity. Thus, the correlation of androgenic gland structure to spermatogenesis likely differs between during the molt cycle and during the annual cycle.

The present study is based on histological observations of the development of rER in the androgenic gland cells; however, the ultrastructure of androgenic gland cells is likely to be related not only to the secretory activity but also to the cell growth activity. While histological observations have provided new information concerning the functioning of the androgenic gland, more specific methods are required for further investigation of its role. In *A. vulgare*, after purification of the androgenic gland hormone, a recombinant hormone was produced (Okuno *et al.*, 2002), and the distribution of the hormone was immunohistochemically determined to be limited to the androgenic gland using a specific antibody raised against the recombinant hormone (Hasegawa *et al.*, 2002). Immunological methods for examination of androgenic gland function are not currently available in decapods as the androgenic gland hormone has not yet been purified in any decapod species.

In conclusion, during spermatogenesis which is related to the molt cycle in *M. rosenbergii*, the androgenic gland secretory activity is likely to be static rather than showing dynamic changes. The activity seems to be highest in blue-claw males, suggesting that the androgenic gland plays a role in regulating mating activity in blue-claw males. For further investigation, purification of the hormone is an essential key. The present study provides useful information for potential purification techniques. The active androgenic gland in blue-claw males may be used as a purification source. Morphotypic differentiation may be suitable for bioassay of the androgenic gland hormone activity rather than spermatogenesis, because secretory activity is more likely related to morphotypic differentiation.

ACKNOWLEDGEMENTS

We express appreciation to Prof. P. Tabthipwong, Kasetsart University, Thailand for assistance in sample collection. We thank Dr. M. Okiyama and Ms. M. Hara, Ocean Research Institute (ORI), University of Tokyo for technical assistance and valuable discussion. This study was supported in part by a project sponsored by the Japan International Research Center for Agricultural Sciences, and by funds from the Cooperative Program No.38, 2001 provided by ORI.

REFERENCES

Barki A, Karplus I, Khalaila I, Manor R, Sagi A (2003) Male-like

- behavioral patterns and physiological alterations induced by androgenic gland implantation in female crayfish. *J Exp Biol* 206: 1791–1797
- Charniaux-Cotton H (1954) Découverte chez un crustacé amphipode (*Orchestia gammarella*) d'une glande endocrine responsable de la différenciation des caractères sexuels primaires et secondaires mâles. *C R Acad Sci Paris* 239: 780–782
- Charniaux-Cotton H, Payen G (1985) Sexual differentiation. In "The Biology of Crustacea Vol 9" Ed by DE Bliss, LH Mantel, Academic Press, New York, pp 217–299
- Hasegawa Y, Hirose E, Katakura Y (1993) Hormonal control of sexual differentiation and reproduction in Crustacea. *Am Zool* 33: 403–411
- Hasegawa Y, Okuno A, Nagasawa H (2002) Immunohistochemical study of androgenic gland hormone: localization in the male reproductive system and species specificity in the terrestrial isopods. *Gen Comp Endocrinol* 125: 218–225
- Katakura Y (1961) Hormonal control of development of sexual characters in the isopod crustacean, *Armadillidium vulgare*. *Annot Zool Japon* 34: 60–71
- Katakura Y (1989) Endocrine and genetic control of sex differentiation in the Malacostracan Crustacea. *Invertebr Reprod Dev* 16: 177–182
- Khalaila I, Weil S, Sagi A (1999) Endocrine balance between male and female components of the reproductive system in intersex *Cherax quadricarinatus* (Decapoda: Parastacidae). *J Exp Zool* 283: 286–294
- Khalaila I, Katz T, Abdu U, Yehezkel G, Sagi A (2001) Effects of implantation of hypertrophied androgenic glands on sexual characters and physiology of the reproductive system in the female red claw crayfish, *Cherax quadricarinatus*. *Gen Comp Endocrinol* 121: 242–249
- Kim DH, Jo Q, Kim BK, Han CH (2002) Eyestalk ablation-induced androgenic gland activity and gonad development in the freshwater prawn *Macrobrachium nipponense* (De Haan, 1849). *Invertebr Reprod Dev* 42: 35–42
- King DS (1964) Fine structure of the androgenic gland of the crab, *Pachygrapsus crassipes*. *Gen Comp Endocrinol* 4: 533–544
- Kuris AM, Ra'anani Z, Sagi A, Cohen D (1987) Morphotypic differentiation of male Malaysian giant prawn, *Macrobrachium rosenbergii*. *J Crust Biol* 7: 219–237
- Légrand JJ (1955) Rôle endocrinien de l'ovaire dans la différenciation des oostégites chez les Crustacés Isopodes terrestres. *C R Acad Sci Paris* 241: 1083–1087
- Martin G, Sorokine O, Moniatte M, Bulet P, Hetru C, Van Dorsselaer A (1999) The structure of a glycosylated protein hormone responsible for sex determination in the isopod, *Armadillidium vulgare*. *Eur J Biochem* 262: 727–736
- Nagamine C, Knight AW, Maggenti A, Paxman G (1980a) Effects of androgenic gland ablation on male primary and secondary sexual characteristics in the Malaysian prawn *Macrobrachium rosenbergii* (de Man) (Decapoda, Palaemonidae) with first evidence of induced feminization in a nonhermaphroditic decapod. *Gen Comp Endocrinol* 41: 423–441
- Nagamine C, Knight AW, Maggenti A, Paxman G (1980b) Masculinization of female *Macrobrachium rosenbergii* (de Man) (Decapoda, Palaemonidae) by androgenic gland implantation. *Gen Comp Endocrinol* 41: 442–457
- Nagamine C, Knight AW (1987) Masculinization of female crayfish, *Procambarus clarkii* (Girard). *Int J Invertebr Reprod Dev* 11: 77–86
- Negishi S, Hasegawa Y, Nakajima Y (2001) Novel structures in secreting the androgenic gland hormone. *Zool Sci* 18: 1237–1243
- Okumura T, Han CH, Suzuki Y, Aida K, Hanyu I (1992) Changes in hemolymph vitellogenin and ecdysteroid levels during the reproductive and non-reproductive molt cycles in the freshwater prawn *Macrobrachium nipponense*. *Zool Sci* 9: 37–45
- Okumura T, Hara M, Hara M, Okiyama M (1997) Possible roles of the androgenic gland in male reproduction in the giant freshwater prawn, *Macrobrachium rosenbergii*. In "Advances in Comparative Endocrinology Vol 1" Ed by S Kawashima, S Kikuyama, Monduzzi Editore, Bologna, pp 73–77
- Okuno A, Hasegawa Y, Ohira T, Katakura Y, Nagasawa H (1999) Characterization and cDNA cloning of androgenic gland hormone of the terrestrial isopod *Armadillidium vulgare*. *Biochem Biophys Res Com* 264: 419–423
- Okuno A, Hasegawa Y, Nishiyama M, Ohira T, Ko R, Kurihara M, Matumoto S, Nagasawa H (2002) Preparation of an active recombinant peptide of crustacean androgenic gland hormone. *Peptides* 23: 567–572
- Ra'anani Z, Sagi A (1985) Alternative mating strategies in male morphotypes of the freshwater prawn *Macrobrachium rosenbergii* (de Man). *Biol Bull* 169: 592–601
- Sagi A, Milner Y, Cohen D (1988) Spermatogenesis and sperm storage in the testes of the behaviorally distinctive male morphotypes of *Macrobrachium rosenbergii* (Decapoda, Palaemonidae). *Biol Bull* 174: 330–336
- Sagi A, Cohen D, Milner Y (1990) Effect of androgenic gland ablation on morphotypic differentiation and sexual characteristics of male freshwater prawns, *Macrobrachium rosenbergii*. *Gen Comp Endocrinol* 77: 15–22
- Sagi A, Karp L, Milner Y, Cohen D, Kuris AM, Chang ES (1991) Testicular thymidine incorporation in the prawn *Macrobrachium rosenbergii*: molt cycle variation and ecdysteroid effects *in vitro*. *J Exp Zool* 259: 229–237
- Sagi A, Khalaila I (2001) The crustacean androgen: a hormone in an isopod and androgenic activity in decapods. *Amer Zool* 41: 477–484
- Sun PS, Weatherby TM, Dunlap MF, Arakaki KL, Zacarias DT, Malecha SR (2000) Developmental changes in structure and polypeptide profile of the androgenic gland of the freshwater prawn *Macrobrachium rosenbergii*. *Aquaculture Int* 8: 327–334
- Taketomi Y (1986) Ultrastructure of the androgenic gland of the crayfish, *Procambarus clarkii*. *Cell Biol Int Reports* 10: 131–136
- Taketomi Y, Murata M, Miyawaki M (1990) Androgenic gland and secondary sexual characters in the crayfish *Procambarus clarkii*. *J Crust Biol* 10: 492–497
- Taketomi Y, Nishikawa S (1996) Implantation of androgenic glands into immature female crayfish, *Procambarus clarkii*, with masculinization of sexual characteristics. *J Crust Biol* 16: 232–239
- Taketomi Y, Murata M, Imakado K (1996) On the androgenic gland of the crayfish, *Procambarus clarkii*. I. Seasonal changes in the cell structure of the androgenic gland of the crayfish, *Procambarus clarkii*. *Mem Fac Gen Education Kumamoto Univ Natural Sci* 31: 65–72

(Received January 22, 2004 / Accepted March 12, 2004)