

## **Molecular Detection of *Pseudogymnoascus destructans* (Ascomycota: Pseudeurotiaceae) and Unidentified Fungal Dermatitides on Big Brown Bats (*Eptesicus fuscus*) Overwintering inside Buildings in Canada**

Authors: McAlpine, Donald F., McBurney, Scott, Sabine, Mary, Vanderwolf, Karen J., Park, Allysia, et al.

Source: Journal of Wildlife Diseases, 52(4) : 902-906

Published By: Wildlife Disease Association

URL: <https://doi.org/10.7589/2015-03-076>

---

BioOne Complete ([complete.BioOne.org](https://complete.BioOne.org)) is a full-text database of 200 subscribed and open-access titles in the biological, ecological, and environmental sciences published by nonprofit societies, associations, museums, institutions, and presses.

Your use of this PDF, the BioOne Complete website, and all posted and associated content indicates your acceptance of BioOne's Terms of Use, available at [www.bioone.org/terms-of-use](https://www.bioone.org/terms-of-use).

Usage of BioOne Complete content is strictly limited to personal, educational, and non - commercial use. Commercial inquiries or rights and permissions requests should be directed to the individual publisher as copyright holder.

---

BioOne sees sustainable scholarly publishing as an inherently collaborative enterprise connecting authors, nonprofit publishers, academic institutions, research libraries, and research funders in the common goal of maximizing access to critical research.

## Molecular Detection of *Pseudogymnoascus destructans* (Ascomycota: Pseudeurotiaceae) and Unidentified Fungal Dermatitides on Big Brown Bats (*Eptesicus fuscus*) Overwintering inside Buildings in Canada

Donald F. McAlpine,<sup>1,6</sup> Scott McBurney,<sup>2</sup> Mary Sabine,<sup>3</sup> Karen J. Vanderwolf,<sup>1,4</sup> Allisia Park,<sup>2</sup> and Hugh Y. Cai<sup>5</sup> <sup>1</sup>New Brunswick Museum, 277 Douglas Avenue, Saint John, New Brunswick E2K 1E5, Canada; <sup>2</sup>Canadian Wildlife Health Cooperative, Atlantic Region, Atlantic Veterinary College, University of Prince Edward Island, 550 University Avenue, Charlottetown, Prince Edward Island C1A 4P3, Canada; <sup>3</sup>New Brunswick Department of Natural Resources, PO Box 6000, Fredericton, New Brunswick E3B 5H1, Canada; <sup>4</sup>Canadian Wildlife Federation, 350 Promenade Michael Cowpland Drive, Kanata, Ontario K2M 2W1, Canada; <sup>5</sup>Animal Health Laboratory, University of Guelph, 419 Gordon Street, Building 89, Guelph, Ontario N1G 2W1, Canada; <sup>6</sup>Corresponding author (email: donald.mcalpine@nbm-mnb.ca)

**ABSTRACT:** Big brown bats (*Eptesicus fuscus*) overwintering outside the underground environment are not believed to play a role in the epidemiology of the disease white-nose syndrome (WNS), caused by the fungus *Pseudogymnoascus destructans* (*Pd*). Using quantitative real-time PCR (qPCR), we provide molecular evidence for *Pd* on four big brown bats overwintering in heated buildings in New Brunswick, Canada. Two of the affected individuals also had very mild, focal, pustular, fungal dermatitis identified microscopically. A third bat, which was qPCR *Pd*-negative, had similar fungal lesions. Despite determining that these fungal lesions were caused by a suspected ascomycete, the intralésional fungi were not confirmed to be *Pd*. These findings demonstrate that bats overwintering in heated buildings and other above-ground sites may have subclinical or preclinical WNS, or be contaminated with *Pd*, and could play a role in local dispersal of *Pd*. Our inability to determine if the ascomycetes causing pustular lesions were *Pd* highlights the need for ancillary diagnostic tests, such as in situ hybridization or immunohistochemistry, so that *Pd* can be detected directly within a lesion. As the host–pathogen relationship for *Pd* evolves, and where bat species are exposed to the fungus under varying temperature regimes, lesions may become less stereotypic and such tests could help define these changes.

**Key words:** Big brown bat, *Eptesicus fuscus*, fungal infection, *Pseudogymnoascus destructans*, white-nose syndrome.

White-nose syndrome (WNS), caused by the fungus *Pseudogymnoascus destructans* (*Pd*), is decimating populations of eastern North American bats. First detected in New York in 2006–07, it is believed *Pd* was introduced from Europe (Leopardi et al.

2015). Estimates suggest >6.7 million bats have died from WNS (US Fish and Wildlife Service 2012), and several species may be at risk of regional extinction (Frick et al. 2010). White-nose syndrome is associated with bats in underground hibernacula during periods of extended torpor (hibernation), when they fail to show a cellular immune response to *Pd* invasion (Meteyer et al. 2011, 2012) and where environmental conditions provide high humidity and the range of temperatures at which *Pd* grows (Verant et al. 2012).

More than 50% of the 45 North American bat species hibernate underground (Foley et al. 2011), most above 40°N. Other bats may enter torpor for short or extended periods while roosting in buildings, hollow trees, and under bark. As winter approaches some migratory bats leave the northern portion of their range, possibly avoiding the need for torpor. Although WNS is reported in cave-roosting big brown bats (*Eptesicus fuscus*) and *Pd* prevalence on this species can be high (Langwig et al. 2014), we are not aware that *Pd* or WNS has been documented in hibernating bats overwintering outside underground hibernacula. We present incidents where *E. fuscus* overwintering in buildings had Suspect (b) category diagnoses of WNS (Canadian Wildlife Health Cooperative [CWHC] 2014), based on premature egression from hibernacula (a clinical or field sign associated with WNS) and cryptic *Pd* infections as determined by quantitative real-time PCR (qPCR) for *Pd*, but with no external

TABLE 1. Findings in big brown bats (*Eptesicus fuscus*) collected in or adjacent to buildings, during winter in New Brunswick, Canada, and submitted to Canadian Wildlife Health Cooperative (CWHC) November 2013–May 2014. Included are quantitative real-time PCR (qPCR) results for *Pseudogymnoascus destructans* (*Pd*), white-nose syndrome status based on histologic evaluation, whether fungal elements were seen histologically, and minimum outdoor temperature on day of collection.

Date collected	CWHC	Location <sup>a</sup>	Status	Sex <sup>b</sup>	Age <sup>c</sup>	Weight (g)	<i>Pd</i> qPCR <sup>d</sup>	WNS <sup>d</sup>	Fungal lesions <sup>d</sup>	Temperature <sup>e</sup>
16 November	107455	O	Alive	M	Imm	11.6	N	N	N	–5.6 C
2 January	107775	B	Alive	M	?	12.8	N	N	N	–29.5 C
2 January	107768	O	Dead	M	Imm	14.5	P (Cq=29.46)	N	N	–31.0 C
8 January	107769	B	Alive	F	Adult	19.4	P (Cq=29.07)	N	P	–16.1 C
9 January	107774	B	Alive	F	Imm	11.7	P (Cq=30.51)	N	P	–19.5 C
26 January	110398	B	Alive	F	Imm	10.2	N	N	N	–15.6 C
7 February	108006	B	Alive	F	Adult	13.0	N	N	N	–18.7 C
25 March	109782	B	Alive	M	Adult	11.9	P (Cq=35.00)	N	N	–21.6 C
16 April	110401	O	Dead	F	Imm	12.0	N	N	N	[10.3 C] <sup>f</sup>
23 May	110014	O	Alive	F	Imm	11.7	N (Cq=44.19)	N	P	8.0 C

<sup>a</sup> O = outside; B = inside building.

<sup>b</sup> M = male; F = female.

<sup>c</sup> Imm = immature.

<sup>d</sup> N = negative; P = positive; Cq = quantification cycle.

<sup>e</sup> Environment Canada.

<sup>f</sup> Data not available for 15 April; 16 April data presented.

signs of the fungus (see Janicki et al. 2015). The affected individuals also lacked grossly visible or microscopic lesions consistent with WNS (Meteyer et al. 2009), providing further evidence of the cryptic nature of these preclinical or subclinical infections. Although *Pd* on the surface of bat skin or fur could yield positive qPCR without infection, molecular detection of *Pd* on multiple bats during hibernation <195 km from *Pd*-positive underground hibernacula strongly suggests infection. In addition, some affected bats had a fungal dermatitis caused by unidentified ascomycetes. We discuss epidemiologic implications and diagnostic significance of these results.

Surveillance for WNS and *Pd* in bats in Atlantic Canada follows a standardized necropsy protocol (CWHC 2014) and has been underway since winter 2008–09. The disease was first recorded in New Brunswick in 2011. Most postmortem submissions of bats include little brown bats (*Myotis lucifugus*) and northern long-eared bats (*Myotis septentrionalis*) which overwinter in underground hibernacula in the region. However, 10 big

brown bats were submitted from New Brunswick during mid-November to late May 2013–14 (Table 1). Six of these bats were discovered active and alive inside the living spaces of human-occupied, heated buildings in Fredericton (45°57'N–66°38'W). The remaining four were found dead or alive outside, near buildings, where they may have been overwintering, in Fredericton ( $n=3$ ) and near Royalton (46°28'N–67°45'W), 85–190 km north of the closest known underground hibernaculum. Prior to necropsy, swabs for *Pd* were taken with one sterile, polyester swab from the dorsal and ventral wing membranes, ears, and muzzle of each bat (CWHC 2014). Swabs were frozen at –80 C and sent to the Animal Health Laboratory, University of Guelph (Ontario) to test for *Pd* using qPCR for WNS surveillance (Muller et al. 2013). Skin from all wing membranes, ears, and two cross-sections of the muzzle were fixed in 10% neutral-buffered formalin, dehydrated in alcohol and xylene, and embedded in paraffin; 5- $\mu$ m sections were stained with H&E and periodic acid-Schiff to detect fungi.

Cause of death for the 10 bats included rabies ( $n=1$ ), possible hypothermia ( $n=1$ ), and euthanasia of emaciated ( $n=7$ ) and apparently healthy individuals ( $n=1$ ). Four of the 10 bats had positive qPCR results for *Pd* (Table 1) and two of these also had a pustular, focal dermatitis with intralesional, unidentified ascomycetes. Fungi were identified as ascomycetes based on the presence of septa without clamp connections, the typical morphologic feature distinguishing the group (Alexopoulos et al. 1996). Although the monokaryon hyphae of basidiomycetes share this feature, most filamentous fungal infections are caused by ascomycetes and most pathogenic infections associated with basidiomycetes present solely in the single-celled yeast state (de Hoog et al. 2000). A third bat with similar, multifocal lesions was qPCR *Pd*-negative based on a quantification cycle  $>40$ , the cut-off for WNS surveillance protocol (Muller et al. 2013). Although *Pd* qPCR was positive in four of 10 *E. fuscus*, lesions consistent with WNS (Meteyer et al. 2009) were not present. Additionally, fungal hyphae or conidia morphologically consistent with the typical growth described for intralesional *Pd* in bats with WNS (Meteyer et al. 2009) were not identified microscopically. Skin lesions caused by the unidentified ascomycetes were only found on the muzzle and were minor and not associated with significant disease.

In the first case (CWHC 107769; Table 1), the fungus was on the epidermal surface in a solitary, intraepidermal, microscopic pustule on the muzzle of an adult female in good body condition that had been found alive inside a building. The fungal hyphae within the pustule were narrow (2.5- $\mu$ m diameter) and septate with random branching. In contrast, the hyphae within the epidermis were often bulbous and almost torulose, with diameters  $<5.0$   $\mu$ m (Fig. 1A). In the second case (CWHC 107774), the fungus was in a solitary, microscopic, intraepidermal pustule in the muzzle skin of an immature female in poor body condition, also found alive inside a building. The fungal hyphae were septate with prominent constrictions at their frequent septa and with random branching. The hyphal

walls bulged slightly and varied from 2.5–5.0  $\mu$ m in diameter (Fig. 1B). In the last case (CWHC 110014), there were morphologically different fungi in two separate microscopic, intraepidermal pustules in the muzzle skin of an immature female that was emaciated and found alive outside, adjacent to a building. The hyphae of one fungus were branched with infrequent septation and were variable in diameter (2.5–7.5  $\mu$ m; Fig. 1C); these hyphae were not confined to the intraepidermal pustule but extended into the surrounding dermis. The morphology of the second fungus varied depending on its location in the lesion. On the epidermal surface, and within the intraepidermal pustule, there were slender (1.8–2.5  $\mu$ m diameter), unbranched, septate hyphae. However, where they extended into the surrounding dermis, the diameters of the hyphae were 2.5–5.0  $\mu$ m (Fig. 1D). Conidiogenesis was not observed from any of the fungi.

Outside New Brunswick, big brown bats share caves with *Myotis* spp. and tricolored bats (*Perimyotis subflavus*). However, big brown bats are known to hibernate only in heated buildings in New Brunswick (McAlpine et al. 2002). Such behavior is common in the northern US (Whitaker and Gummer 2000). It is unknown how the *Pd*-positive big brown bats reported here might have acquired *Pd*. Although big brown bats may participate in swarming behavior at New Brunswick hibernacula, there is no evidence to support this.

Verant et al. (2012) found the optimal *Pd* growth temperature to be 12.5–15.8 C, with atypical fungal morphologies observed above 12 C; fungal morphologies typical for *Pd* were displayed between 0–7 C. Vanderwolf et al. (2012) report average winter dark zone temperatures of  $5.1 \pm 1.1$  C for New Brunswick underground hibernacula. While the descriptions of Verant et al. (2012) for atypical *Pd* morphologies share some similarities with the unidentified fungi we describe, and big brown bats were hibernating in buildings that likely provided the higher temperatures associated with atypical growth of *Pd*, there is no in situ or immunohistochemical diagnostic test



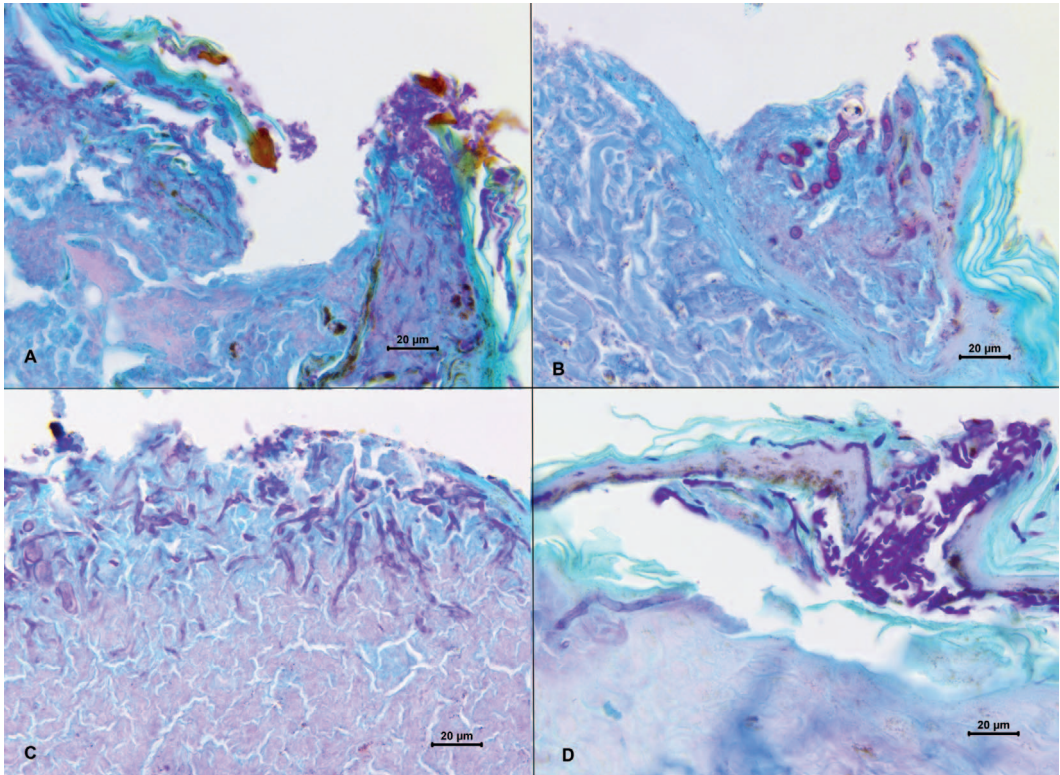


FIGURE 1. Suppurative dermatitis associated with unidentified fungal hyphae (suspect ascomycete) in histologic sections of Canadian big brown bat (*Eptesicus fuscus*) muzzles stained with periodic acid-Schiff. Canadian Wildlife Health Cooperative (CWHC) numbers 107769 (A) and 107774 (B) were both found alive inside buildings, and were quantitative real-time PCR (qPCR)-positive for *Pseudogymnoascus destructans* (*Pd*), the fungal agent of white-nose syndrome. Fungal hyphae associated with inflammation were restricted to the epidermis of the muzzle. (C, D) Images from the muzzle of CWHC 110014, found alive outside and qPCR *Pd*-negative. The hyphae penetrate the dermis.

available to confirm that these unidentified fungi are *Pd*. Nonetheless, our data demonstrate that *Pd* may occur on *E. fuscus* overwintering in buildings, although risk of the subsequent development of WNS is unclear. In spite of temperature conditions in buildings that are more conducive for *Pd* growth than are underground hibernacula, we could not confirm WNS in any of the *Pd*-infected big brown bats, consistent with Frank et al. (2014) findings that big brown bats have some resistance to WNS. Langwig et al. (2014) suggested that even occasional movements among underground hibernacula during winter could be important in *Pd* spread. Although big brown bats do not appear to use underground hibernacula in New Brunswick,

these bats can regularly move in and out of winter roosts in buildings and caves (Beer 1955; Whittaker and Gummer 2000).

We can neither conclude nor discount that the fungi in the big brown bat lesions were *Pd*. Ancillary diagnostic tests, such as in situ hybridization or immunohistochemistry, are needed so that *Pd* can be detected directly within a microscopic lesion, particularly in the absence of identifying features such as conidia. As the host–pathogen relationship for *Pd* evolves, and where bats are exposed to the fungus under varying temperature regimes, lesions may become less stereotypic, and such tests could help define these changes.

We are grateful to the following members of the public for submitting bat specimens for

testing: John Boudreau, Cara Hazelton, Wendell Price (Canadian Border Services Agency), Joe Robichaud, and Larry Tannahill. We are especially grateful to Melissa Behr, University of Wisconsin, School of Veterinary Medicine; Carol Meteyer, US Geological Survey, National Wildlife Health Center; and David Overy, Department of Pathology and Microbiology, Atlantic Veterinary College, University of Prince Edward Island, who graciously provided constructive comments on the pathology as it related to the fungal infections reported here, as well as David Groman with Aquatic Diagnostic Services, Atlantic Veterinary College, for preparation of photomicrographs and Hamid Haghighi and Patricia Bell-Rogers with Animal Health Laboratory, University of Guelph, for qPCR testing of our samples.

#### LITERATURE CITED

- Alexopoulos CJ, Mims CW, Blackwell M. 1996. *Introductory mycology*. 4th Ed. John Wiley and Sons, Inc., New York, New York, 880 pp.
- Beer JR. 1955. Survival and movement of banded big brown bats. *J Mamm* 36:242–248.
- CWHC (Canadian Wildlife Health Cooperative). 2014. Canadian bat white-nose syndrome necropsy protocol. 10 pp. <http://www.cwhc-rscf.ca/docs/Canadian%20Bat%20WNS%20Necropsy%20Protocol.pdf>. Accessed May 2016.
- de Hoog GS, Guarro J, Gené J, Figueras MJ. 2000. *Atlas of clinical fungi*. 2nd Ed. Centraalbureau voor Schimmelmcultures, Baarn, the Netherlands, 1126 pp.
- Foley J, Clifford D, Castle K, Cryan P, Ostfeld RS. 2011. Investigating and managing the rapid emergence of white-nose syndrome, a novel, fatal, infectious disease of hibernating bats. *Conserv Biol* 25:223–231.
- Frank CL, Michalski A, McDonough AA, Rahimian M, Rudd RJ, Herzog C. 2014. The resistance of a North American bat species (*Eptesicus fuscus*) to white-nose syndrome (WNS). *PLoS One* 9:e113958.
- Frick WF, Pollock JF, Hicks AC, Langwig KE, Reynolds DS, Turner GG, Butchkoski CM, Kunz TH. 2010. An emerging disease causes regional population collapse of a common North American bat species. *Science* 329:679–682.
- Janicki AF, Frick WF, Kilpatrick AM, Parise KL, Foster JT, McCracken GF. 2015. Efficacy of visual surveys for white-nose syndrome at bat hibernacula. *PLoS One* 10:e0133390.
- Langwig KE, Frick WF, Reynolds R, Parise KL, Drees KP, Hoyt JR, Cheng TL, Kunz TH, Foster JT, Kilpatrick AM. 2014. Host and pathogen ecology drives the seasonal dynamics of a fungal disease, white-nose syndrome. *Proc Biol Sci* 282:20142335.
- Leopardi S, Blake D, Puechmaille SJ. 2015. White-nose syndrome fungus introduced from Europe to North America. *Curr Biol* 25:R217–R219.
- McAlpine DF, Muldoon F, Forbes GA, Wandeler AI, Makepeace S, Broders HG, Goltz JP. 2002. Overwintering and reproduction by the big brown bat, *Eptesicus fuscus*, in New Brunswick. *Can Field-Nat* 116:645–647.
- Meteyer CU, Barber D, Mandl JN. 2012. Pathology in euthermic bats with white-nose syndrome suggests a natural manifestation of immune reconstitution inflammatory syndrome. *Virulence* 3:583–588.
- Meteyer CU, Buckles EL, Blehert DS, Hicks AC, Green DE, Shearn-Bochsler V, Thomas NJ, Gargas A, Behr MJ. 2009. Histopathologic criteria to confirm white-nose syndrome in bats. *J Vet Diagn Invest* 21:411–414.
- Meteyer CU, Valent M, Kashmer J, Buckles EL, Lorch JM, Blehert DS, Lollar A, Berndt D, Wheeler E, White CL, et al. 2011. Recovery of little brown bats (*Myotis lucifugus*) from natural infection with *Geomyces destructans*, white-nose syndrome. *J Wildl Dis* 47:618–626.
- Muller LK, Lorch JM, Lindner DL, O'Connor M, Gargas A, Blehert DS. 2013. Bat white-nose syndrome: A real-time TaqMan polymerase chain reaction test targeting the intergenic spacer region of *Geomyces destructans*. *Mycologia* 105:253–259.
- US Fish and Wildlife Service. 2012. *North American bat death toll exceeds 5.5 million from white-nose syndrome*. US Fish and Wildlife Service, Arlington Virginia. [https://www.whitenosesyndrome.org/sites/default/files/files/wms\\_mortality\\_2012\\_nr\\_final\\_0.pdf](https://www.whitenosesyndrome.org/sites/default/files/files/wms_mortality_2012_nr_final_0.pdf). Accessed June 2016.
- Vanderwolf KJ, McAlpine DF, Forbes GJ, Malloch D. 2012. Winter bat populations and cave microclimate prior to and at the onset of white-nose syndrome in New Brunswick. *Can Field-Nat* 126:125–134.
- Verant ML, Boyles JG, Waldrep W Jr, Wibbelt G, Blehert DS. 2012. Temperature-dependent growth of *Geomyces destructans*, the fungus that causes bat white-nose syndrome. *PLoS One* 7:e46280.
- Whitaker JO Jr, Gummer SL. 2000. Population structure and dynamics of the big brown bat (*Eptesicus fuscus*) hibernating in buildings in Indiana. *Am Midl Nat* 143:389–396.

Submitted for publication 26 March 2015.

Accepted 7 January 2016.

## ERRATUM

“Molecular Detection of *Pseudogymnoascus destructans* (Ascomycota: Pseudeurotiaceae) and Unidentified Fungal Dermatitides on Big Brown Bats (*Eptesicus fuscus*) Overwintering in Buildings” by Donald F. McAlpine et al. [*Journal of Wildlife Diseases*, 2016, 52(4):902–906; DOI: 10.7589/2015-03-076]. The table (p. 903) contains errors. Those errors have been corrected in the online version.