

The Flea, *Megabothris abantis*: An Invertebrate Host of *Hepatozoon* sp. and a Likely Definitive Host in *Hepatozoon* Infections of the Montane Vole, *Microtus montanus*

Authors: Watkins, Raychel A., Moshier, Suzanne E., and Pinter, Aelita J.

Source: Journal of Wildlife Diseases, 42(2) : 386-390

Published By: Wildlife Disease Association

URL: <https://doi.org/10.7589/0090-3558-42.2.386>

BioOne Complete (complete.BioOne.org) is a full-text database of 200 subscribed and open-access titles in the biological, ecological, and environmental sciences published by nonprofit societies, associations, museums, institutions, and presses.

Your use of this PDF, the BioOne Complete website, and all posted and associated content indicates your acceptance of BioOne's Terms of Use, available at www.bioone.org/terms-of-use.

Usage of BioOne Complete content is strictly limited to personal, educational, and non - commercial use. Commercial inquiries or rights and permissions requests should be directed to the individual publisher as copyright holder.

BioOne sees sustainable scholarly publishing as an inherently collaborative enterprise connecting authors, nonprofit publishers, academic institutions, research libraries, and research funders in the common goal of maximizing access to critical research.

The Flea, *Megabothris abantis*: An Invertebrate Host of *Hepatozoon* sp. and a Likely Definitive Host in *Hepatozoon* Infections of the Montane Vole, *Microtus montanus*

Raychel A. Watkins,¹ Suzanne E. Moshier,^{1,3} and Aelita J. Pinter² ¹ Department of Biology, University of Nebraska at Omaha, Omaha, Nebraska 68182-0040, USA; ² Department of Biological Sciences, University of New Orleans, New Orleans, Louisiana 70148, USA; ³ Corresponding author (email: smoshier@mail.unomaha.edu)

ABSTRACT: In searching for an invertebrate host for *Hepatozoon* sp. infecting the montane vole (*Microtus montanus*), we collected fleas, ticks, and mites from live-trapped voles and searched squash preparations for *Hepatozoon* oocysts. From 1989 through 1996, we identified six species of fleas in Grand Teton National Park: *Megabothris abantis*, *Megabothris asio megacolpus*, *Aetheca wagneri*, *Peromyscopsylla selenis*, *Peromyscopsylla hesperomys*, and *Hystriechopsylla dippiei dippiei*. We found *Hepatozoon* oocysts only in *M. abantis*; we found no oocysts in mites or ticks. We conclude that *M. abantis* is an invertebrate host of *Hepatozoon* sp. and is likely to be the definitive host for the *Hepatozoon* spp. of *M. montanus*.

Key words: Definitive host, flea, *Hepatozoon*, invertebrate host, *Megabothris abantis*, *Microtus montanus*, oocyst, sporocyst.

Hepatozoon spp. parasitize many mammals, especially rodents (Smith, 1996). The life cycle includes a second host, the invertebrate or definitive host, which, depending upon species may be a tick, mite, louse, flea, mosquito, or reduviid bug (Krampitz, 1964; Smith, 1996). Although many mammals are known to be hosts for *Hepatozoon* sp., the corresponding invertebrate hosts are known for only a few. We sought to identify an invertebrate host for the *Hepatozoon* spp. parasitizing the montane vole, *Microtus montanus*. Because one of us (A.J.P.) is conducting a long-term study of the population dynamics of *M. montanus* (Pinter, 1986, 1988), we had the opportunity to collect invertebrate ectoparasites from montane voles live-trapped in Wyoming in Grand Teton National Park. Desser et al. (1995) found the search for the invertebrate host of *Hepatozoon catesbianae* “a slow and laborious process”;

our search was also prolonged and labor intensive. We examined ectoparasites of *M. montanus* for five collection years before finding oocysts in the flea, *Megabothris abantis*.

We collected mites, ticks, lice, and fleas from *M. montanus* live-trapped in Grand Teton National Park, Wyoming, at approximately 43°50'N, 110°35'W. We squashed the arthropods and made wet mounts on 1 × 3-inch glass slides with phosphate-buffered saline to screen these ectoparasites for the presence of *Hepatozoon* oocysts. We used a compound microscope at 60× (4× objective lens and 15× ocular lens) and focused our examination on the abdominal region. Putative oocysts could be discerned, and specimens suspected of being infected were squashed, fixed in methanol, and stained with Wright–Giemsa stain. Squash preparations were examined further for the presence of *Hepatozoon* oocysts with a light microscope equipped with 15× oculars and a 100× oil-immersion objective lens. Fleas that were not squashed were preserved in 70% ethanol and sent to Robert E. Lewis at Iowa State University to be identified. He identified the two squashed fleas that contained oocysts from photographs as well as the other preserved fleas.

We drew blood from the left ventricle of the heart of euthanized voles with a 25-gauge needle on a heparinized tuberculin syringe and then prepared blood smears. Smears of femoral bone marrow and impression smears of lung, liver, and spleen were also prepared. The smears were fixed in methanol and stained with Wright–Giemsa stain. Each smear was

examined for a minimum of 15 min with a compound microscope equipped with 15× oculars and a 100× oil objective.

We approached the search for an invertebrate host qualitatively at the start. Squashed fleas from our earliest attempts in 1988 were discarded because we were simply looking for a *Hepatozoon*-infected flea. We began keeping uninfected fleas to send to R.E. Lewis for identification after we noticed morphological differences among them (Table 1). From 1989 to 1994 we found two out of 23 *M. abantis* infected with *Hepatozoon* sp. Consequently, a rough approximation of the prevalence in *M. abantis* is 10%.

We found *Hepatozoon* oocysts in two *M. abantis* individuals collected in 1994. Figure 1 shows several oocysts magnified 160×. The maximum oocyst diameter is 125 µm. This size fits neither category used by Smith and Desser (1997) in their phylogenetic analysis of the genus *Hepatozoon*. They characterized the maximum oocyst diameter of *Hepatozoon* spp. into one of two size ranges, <80 µm or >150 µm. Their study included two species, *Hepatozoon erhardovae* and *Hepatozoon griseisciuri*, that use mammalian intermediate hosts; both had oocysts with a maximum diameter >150 µm. Our data call into question the utility of this character.

TABLE 1. Identified fleas collected in Grand Teton National Park from the montane vole (*Microtus montanus*).

Year	Flea species	No.
1989	<i>Megabothris abantis</i>	1
	<i>Megabothris asio megacolpus</i>	3
1990	<i>Megabothris abantis</i>	2
1991	<i>Aetheca wagneri</i>	1
	<i>Megabothris abantis</i>	8
	<i>Megabothris asio megacolpus</i>	3
1994	<i>Hystrihopsylla dippiei dippiei</i>	4
	<i>Megabothris abantis</i>	12
	<i>Megabothris asio megacolpus</i>	8
	<i>Peromyscopsylla selenis</i>	2

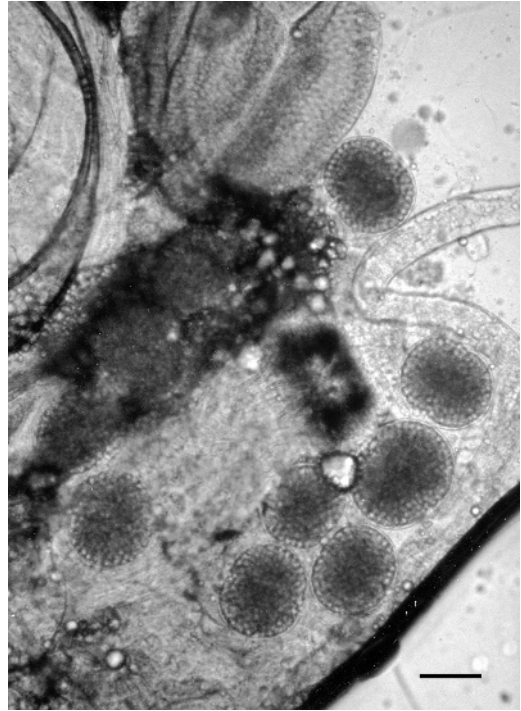


FIGURE 1. Squash preparation of *Megabothris abantis* infected with *Hepatozoon* sp. (Wright-Giemsa stain). Oocysts, magnification 160×, scale bar=50 µm.

In Figure 2, with magnification increased to 320×, sporocysts within the oocytes are evident. We found more than 100 sporocysts per oocyst, an observation that matches the characteristics reported by Smith and Desser (1997) for *H. erhardovae* and *H. griseisciuri*. At 1,600× (Fig. 3) sporozoites within the sporocysts are evident. The maximum sporocyst diameter is approximately 13 µm. This small size places the *Hepatozoon* spp. of *M. abantis* in the less-than-25-µm, rather than the greater-than-30-µm, category of Smith and Desser. It is the same category as *H. erhardovae* and *H. griseisciuri*. We saw four to six sporozoites per sporocyst. *Hepatozoon erhardovae* and *H. griseisciuri* also fell into the category with fewer than 16 sporozoites per sporocyst in the Smith and Desser study. The *Hepatozoon* spp. of *M. abantis* thus matches *H. erhardovae* and *H. griseisciuri*.

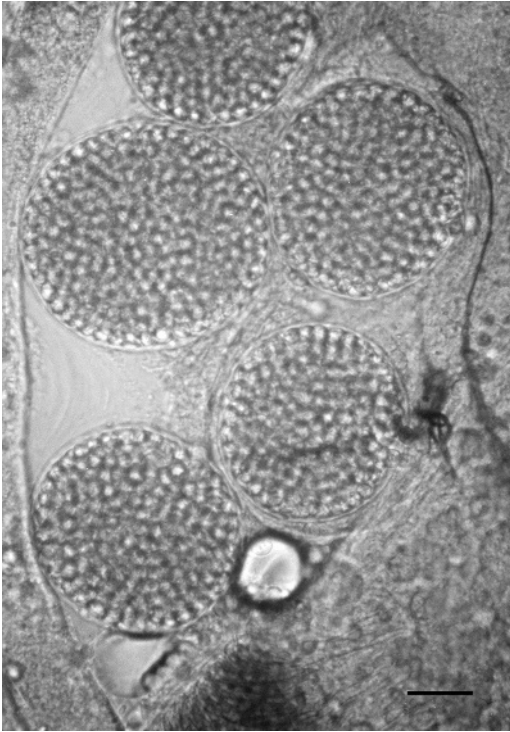

FIGURE 2. Squash preparation of *Megabothris abantis* infected with *Hepatozoon* sp. (Wright-Giemsa stain). Sporocysts in oocysts, magnification 320 \times , scale bar=25 μ m.

in three of the four characters (maximum oocyst diameter, number of sporocysts per oocyst, maximum sporocyst diameter, and number of sporozoites per sporocyst) we have evaluated.

We collected six flea species (*M. abantis*, *Megabothris asio megacolpus*, *Aetheca wagneri*, *Peromyscopsylla selenis*, *Peromyscopsylla hesperomys*, and *Hystri-chopsylla dippiei dippiei*) from 1989 to 1996. Fleas examined in 1988 were not retained for identification. We found oocysts only in *M. abantis*. This finding establishes *M. abantis* as an invertebrate host for *Hepatozoon* sp. Additionally, because *M. abantis* is the flea that we collected most frequently from *M. montanus* (Table 1), we propose that it is most likely the invertebrate host species for the *Hepatozoon* spp. of *M. montanus*. However, some caution is required because an

infected flea may have acquired its infection from an animal other than the one on which it was found. A case in point is our finding of both infected fleas in 1994 on voles that were negative for *Hepatozoon* (Table 2). This situation could arise if the flea were infected from the host vole harboring an undetected infection or if it were infected from another animal.

We found that *Hepatozoon* sp. is a persistent endoparasite in populations of *M. montanus* in northwestern Wyoming. From 1988 to 1996, blood, bone marrow, lungs, liver, and spleen of 468 *M. montanus* were examined for infection with *Hepatozoon* sp. (Table 2). Thirty-nine of these voles were found to be infected (overall infection rate of 8.3%). The year with the highest, and atypical, rate of infection was 1989 with 19% infected. In two years, 1994 and 1995, no infections were found. In the other collection years the infection rates ranged from 8% to 12%. The variation in infection rate cannot be explained satisfactorily by the prevailing macroclimate. For example, both 1988 and 1994 were drought years, yet the infection rates, 12% and 0%, respectively, are quite different. We suspect that the microclimate experienced by fleas in the voles' burrows may be more important than the macroclimate in determining the success of flea reproduction. Because flea larvae die when the relative humidity is below 45%, and they fail to mature at temperatures above 35 C (Powell, 1994), it is likely that burrows provide a more mesic microclimate than one would expect given the more xeric, drought-stricken meadows.

Our research establishes *M. abantis* as an invertebrate host for *Hepatozoon* sp. Because infected fleas were removed from *M. montanus*, it is also preliminary evidence that *M. abantis* transmits *Hepatozoon* to *M. montanus*. Transmission studies are necessary to confirm or refute this relationship. Completion of the life cycle of this *Hepatozoon* remains to be de-

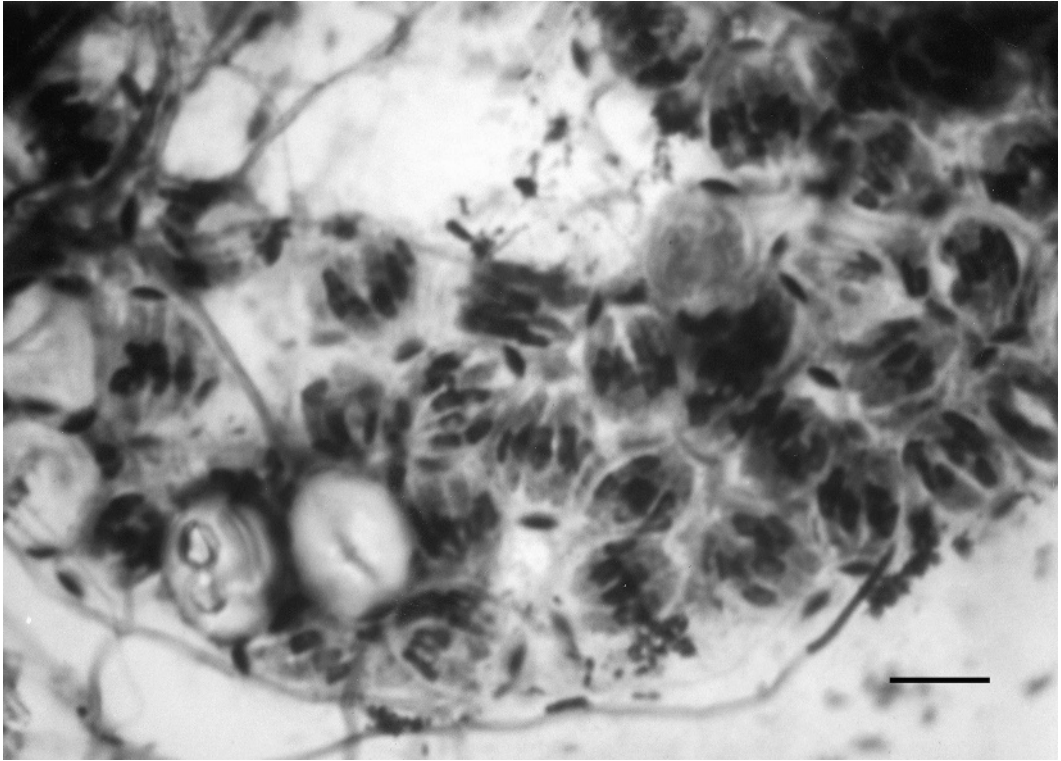


FIGURE 3. Squash preparation of *Megabothris abantis* infected with *Hepatozoon* sp. (Wright–Giemsa stain). Sporozoites within sporocysts, magnification 1,600 \times , scale bar=5 μ m.

terminated, and other vertebrate and invertebrate hosts may be involved in the life cycle.

Among rodents for which *Hepatozoon* infections have been reported, the invertebrate host is frequently unknown. *Hepatozoon* has been reported in other species of the genus *Microtus*, including *Microtus agrestis* (Healing, 1981), *Micro-*

tus arvalis (Pawelczyk et al., 2004), *Microtus oeconomus* (Obayashi, 1971), *Microtus californicus* (Laakkonen et al., 2001), *Microtus miurus* (Laakkonen et al., 2002), and *Microtus pennsylvanicus* (O'Dell et al., 1991). *Hepatozoon* spp. have been reported in rodent species in other genera including *Clethrionomys* and *Apodemus* (Healing, 1981), *Lemmus* (Laakkonen, 2004), *Liomys* (Desser, 2000), *Idiurus* (Killick-Kendrick, 1984), *Thomomys* and *Peromyscus* (Moshier et al., 1994), and *Sciurus* (Clark, 1958). We are aware of one instance in which a flea is known to be the vector that transmits *Hepatozoon*. Frank (1977) reported that *Megabothris turbidus* transmits *Hepatozoon erhardovae* to a nonspecific host, the yellow-necked mouse (*Apodemus flavicollis*).

We are grateful to the University of Wyoming (UW) and the National Park

TABLE 2. Prevalence of *Hepatozoon* sp. in montane voles (*Microtus montanus*) in Grand Teton National Park.

Year	No. of voles trapped	No. infected	% infected
1996	37	3	8
1995	50	0	0
1994	68	0	0
1991	97	9	9
1990	74	5	7
1989	69	13	19
1988	73	9	12

Service (NPS) for the use of the UW-NPS Research Center in Grand Teton National Park and to Robert E. Lewis, Emeritus Professor of Entomology, Iowa State University, for identifying fleas. We are also grateful to two anonymous reviewers whose valuable comments improved this paper. This study was supported in part by a grant from UW.

LITERATURE CITED

- CLARK, G. M. 1958. *Hepatozoon griseisciuri* n. sp.; a new species of *Hepatozoon* from the grey squirrel (*Sciurus carolinensis* Gmelin, 1788), with studies on the life cycle. *Journal of Parasitology* 44: 52–63.
- DESSER, S. S. 2000. The blood parasites of the spiny pocket mouse *Liomys salvini* (Thomas, 1893) from Costa Rica. *Journal of Parasitology* 86: 156–157.
- , H. HONG, AND D. S. MARTIN. 1995. The life history, ultrastructure, and experimental transmission of *Hepatozoon catesbiana*, n. comb., an Apicomplexan parasite of the bullfrog, *Rana catesbiana*, and the mosquito, *Culex territans*, in Algonquin Park, Ontario. *Journal of Parasitology* 81: 212–222.
- FRANK, C. 1977. Ein Beitrag zur Biologie von *Hepatozoon erhardovae* Krampitz 1964 in Rötelmäusen aus der Südweststeiermark und des Neusiedlerseegebietes (Burgenland). *Zeitschrift für Parasitenkunde* 53: 251–254.
- HEALING, T. D. 1981. Infections with blood parasites in the small British rodents *Apodemus sylvaticus*, *Clethrionomys glareolus*, and *Microtus agrestis*. *Parasitology* 83: 179–189.
- KILLICK-KENDRICK, R. 1984. Parasitic protozoa of the blood of rodents. VI. Two new hemogregarines of the pygmy flying squirrel *Idiurus macrotis* (Rodentia: Theridomyomorpha: Anomaluridae) in West Africa. *Journal of Protozoology* 31: 532–535.
- KRAMPTZ, H. E. 1964. Über das Vorkommen und Verhalten von Haemococcidien der Gattung *Hepatozoon*, Miller 1908 (Protozoa, Adeleidae) in mittel- und südeuropäischen Säugern. *Acta Tropica* 21: 114–154.
- LAAKKONEN, J. 2004. Hepatozoonosis and trypanosomiasis in Norwegian lemmings, *Lemmus lemmus*, from Finland. *Acta Parasitologica* 49: 269–271.
- , R. N. FISHER, AND T. J. CASE. 2001. Pneumocystosis in wild small mammals from California. *Journal of Wildlife Diseases* 37: 408–412.
- , H. HENTTONEN, M. W. HASTRITER, J. NIEMIMAA, AND G. H. JARRELL. 2002. Hemoparasites and fleas of shrews and rodents from Alaska. *Acta Parasitologica* 47: 255–257.
- MOSHIER, S. E., W. D. O'DELL, R. A. WATKINS, AND A. J. PINTER. 1994. Parasites of small mammals in Grand Teton National Park: *Babesia* and *Hepatozoon*. In *University of Wyoming–National Park Service Research Center 18th annual report*, H. J. Harlow and M. Harlow (eds.). UW-NPS Research Center, Laramie, Wyoming, pp. 65–75.
- OBAYASHI, M. 1971. *Hepatozoon* sp. in northern voles, *Microtus oeconomus*, on St. Lawrence Island, Alaska. *Journal of Wildlife Diseases* 7: 49–51.
- O'DELL, W. D., R. A. WATKINS, S. E. MOSHIER, AND A. J. PINTER. 1991. *Giardia* and other parasites of small mammals in Grand Teton National Park. In *University of Wyoming–National Park Service Research Center 15th annual report*, G. E. Plumb (ed.). UW-NPS Research Center, Laramie, Wyoming, pp. 155–157.
- PAWELCZYK, A., A. BAJER, J. M. BEHNKE, F. S. GILBERT, AND E. SINSKI. 2004. Factors affecting the component community structure of haemoparasites in common voles (*Microtus arvalis*) from the Mazury Lake District region of Poland. *Parasitology Research* 92: 270–284.
- PINTER, A. J. 1986. Population dynamics and litter size of the montane vole, *Microtus montanus*. *Canadian Journal of Zoology* 64: 1487–1490.
- . 1988. Multiannual fluctuations in precipitation and population dynamics of the montane vole, *Microtus montanus*. *Canadian Journal of Zoology* 66: 2128–2132.
- POWELL, P. K. 1994. Fleas. In *Household pest management: Less toxic methods for managing your uninvited guests*. West Virginia University Cooperative Extension Service, Morgantown, West Virginia, pp. 1–2.
- SMITH, T. G. 1996. The genus *Hepatozoon* (Apicomplexa: Adeleina). *Journal of Parasitology* 82: 565–585.
- , AND S. S. DESSER. 1997. Phylogenetic analysis of the genus *Hepatozoon* Miller, 1908 (Apicomplexa: Adeleorina). *Systematic Parasitology* 36: 213–221.

Received for publication 26 October 2004.