

EXTRINSIC FACTORS SIGNIFICANTLY AFFECT PATTERNS OF DISEASE IN FREE-RANGING AND CAPTIVE CHEETAH (*ACINONYX JUBATUS*) POPULATIONS

Authors: Munson, Linda, Terio, Karen A., Worley, Michael, Jago, Mark, Bagot-Smith, Arthur, et al.

Source: Journal of Wildlife Diseases, 41(3) : 542-548

Published By: Wildlife Disease Association

URL: <https://doi.org/10.7589/0090-3558-41.3.542>

BioOne Complete (complete.BioOne.org) is a full-text database of 200 subscribed and open-access titles in the biological, ecological, and environmental sciences published by nonprofit societies, associations, museums, institutions, and presses.

Your use of this PDF, the BioOne Complete website, and all posted and associated content indicates your acceptance of BioOne's Terms of Use, available at www.bioone.org/terms-of-use.

Usage of BioOne Complete content is strictly limited to personal, educational, and non - commercial use. Commercial inquiries or rights and permissions requests should be directed to the individual publisher as copyright holder.

BioOne sees sustainable scholarly publishing as an inherently collaborative enterprise connecting authors, nonprofit publishers, academic institutions, research libraries, and research funders in the common goal of maximizing access to critical research.

EXTRINSIC FACTORS SIGNIFICANTLY AFFECT PATTERNS OF DISEASE IN FREE-RANGING AND CAPTIVE CHEETAH (*ACINONYX JUBATUS*) POPULATIONS

Linda Munson,^{1,5} Karen A. Terio,¹ Michael Worley,² Mark Jago,³ Arthur Bagot-Smith,⁴ and Laurie Marker⁴

¹ Department of Veterinary Pathology, Microbiology, and Immunology, University of California, Davis, California 95616, USA

² Center for Reproduction of Endangered Species, Zoological Society of San Diego, San Diego, California 92115, USA

³ Otjiwarango Veterinary Clinic, Otjiwarango, Namibia

⁴ Cheetah Conservation Fund, Otjiwarango, Namibia

⁵ Corresponding author (email: lmunson@ucdavis.edu)

ABSTRACT: The cheetah (*Acinonyx jubatus*) has been considered a paradigm for disease vulnerability due to loss of genetic diversity. This species monomorphism has been suspected to be the basis for their general poor health and dwindling populations in captivity. North American and South African captive populations have high prevalences of hepatic veno-occlusive disease, glomerulosclerosis, gastritis, and systemic amyloidosis, diseases that are rare in other species. Unusually severe inflammatory reactions to common infectious agents have also been documented in captive cheetahs. The current study compared disease prevalences in free-ranging Namibian cheetahs with those in two captive populations of similar ages. The occurrence of diseases in the free-ranging population was determined from 49 necropsies and 27 gastric biopsies obtained between 1986 and 2003 and compared with prevalences in 147 North American and 80 South African captive cheetahs. Except for two cheetahs, the free-ranging population was in robust health with only mild lesions present, in contrast with significantly higher prevalences in the captive populations. Despite widespread heavy *Helicobacter* colonization in wild cheetahs, only 3% of the free-ranging population had moderate to severe gastritis, in contrast with 64% of captive cheetahs. No severe inflammatory reactions to viral infections were detected in the free-ranging animals. Because free-ranging Namibian cheetahs are as genetically impoverished as captive cheetahs, these findings caution against attributing loss of fitness solely to genetic factors and attest to the fundamental importance of extrinsic factors in wildlife health.

Key words: *Acinonyx jubatus*, gastritis, glomerulosclerosis, pathology, veno-occlusive disease.

INTRODUCTION

Loss of polymorphism is common to many endangered species, but whether low genetic diversity correlates with loss of fitness remains unproven. Although most terrestrial carnivores lack the diversity of other mammals, cheetahs (*Acinonyx jubatus*) are unique in the extent to which they have lost polymorphism (O'Brien et al., 1983), and this homogeneity has been suspected as the cause of poor health and reproductive failure in captivity (O'Brien et al., 1985; O'Brien and Evermann, 1988; Marker-Kraus, 1997). High neonatal mortality rates in cheetahs have been cited as further evidence of genetic impoverishment (O'Brien et al., 1985). However, subsequent studies have shown predation to be the principal cause of death in wild

cheetah cubs (Laurenson et al., 1995), and management to affect rates of juvenile mortality in captivity (Wielebnowski, 1996). Although fitness is usually measured by reproductive parameters, compromised health may be of equal consequence.

Cheetahs were suspected to be particularly vulnerable to infectious diseases because the species lacks heterogeneity at MHC loci that encode peptides mediating immune responsiveness to pathogens (O'Brien et al., 1983, 1985, 1987). The occurrence of catastrophic feline infectious peritonitis (FIP) epidemics in captive cheetahs was cited as support for this hypothesis (Evermann et al., 1983). The propensity for cheetahs to maintain persistent viral infections and develop atypical immune responses to common pathogens

(Evermann et al., 1988; Junge et al., 1991; Eaton et al., 1993; Steinell et al., 2000; Munson et al., 2003) may also have a genetic basis, although modulation of the immune response by chronic stress has also been proposed (Terio et al., 2004). In light of these suspected inherent vulnerabilities to viral agents, we were surprised to find that morbidity and mortality in North American (NA) cheetahs were principally due to chronic degenerative diseases, such as veno-occlusive disease, glomerulosclerosis, and amyloidosis, rather than infectious disease (Munson, 1993; Papendick et al., 1997; Bolton and Munson, 1999). Furthermore, the prevalence and severity of these diseases in both captive populations differed among facilities, suggesting an environmental effect.

To investigate this possible environmental influence, we surveyed a population of free-ranging cheetahs from the farmlands of north central Namibia (Marker et al., 2003) for similar diseases. This population historically produced the founders of NA and South African (SA) captive populations (Marker-Kraus, 1997). If veno-occlusive disease, glomerulosclerosis, gastritis, and amyloidosis have a purely heritable basis, then free-ranging Namibian cheetahs should have similar high prevalences of these diseases. As free-ranging cheetahs in this region are exposed to the same viruses as captive populations (Munson et al., 2004) and are as genetically impoverished as captive cheetahs, this population would also be expected to have compromised health from persistent viral diseases.

MATERIALS AND METHODS

Because histopathology is the only definitive method to detect the diseases of interest, organ samples were obtained opportunistically from 49 free-ranging cheetahs that died between 1986 and 2003 in the farmland region of north central Namibia (19°30'S to 23°30'S and 16°E to 19°E). Necropsies were performed by local biologists, veterinarians, or hunters on cheetahs that died from gunshot ($n=38$), vehicular trauma ($n=5$), choke ($n=3$), capture cage trauma ($n=1$), or euthanasia due to infection ($n=2$). Wild-caught animals held captive for ≤ 30 days

were included in the study because that interval was considered insufficient for the development of chronic degenerative diseases as a result of captivity. Gastric biopsies collected during routine health exams of 27 cheetahs, captured by farmers to avert threats to livestock (Marker et al., 2003), were also included in the study. Gastric biopsies were obtained under general anesthesia (Telazol®; tiletamine-HCl and zolazepam-HCl; 4 mg/kg IM; Warner Lambert, Ann Arbor, Michigan, USA). All cheetahs were intubated and then 15 biopsies were obtained from the gastric fundus with a flexible, fiberoptic endoscope (donated by Olympus America, Inc., Melville, New York, USA) and a 2.0-mm flexible biopsy forcep (Endoscopy Support Services, Inc., Brewster, New York, USA).

Age classification took into account body weight, body size, tooth wear, gum recession, wear on pads, pelage and scarring, social groupings of animals caught together, and reproductive condition (Marker and Dickman, 2002). Lower premolars were categorized by cementum aging, and these results correlated with other age estimates (Marker and Dickman, 2002). Only those cheetahs that were 24 or more months old (approximate age of sexual maturity) were included in the study because the diseases prevalent in captive animals occur principally in adults (Munson, 1993; Munson et al., 1999). The Namibian study animals ranged from 2 to 10 yr old (median age=6 yr) with only one animal >8 yr old. The study population included 41 males, 27 females, and eight animals of unrecorded sex.

Tissues were fixed in 10% buffered formalin, paraffin embedded, sectioned at 7 μm , and stained with hematoxylin and eosin (H&E). Samples of liver and kidney were also stained with Masson's trichrome (Luna, 1992), and sections of stomach were stained with Warthin Starry's silver stain (Luna, 1992). Veno-occlusive disease (VOD), glomerulosclerosis, and gastritis were graded by one author (L.M.) using previously published criteria (Munson, 1993; Munson et al., 1999). Lymphoid aggregates in the deep lamina propria of the stomach were considered normal and were not included in gastritis grading (Stolte and Meining, 2001).

Samples from all organs of each animal were not available, so prevalence statistics were calculated as a percentage of organ samples available. Histopathology results from 48 liver, 47 kidney, 61 stomach, 35 lung, 34 heart, 33 small intestine, 31 colon, 32 spleen, 26 pancreas, 23 adrenal gland, and 17 skeletal muscle samples were used for prevalence statistics. Brains from nine cheetahs and reproductive tracts from 19 males and 11 females were also evaluated.

Histopathology information on NA and SA

TABLE 1. Lesion prevalence in free-ranging Namibian cheetahs in comparison with captive South African (SA) and North American (NA) cheetahs.

Lesion	Free-ranging Namibian cheetahs n=76	Captive SA cheetahs ^a n=80	Captive NA cheetahs ^a n=147
Gastritis	7/62 (11%) ^b	69/70 (99%)	109/110 (99%)
<i>Helicobacter</i> colonization	54/61 (88%)	29/35 ^c (83%)	91/110 (83%)
Glomerulosclerosis	6/47 (13%)	22/27 (81%)	32/48 (67%)
Renal amyloidosis	2/47 (4%)	10/27 (37%)	17/48 (35%)
Veno-occlusive disease	4/48 (8%)	12/28 (43%)	51/81 (63%)
Adrenal cortical hyperplasia	2/23 (9%)	13/14 (93%)	20/36 (56%)

^a Only cheetahs 2–8 yr are included to conservatively match the age range of free-ranging cheetahs. A subset of this data has been published previously. (Munson, 1993; Papendick et al., 1997; Bolton and Munson, 1999).

^b Prevalences are expressed as the proportion (%) of tissues available. Lesions of all grades are included.

^c Not all gastric biopsies had Warthin Starry stains available to confirm the presence of bacteria.

animals were obtained from the cheetah pathology database developed by one author (L.M.). The NA and SA animals died between 1988 and 2002; a subset of this data was previously reported (Munson, 1993; Munson et al., 1999). All histopathology was performed by the same pathologist (L.M.) using consistent classification and grading of lesions (Munson, 1993; Munson et al., 1999). Only data from captive cheetahs 2–8 yr old were included for prevalence comparisons because all except one Namibian cheetah were in this age range. Because the diseases of concern tend to increase with age, exclusion of older captive animals from the analyses was considered the most conservative comparison. The single Namibian animal older than this range (estimated as 10 yr old) had only gastric biopsies available for the study. Captive animals that met the age criteria included 147 US cheetahs (47 necropsies and 100 gastric biopsies) and 80 SA cheetahs (30 necropsies and 50 gastric biopsies). The median age for the NA population was 5.5 yr and for the SA population was 5 yr. All captive animals in this study were captive born.

Descriptive statistics were performed for all three populations. Lesion prevalences in free-ranging Namibian cheetahs were then compared by Fisher's exact test with prevalences in NA and SA captive cheetahs of the same age range.

RESULTS

Overall, the free-ranging Namibian cheetah population was remarkably free of disease. Lesions that are common and usually severe in captive cheetahs were found only rarely in free-ranging Namibian cheetahs and usually only to a mild degree (Table 1). Captive cheetahs were significantly

more likely than free-ranging cheetahs to develop gastritis (RR=79.84; 95% CI, 20.06–317.79; $P<0.0001$) or VOD (RR=2.17; 95% CI, 1.72–2.75; $P<0.0001$). Most striking was the relative absence in free-ranging cheetahs of moderate to severe forms of these diseases (Fig. 1) that account for considerable morbidity and mortality in captive animals. In contrast with captive cheetahs, the majority of free-ranging cheetahs did not have gastritis despite being heavily colonized with *Helicobacter* (Fig. 2).

In addition to the lesions listed in Table 1, only one of 32 free-ranging cheetahs from which spleen was available had myelolipomas, in contrast with three of 23 SA cheetahs and 13 of 45 NA cheetahs. Five of 34 free-ranging cheetahs, nine of 18 SA cheetahs, and six of 45 NA cheetahs had cardiac fibrosis. Conspicuously absent from the free-ranging population was any evidence of viral diseases that afflicted the captive populations, in contrast with seven cases of FIP, three cases of herpes viral infection, and four cases of parvoviral enteritis in the captive-animal populations.

Although most free-ranging cheetahs had minimal or no disease, two animals had notably severe lesions. One 3-yr-old male had end-stage renal disease caused by amyloidosis and glomerulosclerosis. This animal also had severe VOD, cardiac fibrosis, adrenal cortical hyperplasia, and splenic lymphoid depletion, all common

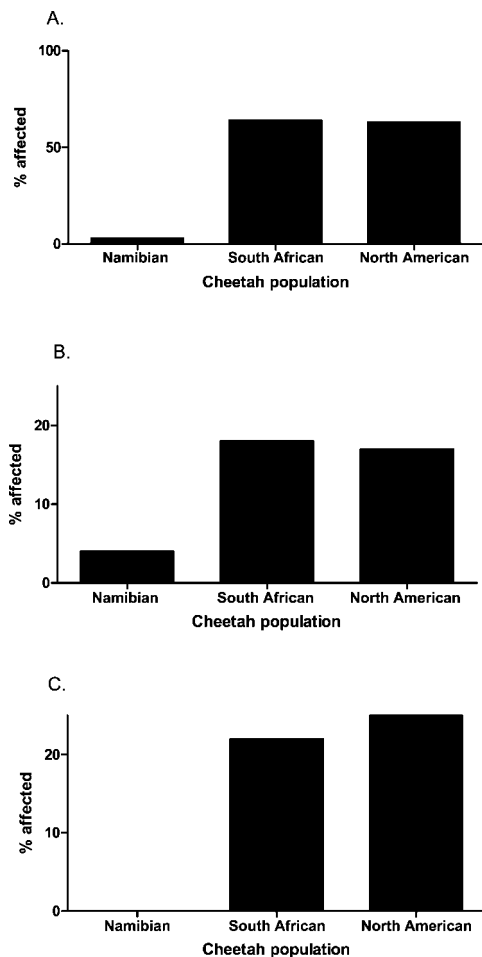


FIGURE 1. Prevalence of moderate to severe disease in free-ranging Namibian cheetahs in comparison to captive South African (SA) and North American (NA) populations. Only cheetahs 2–8 yr old from NA and SA populations are included to match the age range of Namibian cheetahs. (A) Moderate to severe gastritis. One of the two free-ranging cheetahs had only focal gastritis with no gastritis in the other 15 gastric biopsy samples. (B) Moderate to severe veno-occlusive disease (VOD). One of the two free-ranging cheetahs with VOD had only a small region of affected liver. (C) Moderate to severe glomerulosclerosis.

lesions in captive NA and SA cheetahs. Another animal, a 2-yr-old male with severe osteoarthritis of the scapulohumeral joint, had severe gastritis and renal amyloidosis. Adrenal glands were not available from this animal to screen for cortical hyperplasia, a morphological indicator of chronic stress.

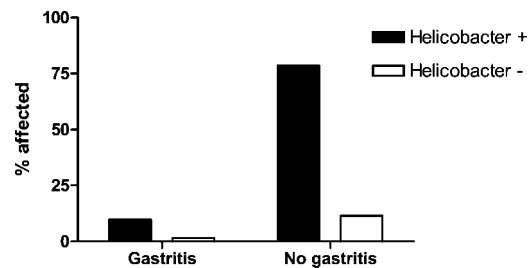


FIGURE 2. Association between *Helicobacter* colonization and gastritis in free-ranging Namibian cheetahs ($P=1.0$).

DISCUSSION

The excellent health of the free-ranging Namibian cheetah population was confirmed by this pathology survey. Although the Namibian study animals did not die for health reasons and may have been biased toward more healthy animals, it also could be argued that animals shot for livestock depredation represent the less fit individuals within a population (Marker et al., 2003). Although the occurrence of these typically rare conditions in three geographically distinct cheetah populations suggests a predisposition in this species, the absence of significant health problems in most free-ranging cheetahs that are as genetically depauperate as their captive counterparts (O'Brien et al., 1983) indicates that, functionally, genetics is not the only factor determining fitness in this species. Only an environmental effect could account for the high disease prevalences that were observed solely in the captive populations. Thus, a physiologic response to the local environment is likely of equal importance and perhaps of greater importance than genetic influences in determining health in cheetahs.

The relative absence of VOD, gastritis, amyloidosis, and glomerulosclerosis in the free-ranging population in comparison with high prevalences in captive animals of equivalent age suggests that these diseases do not solely occur in captive animals because they tend to live longer than wild cheetahs. Diet also does not appear to be the primary factor in disease development.

South African cheetahs that are genetically similar to NA cheetahs (O'Brien et al., 1983) but have diets of unprocessed meat or whole carcasses (comparable with the diet of free-ranging cheetahs) had similar high prevalences of the same unusual diseases as NA cheetahs (Munson et al., 1999). An additional interesting result of this study was confirmation that VOD can occur in free-ranging animals, which refutes the hypothesis that estrogens in captive diets cause VOD (Setchell et al., 1987).

Current medical research is disclosing substantial adverse effects of chronic stress on human health (Sapsee, 1997; Sher, 2004), and the immunologic and metabolic alterations that develop during persistent hypercortisolemia may also affect cheetahs. We have previously measured higher fecal corticoid concentrations and larger adrenal cortices (physiologic and morphologic indices of chronic stress) in captive cheetahs (Terio et al., 2004). Additionally, a higher proportion of captive cheetahs have adrenal cortical hyperplasia than free-ranging cheetahs (Table 1). We further have documented a prolonged elevation of corticosteroids in response to environmental change in cheetahs (Wells et al., 2004). We have suspected that persistent hypercortisolemia may influence the development of glomerulosclerosis (Bolton and Munson, 1999) and may stimulate cytokine shifts (Chiapelli et al., 1994; Ramirez, 2003) that favor the development of gastritis. The high prevalence of *Helicobacter* in wild cheetahs in the absence of gastritis substantiates our suspicion that *Helicobacter* is a commensal organism. The relative absence of diseases in the free-ranging cheetah population that also had significantly lower corticoid levels provides further support for a role of chronic stress in the pathogenesis of these diseases.

The aspects of the captive environment that promote this adrenal response have not been elucidated. Restricted space and lack of exercise in captivity are possible

stress factors (Mason et al., 2001; Clubb and Mason, 2003) because free-ranging cheetahs have large home ranges as well as physical and behavioral adaptations for chasing prey (Marker, 2003). Cheetahs also are largely solitary, avoiding contact with humans, other carnivores, and unrelated cheetahs except during mating (Caro, 1994). Involuntary exposure to other animals in captivity could be perceived as threatening, leading to chronic stress. A theory that would embrace current genetic, ecological, and biomedical knowledge of the cheetah would be that loss of polymorphism has limited the capacity of this species to adapt to the captive environment, resulting in a chronic stress response that exacerbates and accelerates disease development by modulating normal physiologic homeostasis and immunity.

If, as these data suggest, the genetically impoverished cheetah is not adaptable to environmental change, then conservation strategies should focus on preserving habitat so that free-ranging populations can flourish. If capture and translocation induce physiological responses that affect homeostasis, then their increasing use in conservation management and censusing (Marker, 2003) is of concern. To investigate this possibility, we currently are monitoring the development of degenerative and inflammatory diseases in previously free-ranging cheetahs that have been captured by farmers as problem animals and then kept in captivity because they were nonreleasable. A fundamental understanding of the extrinsic factors that affect cheetah health will be essential to preserve robust self-sustaining populations.

ACKNOWLEDGMENTS

The authors thank the Namibian farmers and the Namibian government, particularly the Ministry of Environment and Tourism, without whose support this long-term research would not have been possible. We are also grateful to the team of CCF staff and volunteers, especially Bonnie Schumann, Jane Fink, Audrey Pickup, Sandy Hurlbut, Daniel Kraus, Mandy

Schumann, and to local veterinarians, Ulf Tubbesing, Hermann Scherer, and Axel Hartman, for performing necropsies. Scott Citino from White Oak Conservation Center trained Namibian veterinarians in biopsy technique, and Olympus Corporation generously donated the endoscope. We thank the many Namibian farmers and members of the Namibian Professional Hunters Association for submission of necropsy samples for this survey, particularly Jochen Hein, Thodo Garbade, and Hartmu von Seydlitz. The authors thank Dieter Morsbach, previously from the Namibian Ministry of Environment and Tourism, for facilitating sample collection from 1985 to 1990. We thank Lorna Bolton, Rebecca Papendick, and Ali Brower for assisting with histopathology. Partial funding for this research was provided by the Cheetah Conservation Fund-USA, Cincinnati Zoo, Earthwatch Institute, the Tapeats Foundation, the Weeden Foundation, White Oak Conservation Center, the WWF SA Green Trust, and the University of Tennessee. All tissue samples were collected in full compliance with specific Federal Fish and Wildlife permits (Convention on International Trade in Endangered Species of Wild Fauna and Flora [CITES]; Endangered and Threatened Species) issued to the National Cancer Institute, National Institutes of Health (principal officer S. J. O'Brien) and to Michael Worley (Zoological Society of San Diego) by the US Fish and Wildlife Service of the Department of the Interior, as well as CITES permits issued to the Cheetah Conservation Fund (principal officer L. Marker) from the Namibian Ministry of Environment and Tourism.

LITERATURE CITED

- BOLTON, L. A., AND L. MUNSON. 1999. Glomerulosclerosis in captive cheetahs (*Acinonyx jubatus*). *Veterinary Pathology* 36: 14–22.
- CARO, T. M. 1994. Cheetahs of the Serengeti Plains: Group living in an asocial species. University of Chicago Press, Chicago, Illinois. 478 pp.
- CHIAPELLI, F., E. MANFRINI, C. FRANCESCHI, A. COSSARIZZAN, AND K. L. BLACK. 1994. Steroid regulation of cytokines: Relevance for Th1 to Th2 shift? *Annals of the New York Academy of Sciences* 746: 204–215.
- CLUBB, R., AND G. MASON. 2003. Captivity effects on wide-ranging carnivores. *Nature* 425: 473–474.
- EATON, K. A., M. J. RADIN, L. KRAMER, R. WACK, R. SHERDING, J. G. KRAKOWKA, J. G. FOX, AND D. R. MORGAN. 1993. Epizootic gastritis in cheetahs associated with spiral bacteria. *Veterinary Pathology* 30: 55–63.
- EVERMANN, J. G., G. BURNS, M. E. ROELKE, A. J. MCKEIRNAN, A. GREENLEE, A. C. WARD, AND M. L. PFEIFER. 1983. Diagnostic features of an epizootic of feline infectious peritonitis in captive cheetahs. *American Association of Veterinary Laboratory Diagnosticians* 26: 365–382.
- , J. L. HEENEY, M. E. ROELKE, A. J. MCKEIRNAN, AND S. J. O'BRIEN. 1988. Biological and pathological consequences of feline infectious peritonitis virus infection in the cheetah. *Archives of Virology* 102: 155–171.
- JUNGE, R. E., R. E. MILLER, W. J. BOEVER, G. SCHERBA, AND J. SUNDBERG. 1991. Persistent cutaneous ulcers associated with feline herpesvirus type 1 infection in a cheetah. *Journal of the American Veterinary Medical Association* 198: 1057–1058.
- LAURENSEN, M. K., N. WIELEBNOWSKI, AND T. M. CARO. 1995. Extrinsic factors and juvenile mortality in cheetahs. *Conservation Biology* 9: 1329–1331.
- LUNA, L. G. 1992. Histopathologic methods and color atlas of special stains and tissue artifacts. Johnson Printers, Downers Grove, Illinois. 767 pp.
- MARKER, L. 2003. Aspects of the Namibian cheetah: Biology, ecology and conservation strategies. PhD Dissertation, University of Oxford, 475 pp.
- , AND A. J. DICKMAN. 2002. Morphometrics of the Namibian cheetah. *Journal of Mammology* 84: 322–332.
- , ———, M. G. L. MILLS, AND D. W. MACDONALD. 2003. Aspects of the management of cheetahs trapped on Namibian farmlands. *Biological Conservation* 114: 401–412.
- MARKER-KRAUS, L. 1997. History of the cheetah (*Acinonyx jubatus*) in zoos 1829–1994. *International Zoo Yearbook* 35: 27–43.
- MASON, G. J., J. COOPER, AND C. CLAREBROUGH. 2001. Frustrations of fur-farmed mink. *Nature* 410: 35–36.
- MUNSON, L. 1993. Diseases of captive cheetahs (*Acinonyx jubatus*): Results of the Cheetah Research Council pathology survey 1989–1992. *Zoo Biology* 12: 105–124.
- , J. W. NESBIT, D. G. A. MELTZER, L. P. COLLY, L. BOLTON, AND N. P. K. KRIEK. 1999. Diseases of captive cheetahs (*Acinonyx jubatus*) in South Africa: A 20-year retrospective survey. *Journal of Zoo and Wildlife Medicine* 30: 342–347.
- , R. WACK, M. DUNCAN, R. J. MONTALI, D. BOON, I. STALIS, G. J. GRAWSHAW, K. N. CAMERON, J. MORTENSON, S. CITINO, J. ZUBA, AND R. E. JUNGE. 2003. Chronic eosinophilic dermatitis associated with persistent feline herpes virus infection in cheetahs (*Acinonyx jubatus*). *Veterinary Pathology* 41: 170–176.
- , L. MARKER, E. DUBOVI, J. A. SPENCER, J. F. EVERMANN, AND S. J. O'BRIEN. 2004. A serosurvey of viral infections in free-ranging Namibian cheetahs (*Acinonyx jubatus*). *Journal of Wildlife Diseases* 40:23–31.

- O'BRIEN, S. J., AND J. F. EVERMANN. 1988. Interactive influence of infectious disease and genetic diversity in natural populations. *Trends in Ecology and Evolution* 3: 254–259.
- , D. E. WILDT, D. GOLDMAN, C. R. MERRIL, AND M. BUSH. 1983. The cheetah is depauperate in genetic variation. *Science* 221: 459–462.
- , M. E. ROELKE, L. MARKER, A. NEWMAN, C. A. WINKLER, D. MELTZER, L. COLLY, AND J. F. EVERMANN. 1985. Genetic basis for species vulnerability in the cheetah. *Science* 227: 1428–1434.
- , D. E. WILDT, M. BUSH, T. M. CARO, C. FITZGIBBON, I. AGGUNDEY, AND R. E. LEAKEY. 1987. East African cheetahs: Evidence for two population bottlenecks. *Proceedings of the National Academies of Science USA* 84: 508–511.
- PAPENDICK, R. E., L. MUNSON, T. D. O'BRIEN, AND K. H. JOHNSON. 1997. Systemic AA amyloidosis in captive cheetahs (*Acinonyx jubatus*). *Veterinary Pathology* 34: 549–556.
- RAMIREZ, F., 2003. Glucocorticoids induce a Th2 response in vivo. *Developmental Biology* 6: 233–243.
- SAPSE, A. T. 1997. Cortisol, high cortisol diseases, and anti-cortisol therapy. *Psychoneuroendocrinology* 22: S3–S10.
- SETCHELL, K. D. R., S. J. GOSSELIN, M. B. WELSH, J. O. JOHNSTON, W. F. BALISTRERI, L. W. KRAMER, B. L. DRESSER, AND M. J. TARR. 1987. Dietary estrogens—a probable cause of infertility and liver disease in captive cheetah. *Gastroenterology* 93: 225–233.
- SHER, L. 2004. Daily hassles, cortisol, and the pathogenesis of depression. *Medical Hypotheses* 62: 198–202.
- STEINEL, A., L. MUNSON, M. VANVUUREN, AND U. TRUYEN. 2000. Genetic characterization of feline parvovirus sequences from various carnivores. *Journal of General Virology* 81: 345–350.
- STOLTE, M., AND A. MEINING. 2001. The updated Sydney system: Classification and grading of gastritis as the basis for diagnosis and treatment. *Canadian Journal of Gastroenterology* 15: 591–598.
- TERIO, K. A., L. MARKER, AND L. MUNSON. 2004. Evidence for chronic stress in captive but not wild cheetahs (*Acinonyx jubatus*) based on adrenal morphology and function. *Journal of Wildlife Diseases* 40:259–266.
- WELLS, A., K. A. TERIO, M. H. ZICCARDI, AND L. MUNSON. 2004. The stress response to environmental change in captive cheetahs (*Acinonyx jubatus*). *Journal of Zoo and Wildlife Medicine* 35: 8–14.
- WIELEBNOWSKI, N. 1996. Reassessing the relationship between juvenile mortality and genetic monomorphism in captive cheetahs. *Zoo Biology* 15: 353–369.

Received for publication 16 April 2004.