

Mediastinal Lymphoma in a Badger (*Meles meles*)

Authors: Mutinelli, Franco, Vascellari, Marta, and Melchiotti, Erica

Source: Journal of Wildlife Diseases, 40(1) : 129-132

Published By: Wildlife Disease Association

URL: <https://doi.org/10.7589/0090-3558-40.1.129>

BioOne Complete (complete.BioOne.org) is a full-text database of 200 subscribed and open-access titles in the biological, ecological, and environmental sciences published by nonprofit societies, associations, museums, institutions, and presses.

Your use of this PDF, the BioOne Complete website, and all posted and associated content indicates your acceptance of BioOne's Terms of Use, available at www.bioone.org/terms-of-use.

Usage of BioOne Complete content is strictly limited to personal, educational, and non - commercial use. Commercial inquiries or rights and permissions requests should be directed to the individual publisher as copyright holder.

BioOne sees sustainable scholarly publishing as an inherently collaborative enterprise connecting authors, nonprofit publishers, academic institutions, research libraries, and research funders in the common goal of maximizing access to critical research.

Mediastinal Lymphoma in a Badger (*Meles meles*)

Franco Mutinelli,^{1,2} Marta Vascellari,¹ and Erica Melchioti¹ ¹Istituto Zooprofilattico Sperimentale delle Venezie, Histopathology Department, Viale dell'Università 10, 35020 Legnaro (PD), Italy; ²Corresponding author (email: fmutinelli@izsvenezie.it)

ABSTRACT: A case of mediastinal lymphoma in a free-living, adult male European badger (*Meles meles*), from Trento Province (northern Italy) is described. A yellow-red mass delimited by a thick fibrous capsule completely occupied the anterior mediastinum. Based on the histologic and immunohistochemical findings, a diagnosis of mediastinal lymphocytic lymphoma was made. Documentation of neoplasms in free-living species is important for comparison with domestic animals and humans and may give insight into epidemiology of these diseases. To the authors' knowledge, this is the first report of a mediastinal lymphoma in a badger.

Key words: Badger, case report, mediastinal lymphoma, *Meles meles*, tumor.

Lymphoma is a relatively common disease in many domestic and laboratory animal species (Jones et al., 1997). The classification of lymphomas of animals has been recently revised by Valli et al. (2002). Mediastinal lymphoma has been described in young cattle, cats, dogs, and laboratory animals (Valli, 1993).

Among members of the family Mustelidae, lymphoma has been reported in ranch mink (*Mustela vison*) (Lölinger, 1962), striped skunk (*Mephitis mephitis*) (Smith and Barker, 1983), domestic ferrets (Erdman et al., 1992, 1996a, b; Beach and Greenwood, 1993; Coleman et al., 1998), and in a sea otter (*Enhydra lutris*) (Kim et al., 2002). Mediastinal location of lymphoma in ferrets was observed by Symmers and Thomson (1953), Smith and Bishop (1985), and Batchelder et al. (1996). In the European badger, only a suspected lymphoma (Gallagher and Nelson, 1979) has been reported.

Here we report a case of mediastinal lymphocytic lymphoma in a free-living European badger found dead during the disease surveillance program of wild animals in northern Italy.

A free-living, adult male badger was

found dead in Trento Province (northern Italy). Before dying, it was seen wandering near a village showing respiratory signs and weakness. On postmortem examination, no external abnormalities were found, although poor body condition was observed. Based on dental attrition, the badger was estimated to be 4 yr of age (Harris et al., 1992). In the thoracic cavity, a yellow-red mass delimited by a thick fibrous capsule completely occupied the anterior mediastinum (Fig. 1). The trachea, esophagus, and large vessels arising from the heart were completely embedded in the neoplastic mass. The apical and middle lung lobes were hyperemic and atelectic due to compression.

Samples of the neoplastic mass, lung, liver, spleen, and mesenteric lymph nodes were fixed in 10% neutral buffered formalin and routinely processed for histology. Sections were cut at 3 µm and stained with hematoxylin and eosin.

Histologically, the mass was composed of lymphocytes with round, noncleaved nuclei, finely dispersed chromatin, prominent nucleoli, and scant cytoplasm. The cells were closely packed without a clear interstitium. Although many neoplastic cells were of different grades of differentiation, the majority of cells were mature lymphocytes (Fig. 2). The neoplastic proliferation resulted in a complete loss of the normal tissue architecture and the central part of the mass was necrotic. Mitotic figures were rare. A thick proliferation of fibroblasts encapsulated the mass and thin connective tissue septae extended from the capsule into the parenchyma. No remnants of thymus were recognizable. The neoplastic tissue intimately surrounded the wall of the aorta and infiltrated the tunica adventitia. Individual lymphocytic cells were also in

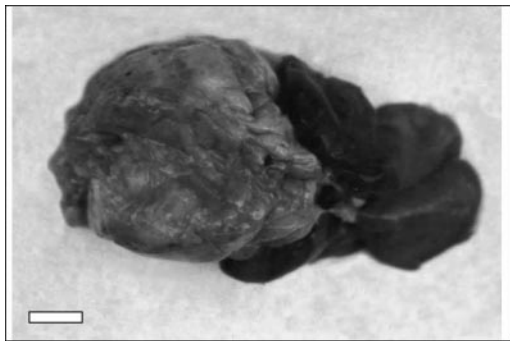


Figure 1

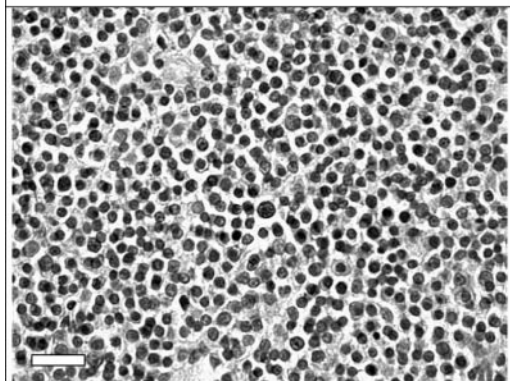


Figure 2




Figure 3

FIGURE 1. A mass delimited by a thick fibrous capsule, completely occupies the anterior mediastinum and compresses the apical and middle lung lobes. Bar = 0.5 cm.

FIGURE 2. Closely packed neoplastic lymphocytes of different grades of maturation and rare mitotic figures (arrow). Hematoxylin and eosin. Bar = 25 μ m.

FIGURE 3. The neoplastic lymphocytic proliferation surrounds and infiltrates the wall of the aorta. Note individual lymphocytes infiltrating the tunica media (insert). Hematoxylin and eosin. Bar = 100 μ m.

the tunica media (Fig. 3). Metastases were not observed in other organs. Additional sections of the neoplasm were processed for immunohistochemistry and tested with polyclonal rabbit anti-human CD3 (08-1102; Zymed, San Francisco, California, USA), monoclonal mouse anti-human CD79 α (M7051; DAKO, 1:10, Carpinteria, California) and monoclonal mouse anti-human cytokeratins (M821, 1:100; DAKO). Antigen retrieval was conducted by pressure cooking for 25 min in citrate buffer, pH 6.1 (S2031; DAKO), for CD79 α , and by trypsin digestion for 30 min at 37C for CD3 and cytokeratins. The EnVision[®] Peroxidase mouse/rabbit detection system (K5007; DAKO) and 3-amin-9-ethylcarbazole (001111; Zymed) as chromogen were applied. Sections were counterstained with methyl green (S1962; DAKO). Samples of mesenteric lymph node and skin of the same animal were used as positive control for CD receptors and cytokeratins, respectively. About 30% of neoplastic cells were positive labeled with anti-CD3 antibody, while all cells were negative for anti-CD79 α and cytokeratins.

On the basis of histologic and immunohistochemical findings, the diagnosis of a low-grade mediastinal lymphocytic lymphoma was made. The immunohistochemical reactions allowed differentiation between mediastinal lymphoma and lymphocytic thymoma; cytokeratins are detected in lymphocytic thymoma (Wick, 2002). Immunophenotypic characterization revealed that lymphoma cells were predominantly CD3-positive and CD79 α -negative lymphocytes, which is indicative of T-cell origin.

Lymphoma of the mediastinum affects numerous species, is often of thymic origin, and typically affects juveniles. The neoplastic cells are predominantly of T-cell lineage (Coleman et al., 1998).

It is possible that some of them arise in the anterior mediastinal lymph nodes, but at the time of the diagnosis, the thymus is obliterated. Characteristically, the tumors reach a large size with dorsocaudal dis-

placement of the lungs. There was no evidence of involvement of lymph nodes or other organs despite the fact that the tunica adventitia of the aorta was infiltrated by neoplastic cells.

Lymphomas and leukemias have been associated with retroviral infections in many mammalian species, including human T-cell leukemia viruses, bovine leukemia virus, and feline leukemia virus (Erdman et al., 1995; Jones et al., 1997). Burkitt's lymphoma in children, which is associated with the Epstein-Barr virus, is characterized histologically as small, non-cleaved lymphoma and phenotypically as B-cell tumor (Sandlund et al., 1996). Horizontal transmission of malignant lymphoma was demonstrated in ferrets and retroviral infection was suspected in some outbreaks of lymphoma in ferrets (Erdman et al., 1995, 1996b), even though an etiologic agent was not identified. Similarity of the lesions observed in the badger to those in ferrets suggests the possible involvement of retroviruses. Unfortunately, virus isolation was not attempted and the etiology of this neoplasm was not determined.

Only one case of suspected lymphoma has been reported in the badger. This animal had enormous enlargement of all the peripheral nodes and variable enlargement of visceral nodes. Gross involvement of the other viscera was not apparent but autolysis precluded histologic confirmation of lymphoma (Gallagher and Nelson, 1979). To the authors' knowledge, this is the first report of a mediastinal lymphoma in a badger. Additional cases of mediastinal lymphoma need to be described to evaluate the prevalence, behavior, and etiology of this neoplasm in badgers. The case reported herein contributes to the limited information available on neoplasia in free-living species and highlights some similarities with domestic animals and humans.

LITERATURE CITED

- BATCHELDER, M. A., S. E. ERDMAN, X. LI, AND J. G. FOX. 1996. A cluster of cases of juvenile mediastinal lymphoma in a ferret colony. *Laboratory Animal Science* 46: 271–274.
- BEACH, J. E., AND B. GREENWOOD. 1993. Spontaneous neoplasia in the ferret (*Mustela putorius furo*). *Journal of Comparative Pathology* 108: 133–147.
- COLEMAN, L. A., S. E. ERDMAN, M. C. SCHRENZEL, AND J. G. FOX. 1998. Immunophenotypic characterization of lymphomas from the mediastinum of young ferrets. *American Journal of Veterinary Research* 59: 1281–1286.
- ERDMAN, S. E., F. M. MOORE, R. ROSE, AND J. G. FOX. 1992. Malignant lymphoma in ferrets: Clinical and pathological findings in 19 cases. *Journal of Comparative Pathology* 106: 37–47.
- , K. A. REIMANN, F. M. MOORE, P. J. KANKI, Q. C. YU, AND J. G. FOX. 1995. Transmission of a chronic lymphoproliferative syndrome in ferrets. *Laboratory Investigation* 72: 539–546.
- , S. A. BROWN, T. A. KAWASAKI, F. M. MOORE, X. LI, AND J. G. FOX. 1996a. Clinical and pathological findings in lymphoma in ferrets: 60 cases (1982–1994). *Journal of the American Veterinary Medical Association* 208: 1285–1289.
- , P. J. KANKI, F. M. MOORE, S. A. BROWN, T. A. KAWASAKI, K. W. MIKULE, K. U. TRAVERS, S. F. BADYLAK, AND J. G. FOX. 1996b. Clusters of malignant lymphoma in ferrets. *Cancer Investigation* 14: 225–230.
- GALLAGHER, J., AND J. NELSON. 1979. Cause of ill health and natural death in badgers in Gloucestershire. *The Veterinary Record* 105: 546–551.
- HARRIS, S., W. J. CRESSWELL, AND C. L. CHEESEMAN. 1992. Age determination of badgers (*Meles meles*) from tooth wear: The need for a pragmatic approach. *Journal of Zoology* 228: 679–684.
- JONES, T. C., R. D. HUNT, AND N. W. KING. 1997. The hemic and lymphatic system. In *Veterinary pathology*, 6th Edition, T. C. Jones, R. D. Hunt and N. W. King (eds.). William and Wilkins, Baltimore, Maryland, pp. 1034–1042.
- KIM, J. H., B. H. KIM, J. H. KIM, M. J. YOO, AND D. Y. KIM. 2002. Lymphoma in a sea otter (*Enhydra lutris*). *Journal of Wildlife Diseases* 38: 616–617.
- LÖLIGER, H. C. 1962. Geschwulstbildungen beim Nerz. *Berliner und Münchener Tierärztliche Wochenschrift* 75: 372–375.
- SANDLUND, J. T., J. R. DOWNING, AND W. M. CRIST. 1996. Non-Hodgkin's lymphoma in childhood. *New England Journal of Medicine* 19: 1238–1248.
- SMITH, D. A., AND I. K. BARKER. 1983. Four cases of Hodgkin's disease in striped skunks (*Mephitis mephitis*). *Veterinary Pathology* 20: 223–229.
- , AND S. P. BISHOP. 1985. Diagnostic exercise: Lymphoproliferative disorder in a ferret. *Laboratory Animal Science* 35: 291–293.
- SYMMERS, W. S. C., AND A. P. D. THOMSON. 1953.

- Multiple carcinomata and focal mast-cell accumulations in the skin of a ferret (*Mustela furo* L.) with a note on other tumours in ferrets. *Journal of Pathologic Bacteriology* 65: 213–216.
- VALLI, V. E. O. 1993. The hematopoietic system. *In* Pathology of domestic animals, 4th Edition, Vol. 3. K. V. F. Jubb, P. C. Kennedy and N. Palmer (eds.). Academic Press, Inc., San Diego, California, pp. 101–265.
- , R. M. JACOBS, A. L. PARODI, W. VERNAU, AND P. F. MOORE. 2002. Histological classification of hematopoietic tumors of domestic animals. Second Series, Vol. VIII, Washington, D.C., 189 pp.
- WICK, M. R. 2002. Immunohistology of the mediastinum. *In* Diagnostic immunohistochemistry, D. J. Dabbs (ed.). Churchill Livingstone, Philadelphia, Pennsylvania, pp. 241–265.

Received for publication 30 December 2002.