

Malignant Melanoma of the Palpebral Conjunctiva in a Captive Fallow Deer

Authors: Sakai, Hiroki, Yanai, Tokuma, Kawakami, Shigehisa, and Masegi, Toshiaki

Source: Journal of Wildlife Diseases, 37(4) : 816-819

Published By: Wildlife Disease Association

URL: <https://doi.org/10.7589/0090-3558-37.4.816>

BioOne Complete (complete.BioOne.org) is a full-text database of 200 subscribed and open-access titles in the biological, ecological, and environmental sciences published by nonprofit societies, associations, museums, institutions, and presses.

Your use of this PDF, the BioOne Complete website, and all posted and associated content indicates your acceptance of BioOne's Terms of Use, available at www.bioone.org/terms-of-use.

Usage of BioOne Complete content is strictly limited to personal, educational, and non - commercial use. Commercial inquiries or rights and permissions requests should be directed to the individual publisher as copyright holder.

BioOne sees sustainable scholarly publishing as an inherently collaborative enterprise connecting authors, nonprofit publishers, academic institutions, research libraries, and research funders in the common goal of maximizing access to critical research.

Malignant Melanoma of the Palpebral Conjunctiva in a Captive Fallow Deer

Hiroki Sakai,^{1,3} Tokuma Yanai,¹ Shigehisa Kawakami,² and Toshiaki Masegi¹ ¹Department of Veterinary Pathology, Faculty of Agriculture, Gifu University, 1-1 Yanagido, Gifu 501-1193, Japan; ²Gunma Safari park, 1 Okamoto, Tomioka City, Gunma 370-23, Japan; ³Corresponding author (e-mail: shiroki@cc.gifu-u.ac.jp).

ABSTRACT: A case of malignant melanoma in the conjunctiva of the eyelid of a captive 13-yr-old female fallow deer (*Dama dama*) was studied. The black tumor that protruded to the palpebral conjunctiva of the right lower eyelid consisted of an infiltrative growth of melanin-containing neoplastic cells with marked cytological atypia. The tumor involved the conjunctiva of the right lower eyelid and infiltrated to the conjunctival epithelial layer, but did not reach the palpebral skin. Numerous mitotic figures and lymphatic invasions were observed. This is a very rare case of a malignant melanoma arising from the palpebral conjunctiva in a wild ruminant.

Key words: Case report, *Dama dama*, fallow deer, malignant melanoma, palpebral conjunctiva.

Eyelid melanomas arise from haired skin or palpebral conjunctiva. Melanomas of the haired skin of eyelids, which are rare in domestic animals other than dogs (Wilcock, 1993), are almost invariably benign and closely resemble benign melanomas elsewhere in the skin (Wilcock, 1993). In contrast, melanomas arising in the conjunctiva, which are very infrequent compared to all other ocular melanomas, are usually malignant (Pullery and Stannard, 1990; Goldschmidt and Shofer, 1992; Wilcock, 1993). Their relationship to eyelid melanomas seems analogous to melanomas of the lip; those of the haired exterior lip are benign and those of the mucous membrane of the inside of the lip are malignant (Wilcock, 1993). Conjunctival melanomas have been reported in dogs (Diters et al., 1983) and cats (Belkin, 1975; Cook et al., 1985). In the eyelid melanoma of a cat described by Cook et al. (1985), the tumor had invaded the conjunctival epithelium and deeper tissues. So, it arose from the palpebral conjunctiva. Eyelid melanomas of gray-skinned horses are re-

ported; these melanomas arose from haired skin, not palpebral conjunctiva (Fleury et al., 2000). Herein, we describe a case of malignant melanoma in the palpebral conjunctiva of a captive fallow deer (*Dama dama*).

A 13-yr-old female fallow deer kept in Gunma Safari park (Gunma Prefecture, Japan; 36°24'N, 139°4'E) had a 1 cm black tumor mass on the palpebral conjunctiva of the right lower eyelid. Despite being removed three times, the tumor recurred and grew to a size of approximately 5 cm. The center of the tumor was severely necrotized. As the tumor grew, the right side of the face was swollen and the deer's appetite decreased. Eventually the animal collapsed and was euthanatized by an overdose of pentobarbital (pentobarbital sodium salt, Nacalai tesque, Kyoto, Japan; 100 mg/kg body weight given intravenously).

A complete necropsy was performed immediately after death. The necropsy revealed a 10 cm tumor on the right eyelid. The tumor protruded to the palpebral conjunctiva (Fig. 1). The overlying conjunctiva was severely ulcerated. The globe was oppressed by the tumor mass, but invasion of the tumor was not observed. The mass was black, firm, and lobulated on the cut sections (Fig. 1), with prominent central necrosis. The palpebral skin was intact. No metastatic lesions were observed in any of the other organs examined.

Organs were collected and fixed in 10% neutral buffered formalin. Paraffin sections from major organs (liver, spleen, heart, kidneys, lungs, pancreas, stomach, small intestine and large intestine) and the right eyelid tumor were cut at 5 μ m, and were stained with hematoxylin and eosin. The serial sections of the tumor also were



FIGURE 1. Marginal part of eyelid with tumor. Formalin-fixed sample. The tumor mass was black and firm. The tumor protruded to the palpebral conjunctiva (arrows) and ruptured. The palpebral skin and meibomian glands (arrowhead) were intact. Bar = 1 cm.

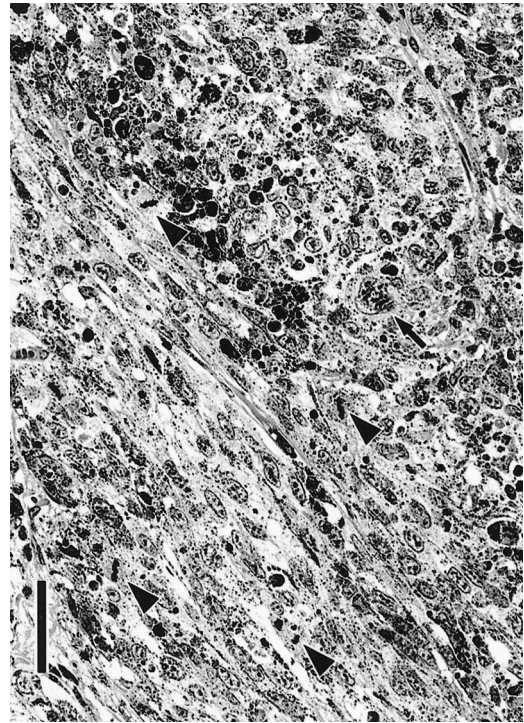


FIGURE 2. The tumor contained cells with a modest amount of black melanin. Anisokaryosis was marked and large bizarre nuclei (arrow) were scattered throughout. There were also numerous mitotic figures (arrowheads). HE stain. Bar = 50 μ m.

stained with Masson's trichrome, Fontana-Masson stain and the bleaching method (potassium permanganate-oxalic acid method) for melanin pigment (Orchard, 1999). Samples of formalin-fixed tumor tissue were fixed with 1% osmium tetroxide (Nissin EM, Tokyo, Japan) and, after being dehydrated in a series of graded ethanols, were embedded in Luveak R (EMS, Washington, Pennsylvania, USA). Ultra-thin sections were cut and double-stained with uranyl acetate and lead citrate, and examined with an electron microscope (H-8100, Hitachi Ltd., Tokyo, Japan) at 75 KV.

Microscopically, the tumor consisted of an infiltrative growth of melanocytic tumor cells. The tumor cells contained various amount of black-brown melanin pigment, which turned black under the Fontana-Masson stain, and were colorless when

treated with the bleaching method. The tumor involved the conjunctiva of the right lower eyelid and some neoplastic cells infiltrated to the conjunctival epithelial layer. Moreover, neoplasm had infiltrated to the orbicularis oculi muscles but had not reached the palpebral dermis. The tumor cells tended to be arranged in alveolar formations, and irregular branching strands of fine connective tissue which turned blue with Masson's trichrome stain were visible. In some areas, neoplastic spindle cells displayed an interwoven pattern (Fig. 2). There were frequent invasions of the tumor into lymphatic vessels (Fig. 3). The tumor showed prominent central necrosis and severe infiltration of neutrophils in the eyelids and subcutaneous tissue of the right side of the face. The tumor cells varied in shape from cuboidal to fusiform and showed prominent pleomorphism. Nuclei

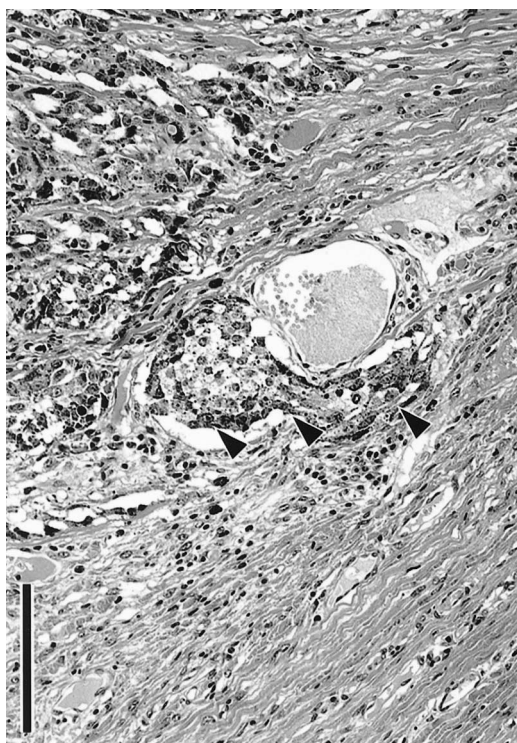


FIGURE 3. Lymphatic invasion of tumor. Melanotic neoplasm cells invaded the lymphatic vessel (arrowheads). Bar = 100 μ m.

varied from ovoid to fusiform, depending upon the cytoplasmic morphology. Anisokaryosis was marked and large bizarre nuclei were scattered throughout (Fig. 2). Numerous mitotic figures were observed at the rate of 10–20/10 high power fields (HPF).

Ultrastructurally, there were numerous highly electron-dense melanosomes in the cytoplasm of the neoplastic cells. These melanosomes varied from 200 to 600 nm in diameter, and immature melanosomes consisting of laminal components were scattered throughout the cytoplasm.

The criteria used for distinguishing benign from malignant melanotic neoplasms are based on the anatomic location and cytological features of tumors in dogs (Goldschmidt and Shofer, 1992). Grossly, the present tumor protruded from the inside of the eyelid, and the palpebral skin was intact. Moreover, with the histopathologi-

cal examination, despite the invasion of the tumor, it did not associate with the palpebral skin. Therefore, we considered that the tumor arose from the conjunctiva of the eyelid. There was much cytological and nuclear atypia in this case, and lymphatic invasions were frequent. The mitotic index is used as a prognostic criteria in canine melanoma (Bostock, 1979). Malignant melanomas have increased numbers of mitotic figures ($>3/10$ HPF) (Goldschmidt and Shofer, 1992). In our deer melanoma case, numerous mitotic figures were observed. Therefore, this deer palpebral melanoma was diagnosed as malignant. In the uveal tract, corneoscleral junction, and the conjunctiva melanocytes are found. Melanoma of these structures have been reported in various domestic animals (Belkin, 1975; Ditters et al., 1983; Dietz et al., 1986; Patnaik and Mooney, 1988; Wilcock, 1993). However, fewer cases of melanomas arising from palpebral conjunctiva have been reported. To our knowledge, there are no existing reports of melanocytic tumors in deer or other wild ruminants which makes the present case a very rare occurrence.

LITERATURE CITED

- BELKIN, P. V. 1975. Malignant melanoma of the bulbar conjunctiva in a dog. *Veterinary Medicine Small Animal Clinician* 70: 957–958.
- BOSTOCK, D. E. 1979. Prognosis after surgical excision of canine melanomas. *Veterinary Pathology* 16: 32–40.
- COOK, C. S., W. ROSENKRANTZ, R. L. PEIFFER, AND A. MACMILLAN. 1985. Malignant melanoma of the conjunctiva in a cat. *Journal of the American Veterinary Medical Association* 186: 505–506.
- DIETZ, H. H., O. A. JENSEN, AND J. B. JORGENSEN. 1986. Malignant melanoma of the uvea in the dog. *Nord Veterinary Medicine* 38: 68–73.
- DITERS, R. W., R. R. DUBIELZIG, G. D. AGUIRRE, AND G. M. ACLAND. 1983. Primary ocular melanoma in dogs. *Veterinary Pathology* 20: 379–395.
- FLEURY, C., F. BERARD, B. BALME, AND L. THOMAS. 2000. The study of cutaneous melanomas in Camargue-type gray-skinned horses (1): clinical-pathological characterization. *Pigment Cell Research* 13: 39–46.
- GOLDSCHMIDT, M. H., AND F. S. SHOFER. 1992. Mel-

- anoma. *In* Skin tumor of the dog & cat. Pergamon Press, New York, New York, pp. 131–141.
- ORCHARD, G. E. 1999. Heavily pigmented melanocytic neoplasms: comparison of two melanin-bleaching techniques and subsequent immunohistochemical staining. *British Journal of Biomedical Science* 56: 188–93.
- PATNAIK, A. K., AND S. MOONEY. 1988. Feline melanoma: a comparative study of ocular, oral, and dermal neoplasms. *Veterinary Pathology* 25: 105–112.
- PULLERY, L. T., AND A. A. STANNARD. 1990. Tumor of the skin and soft tissues. *In* Tumors in domestic animals, 3rd Edition. J. E. Moulton (ed.), University of California Press, Berkeley, California, pp. 23–87.
- WILCOCK, B. P. 1993. Ocular Neoplasia. *In* Pathology of domestic animals, 4th Edition, Vol. 1, K. V. F. Jubb, P. C. Kennedy and N. Palmer (eds.), Academic Press, San Diego, California, pp. 512–521.

Received for publication 10 April 2000.