



Rhizopusmycosis in a Harbor Porpoise from the Baltic Sea

Authors: Wünschmann, Arno, Siebert, Ursula, and Weiss, Reinhard

Source: Journal of Wildlife Diseases, 35(3) : 569-573

Published By: Wildlife Disease Association

URL: <https://doi.org/10.7589/0090-3558-35.3.569>

BioOne Complete (complete.BioOne.org) is a full-text database of 200 subscribed and open-access titles in the biological, ecological, and environmental sciences published by nonprofit societies, associations, museums, institutions, and presses.

Your use of this PDF, the BioOne Complete website, and all posted and associated content indicates your acceptance of BioOne's Terms of Use, available at www.bioone.org/terms-of-use.

Usage of BioOne Complete content is strictly limited to personal, educational, and non - commercial use. Commercial inquiries or rights and permissions requests should be directed to the individual publisher as copyright holder.

BioOne sees sustainable scholarly publishing as an inherently collaborative enterprise connecting authors, nonprofit publishers, academic institutions, research libraries, and research funders in the common goal of maximizing access to critical research.

Rhizopusmycosis in a Harbor Porpoise from the Baltic Sea

Arno Wünschmann,¹ Ursula Siebert,^{2,4} and Reinhard Weiss³ ¹ Institut für Veterinär-Pathologie, Justus-Liebig-Universität, Gießen, Frankfurter Str. 96, 35392 Gießen, Germany; ² Forschungs- und Technologiezentrum (FTZ) Westküste, Christian-Albrechts-Universität, Kiel, Werftstr. 6, 25761 Büsum, Germany; ³ Institut für Hygiene und Infektionskrankheiten der Tiere, Justus-Liebig-Universität, Gießen, Frankfurter Str. 89-91, 35392 Gießen, Germany; and ⁴ Corresponding author (e-mail: usiebert@ftz-west.uni-kiel.de).

ABSTRACT: A case of systemic mycosis due to a *Rhizopus* sp. infection is described in a dead-stranded, 10-yr-old, male harbor porpoise (*Phocoena phocoena*) found on the beach of Neustadt, Schleswig-Holstein on the Baltic Sea (Germany). At necropsy, granulomatous mycotic lesions in brain, lung, kidneys, testis, and draining lymph nodes were found. In addition, a focal ulcerative gastritis of the first stomach, due to a nematode infection, was present and is suspected to be the portal of entry for the fungus.

Key words: Case report, harbor porpoise, *Phocoena phocoena*, *Rhizopus* sp., systemic mycosis

Cases of systemic mycosis, including those caused by members of the Class Zygomycotina, are rarely observed in free-ranging marine mammals. Mucorales sp. infection has been reported in the lung of a captured 2-yr-old, female harp seal (*Pagophilus groenlandicus*), originating from the Gulf of St. Lawrence (Canada; Kaplan et al., 1960), in the skeletal muscles of a 3 to 4-mo-old, male right whale (*Eubalaena australis*), found dead on the coast of South Africa (Best and McCully, 1979) and in several organs (lung, alimentary tract, heart and skeletal muscle) of an 18-yr-old, female killer whale (*Orcinus orca*) residing in an aquarium in Vancouver (Canada; Migaki and Jones, 1983). In the harp seal, the fungus was further identified as *Mucor pusillus*. The filamentous molds of the Zygomycotina include the genera *Rhizopus*, *Mucor*, *Absidia*, *Saksenaea* and *Mortierella*. They are inferior fungi of the Order Mucorales in the Class Zygomycotina of the Subdivision Eumycotina. Members of this class are opportunistic, ubiquitous, saprophytic, facultative pathogenic, and rarely cause systemic mycosis in mammals. A predisposing factor for the manifestation of the disease is often immunosuppression

(Gedek et al., 1993). The present paper describes a case of systemic mycosis due to a *Rhizopus* sp. in a harbor porpoise (*Phocoena phocoena*). The porpoise was stranded and necropsied as a part of research programs running between 1991–96 concerning the health of small cetaceans of the North Sea and Baltic Sea of Germany.

A 10-yr-old, male harbor porpoise, 138 cm long and weighing 36 kg was found dead at the coast at the German Baltic Sea and stored frozen at –20 C until necropsy. Tissue samples were fixed in 10% non-buffered formalin and paraffin-embedded. Sections cut at 3 µm were stained with hematoxylin and eosin (H&E) (Romeis, 1989). Additional sections were stained with silver-staining according to Grocott (Bancroft and Cook, 1994), the periodic acid schiff (PAS) stain (Romeis, 1989), and the Ziehl-Neelsen stain (Romeis, 1989). For microbiological examination, samples of lung, kidney, liver, spleen, intestine, testis, and pulmonary as well as renal lymph nodes were taken and plated on to Blood agar, containing 5% defibrinated sheep blood, and Gassner agar (E. Merck, Darmstadt, Germany). For cultivation of fungi, Kimmig agar (E. Merck) was used. The culture media were incubated at 37 C and 28 C, respectively. Evaluation for bacterial growth was performed following 24 and 48 hr of incubation while fungal growth was assessed at day 3 and 6 of incubation.

Nematodes were collected, fixed in 70% ethanol, and identified. Identification of species by R. Lick (Forschungs- und Technologiezentrum Westküste, Christian-Albrechts-Universität Kiel, Büsum, Germany) was verified using specimens of the re-

spective species deposited at Forschungs- und Technologiezentrum Westküste.

Samples of the blubber were analysed for the presence of chlorinated hydrocarbon contaminants. Contaminants (on a lipid weight basis) were extracted with n-hexane, cleaned-up with alumina and analyzed using High Pressure Liquid Chromatography (HPLC) and single or multidimensional Gas Chromatography-Electron Capture Detector (GC-ECD, ThermoQuest, Egelsbach, Germany; Bruhn, 1997). Teeth removed from the mandible were used for age determinations (Myrick et al., 1983).

The avidin-biotin-peroxidase complex method was used for immunohistological demonstration of a possible morbillivirus infection as previously described (Baumgärtner et al., 1995). A canine distemper virus nucleoprotein-specific polyclonal antiserum (rabbit number 162 kindly provided by C. Örvell, Karolinska, Sweden), known to crossreact with porpoise morbillivirus (W. Baumgärtner, Giessen, Germany, pers. comm.) served as the primary antibody.

At necropsy, the animal was emaciated as indicated by moderate reduction of blubber thickness and mild atrophy of muscles. The cranial part of the right pulmonary lobe and both kidneys contained multiple grayish, poorly delineated nodules up to 5 cm in diameter with a solid cut surface. In the right testis a solitary, well circumscribed, similar nodular lesion of 5 cm in diameter was detected. In the first gastric compartment two chronic ulcers due to infection with the nematode *Anisakis simplex* were found. The pulmonary and retropharyngeal lymph nodes, enlarged up to $4 \times 5 \times 5$ cm and the renal lymph nodes, markedly enlarged to $15 \times 3 \times 3$ cm, had the same color and consistency as the previously described nodules. Furthermore, a moderate number of lungworms (*Pseudalius inflexus* and *Torynurus convolutus*) was observed in the bronchi. The liver showed a chronic fibrosing pericholangitis due to infection with the trem-

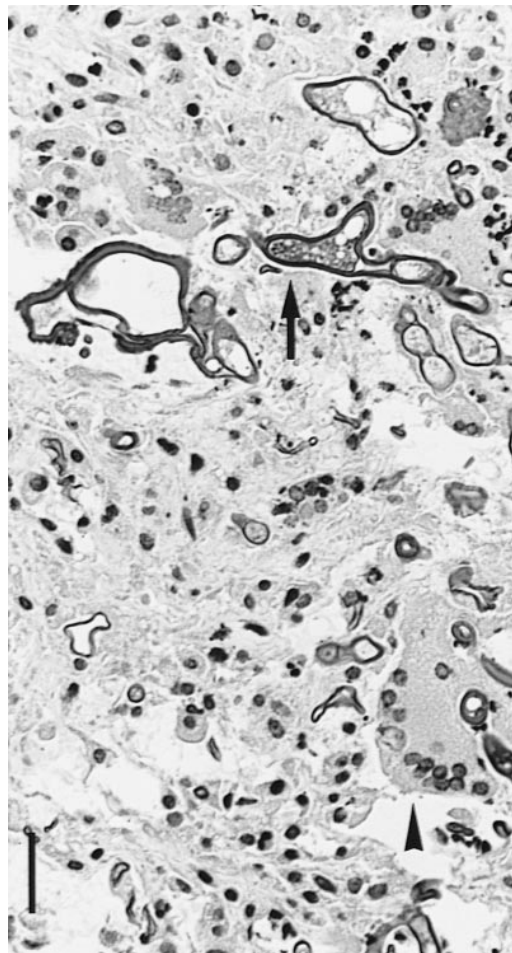


FIGURE 1. Renal lymph node with granulomatous necrotizing inflammation, multinucleated giant cells (arrowhead), and intra- and extracellular fungal hyphae (arrow) in a harbor porpoise from the Baltic Sea. H&E. Bar = 30 μ m.

atode *Campula oblonga*. A moderate number of *Stenurus minor* nematodes was detected in the cavities of both middle ears. The thymus contained multiple cysts up to 1 cm in diameter.

The nodular changes in lung, kidneys, testes, and lymph nodes were characterized by granulomatous necrotizing inflammation with multinucleated giant cells and intra- and extracellular fungal hyphae and spores (Fig. 1). In addition, a marked necrotizing thrombarteriitis due to fungal invasion of the artery wall was evident in the altered organs (Fig. 2). The fungal hyphae

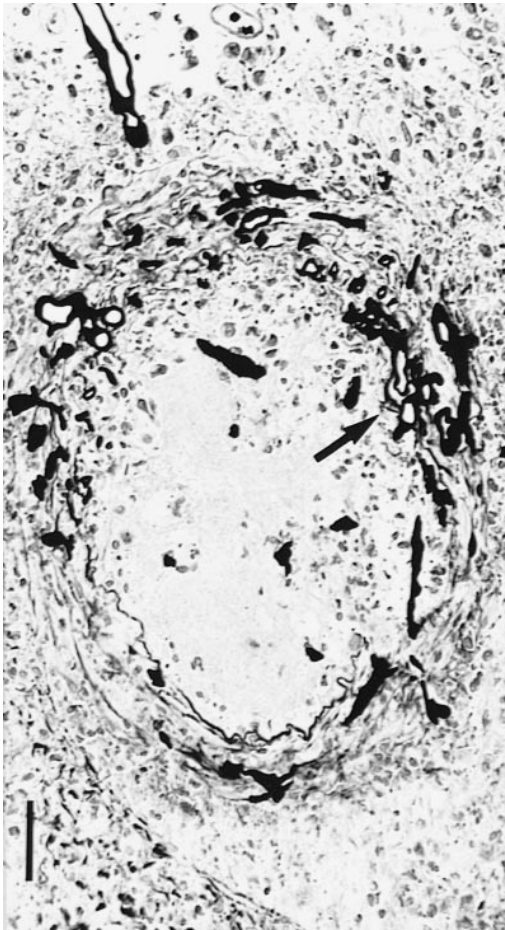


FIGURE 2. Necrotizing thrombarteriitis due to fungal invasion (arrow) of the artery wall in the kidney of a harbor porpoise from the Baltic Sea. Grocott stain. Bar = 50 μ m.

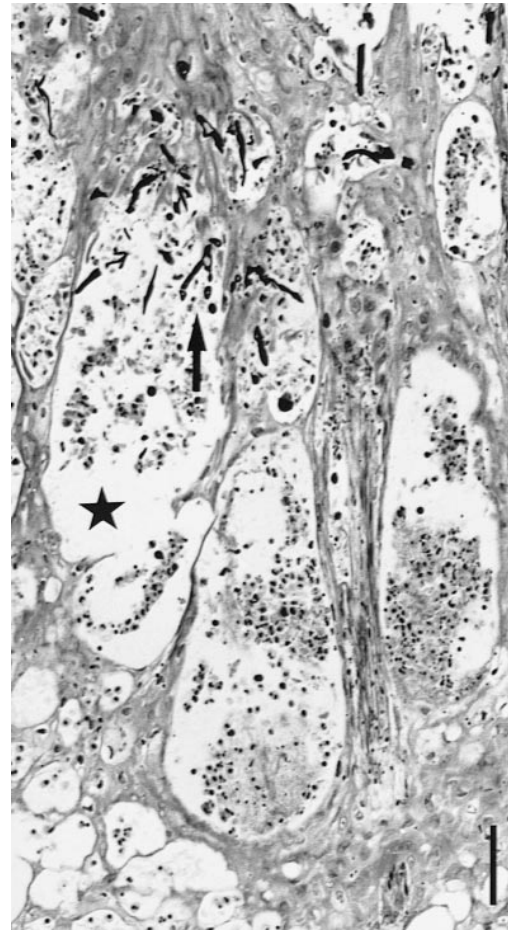


FIGURE 3. Hyperplastic epithelium of the first gastric compartment adjacent to an ulcer with intra-epithelial pustule-formation (star), and intralesional fungi (arrow) of a harbor porpoise from the Baltic Sea. H&E. Bar = 120 μ m.

were up to 40 μ m in diameter, rarely septated, irregularly branched, and had a thick wall. They could be clearly demonstrated in H&E-, Grocott- and PAS-stained sections. Below the ulcerated surface of the first gastric compartment, a granulomatous sclerosing inflammation with calcified remnants of nematodes was found. The mucosa, adjacent to the ulcers exhibited epithelial hyperplasia. Ballooning degeneration of epithelial cells and pustule-formation with intralesional fungi were detected (Fig. 3). Granulomatous meningitis with focal invasion of the brain parenchyma and perineuritis of brain

nerves was present. Ziehl-Neelsen staining was negative for acid-fast bacteria in all examined tissue sections. Morbillivirus antigen was not found by immunohistological examination of lung, kidney, brain and stomach.

Mycologically, a fast growing white fungus, which became grayish-brown with age, was isolated from kidney, lung, intestine, and testis. The columellae were brown and globoid. On the opposite side to the rising sporangiophores, rhizoids were present. Accordingly, the fungus was identified as *Rhizopus* sp. On bacteriological examination *Escherichia coli*, *Citro-*

bacter freundii, α - and γ -streptococci, *Pseudomonas* sp. *Enterobacter* sp. and *Aeromonas* sp. were found in lung, kidney, liver, spleen, intestine, testis, and pulmonary as well as renal lymph nodes and interpreted as incidental contamination. Analytic determination of chlorinated contaminants in blubber specimen yielded 59.34 μg chlorinated biphenyl's (ΣCB of 40 congeners), 0.2 μg hexachlorbenzole and 24.9 μg p,p4-DDE per g lipid.

Systemic mycosis is rare, particularly in wild-living marine mammals. In our examination of 444 harbor porpoises investigated from 1991–96 as part of different national programs, this was the only case exhibiting mycotic lesions. Pneumonia due to fungal infection was reported in two cases among 234 harbor porpoises stranded around the coasts of England and Wales (UK) between 1990 and 1995 (Kirkwood et al., 1997).

In the cases mentioned in the introduction, lung and skin were obviously the portal of entry for the fungus. The presence of fungi in the epithelium of the first gastric compartment of the harbor porpoise examined here is suggestive of a primary alimentary infection. The ulcerations of the first compartment of the stomach might have facilitated the invasion of the fungus.

The Mucorales have a strong affinity for artery walls. As demonstrated, they often enter the artery walls and may metastasize with thrombotic material (Gedek et al., 1993).

Mucorales infections often are associated with a host immunosuppression (Gedek et al., 1993). However, morbillivirus infection, known to occur in harbor porpoises of the North Sea (Kennedy et al., 1988; Barrett et al., 1995) and proven to cause immunodeficiency in dogs (Blixenkrone-Möller, 1993) was not detected. In association with morbillivirus infection, pulmonary aspergillosis was diagnosed in several cetacean species (Domingo et al., 1992; Kennedy et al., 1992; Lipscomb et al., 1994).

The negative impact of organochlorines on the immune system of seals and bottlenose dolphins has been described (De Swart et al., 1996; Lahvis et al., 1995) and the level of chlorinated hydrocarbon contaminants determined in this animal was tenfold higher compared to an age-matched, male harbor porpoise living in the waters around Greenland (data not shown). There are only few data available on organochlorine contaminants in male animals of the Baltic Sea. However, they were in the same range (reviewed by Bruhn, 1997). It needs to be clarified whether amounts of organochlorines as high as such in the presented case may have a negative influence on the immune system of harbor porpoises.

We wish to thank A. Artelt for excellent technical assistance, R. Bruhn for analytic determination of chlorinated hydrocarbon contaminants, R. Lick for the parasitological investigations and L. Chavez-Lisambart for age determination. The study was supported by grants of the Bundesministerium für Umwelt, Naturschutz und Reaktorsicherheit and the Bundesministerium für Bildung, Wissenschaft, Forschung und Technologie, Germany.

LITERATURE CITED

- BANCROFT, J. D., AND H. C. COOK. 1994. Manual of histological techniques and their diagnostic application. Churchill, Livingstone, Edinburgh, UK, 457 pp.
- BARRETT, T., M. BLIXENKRONE-MÖLLER, G. DIGUARDO, M. DOMINGO, P. DUIGNAN, A. HALL, L. MAMAEV, AND A. D. M. E. OSTERHAUS. 1995. Morbilliviruses in aquatic mammals: Report on round table discussion. *Veterinary Microbiology* 44: 261–266.
- BAUMGÄRTNER, W., R. W. BOYCE, S. W. WEISBRODE, S. ALLDINGER, M. K. AXTHELM, AND S. KRAKOWKA. 1995. Histologic and immunocytochemical characterisation of canine distemper-associated metaphyseal bone lesions in young dogs following experimental infection. *Veterinary Pathology* 32: 702–709.
- BEST, P. B., AND R. M. MCCULLY. 1979. Zygomycosis (Phycomycosis) in a right whale (*Eubalaena australis*). *Journal of Comparative Pathology* 89: 341–348.
- BLIXENKRONE-MÖLLER, M. 1993. Biological properties of phocine distemper virus and canine dis-

- temper virus. *Acta Pathologica, Microbiologica et Immunologica Scandinavica*, 101: 5–51.
- BRUHN, R. 1997. Chlorierte Schadstoffe in Schweinswalen (*Phocoena phocoena*): Verteilung, Akkumulation und Metabolisierung in Abhängigkeit von der Struktur. Berichte aus dem Institut für Meereskunde, No 291, Kiel, Germany, 117 pp.
- DE SWART, R. L., P. S. ROSS, J. G. VOS, AND A. D. M. E. OSTERHAUS. 1996. Impaired Immunity in harbour seals (*Phoca vitulina*) exposed to bioaccumulated environmental contaminants: review of a long term feeding study. *Environmental Health Perspectives* 10: 823–828.
- DOMINGO, M., J. VISA, M. PUMAROLA, A. J. MARCO, L. FERRER, R. RABANAL, AND S. KENNEDY. 1992. Pathological and immunocytochemical studies of morbillivirus infection in striped dolphins (*Stenella coeruleoalba*). *Veterinary Pathology* 29: 1–10.
- GEDEK, B., O. R. KAADEN, H. MAHNEL, AND A. MAYR. 1993. Niedere Pilze. In *Medizinische Mikrobiologie, Infektions- und Seuchenlehre*, 6th Edition, A. Mayr, (ed.). Enke Verlag, Stuttgart, Germany, pp. 811–814.
- KAPLAN, W., L. J. GOSS, L. AJELLO, AND M. S. IVENS. 1960. Pulmonary mucormycosis in a harp seal caused by *Mucor pusillus*. *Mycopathology and Mycology Applications* 12: 101–110.
- KENNEDY, S., J. A. SMYTH, P. F. CUSH, S. J. McCULLOUGH, G. M. ALLAN, AND S. MCQUAID. 1988. Viral distemper now found in porpoises. *Nature* 336: 21.
- , T. KUIKEN, H. M. ROSS, M. MCALISKEY, D. MOFFETT, C. M. MCNIVEN, AND M. CAROLE. 1992. Morbillivirus infection in two common porpoises (*Phocoena phocoena*) from the coasts of England and Scotland. *Veterinary Record* 131: 286–290.
- KIRKWOOD, J. K., P. M. BENNETT, P. D. JEPSON, T. KUIKEN, V. R. SIMPSON, AND J. R. BAKER. 1997. Entanglement in fishing gear and other causes of death in cetaceans stranded on the coasts of England and Wales. *Veterinary Record* 141: 94–98.
- LAHVIS, G. P., R. S. WELLS, D. W. KUEHL, J. L. STEWART, H. L. RHINEHART, AND C. S. VIA. 1995. Decreased lymphocyte responses in free-ranging bottlenose dolphins (*Tursiops truncatus*) are associated with increased concentrations of PCBs and DDT in peripheral blood. *Environmental Health Perspectives* 103: 67–72.
- LIPSCOMB, T. P., S. KENNEDY, D. MOFFETT, AND B. K. FORD. 1994. Morbilliviral disease in an Atlantic Bottlenose Dolphin (*Tursiops truncatus*) from the Gulf of Mexico. *Journal of Wildlife Diseases* 30: 572–576.
- MIGAKI, G., AND S. R. JONES. 1983. Mycotic diseases in marine mammals. In *Pathobiology of marine mammal diseases*, Vol. 2, E. B. Howard (ed.). CRC press, Inc, Boca Raton, Florida, pp. 1–27.
- MYRICK, J. A., A. HOHN, P. SLOAN, M. KIMURA, AND D. STANLEY. 1983. Estimating age of spotted and spinner dolphins (*Stenella attenuata* and *Stenella longirostris*) from teeth. Technical Memorandum, National Oceanic and Atmospheric Administration, National Marine Fisheries Service, Washington, D. C., 17 pp.
- ROMEIS, B. 1989. *Mikroskop Technik*. Urban und Schwarzenberg Verlag, München, Germany, 697 pp.

Received for publication 28 April 1998.