

RETICULOENDOTHELIOSIS IN CAPTIVE GREATER AND ATTWATER'S PRAIRIE CHICKENS

Authors: Drew, Mark L., Wigle, William L., Graham, David L., Griffin, Clifton P., Silvy, Nova J., et al.

Source: Journal of Wildlife Diseases, 34(4) : 783-791

Published By: Wildlife Disease Association

URL: <https://doi.org/10.7589/0090-3558-34.4.783>

BioOne Complete (complete.BioOne.org) is a full-text database of 200 subscribed and open-access titles in the biological, ecological, and environmental sciences published by nonprofit societies, associations, museums, institutions, and presses.

Your use of this PDF, the BioOne Complete website, and all posted and associated content indicates your acceptance of BioOne's Terms of Use, available at www.bioone.org/terms-of-use.

Usage of BioOne Complete content is strictly limited to personal, educational, and non - commercial use. Commercial inquiries or rights and permissions requests should be directed to the individual publisher as copyright holder.

BioOne sees sustainable scholarly publishing as an inherently collaborative enterprise connecting authors, nonprofit publishers, academic institutions, research libraries, and research funders in the common goal of maximizing access to critical research.

RETICULOENDOTHELIOSIS IN CAPTIVE GREATER AND ATTWATER'S PRAIRIE CHICKENS

Mark L. Drew,¹ William L. Wigle,² David L. Graham,³ Clifton P. Griffin,⁴ Nova J. Silvy,⁴ Aly M. Fadly,⁵ and Richard L. Witter⁵

¹ Department of Large Animal Medicine and Surgery, College of Veterinary Medicine, Texas A&M University, College Station, Texas 77843, USA

² Texas Veterinary Medical Diagnostic Laboratory, P. O. Drawer 3040, College Station, Texas 77843, USA

³ Department of Veterinary Pathobiology, College of Veterinary Medicine, Texas A&M University, College Station, Texas 77843, USA

⁴ Department of Wildlife and Fisheries Science, College of Agriculture and Life Sciences, Texas A&M University, College Station, Texas 77843, USA

⁵ Avian Disease and Oncology Laboratory, Agricultural Research Service, United States Department of Agriculture, 3606 E. Mount Hope Road, East Lansing, Michigan 48823, USA

ABSTRACT: Reticuloendotheliosis in captive greater (*Tympanuchus cupido pinnatus*) and Attwater's (*T. cupido attwateri*) prairie chickens is reported for the first time. Between September 1993 and August 1994, two adult female wild-caught greater prairie chickens housed at Texas A&M University (College Station, Texas, USA) were observed with multiple subcutaneous nodules. Both birds were euthanatized. Complete necropsy examinations revealed lesions limited to the skin of each bird. Histopathologic examination of lesions revealed pleomorphic lymphoreticular cells suggestive of reticuloendotheliosis and reticuloendotheliosis virus (REV) was demonstrated in tumor tissue by polymerase chain reaction and virus isolation. Between September 1994 and June 1995, five additional greater prairie chickens and two Attwater's prairie chickens were euthanatized or found dead with evidence of lymphoreticular neoplasia in multiple organ systems. Initial testing of the captive flock in December 1994 for evidence of viremia and antibody to reticuloendotheliosis virus revealed over 50% of the tested birds were viremic, but none developed antibodies. Subsequent testing between January 1995 and January 1996 indicated that once infected with reticuloendotheliosis virus, Attwater's prairie chickens tended to remain outwardly healthy despite persistent viremia compared to infected greater prairie chickens which had higher morbidity and mortality rates within 60 to 90 days after initial detection of viremia and did not usually develop persistent viremia. Antibodies to REV were detected in only three captive greater prairie chickens and only in 1995. Six of the nine birds that were euthanatized or found dead due to reticuloendotheliosis developed viremia prior to death; three birds were not tested prior to death. Testing of free-ranging greater and Attwater's prairie chickens for reticuloendotheliosis is recommended prior to translocation or release.

Key words: Attwater's prairie chicken, captivity, greater prairie chicken, reticuloendotheliosis, reticuloendotheliosis virus, *Tympanuchus cupido attwateri*, *Tympanuchus cupido pinnatus*.

INTRODUCTION

Prairie chickens (*Tympanuchus cupido*) were once widely distributed throughout the United States (Aldrich, 1963; Johnsgard, 1983). However, characteristics that make grasslands prime habitat for prairie chickens also make them prime habitat for human exploitation. Throughout this century, much of the native prairie has been converted to agricultural and urban use. As a result, the remaining prairie covers only a small fraction of its original expanse and has become severely fragmented. Concomitant with this loss has been degradation of the remaining prairie due to overgrazing and brush invasion. This has

lead to the dramatic reduction in the numbers and distribution of prairie grouse (Aldrich, 1963; Johnsgard and Wood, 1968; Johnsgard, 1983).

Of the three subspecies of prairie chickens, in North America the greater prairie chicken (*T. cupido pinnatus*) (GPC) has the largest extant population (Johnsgard, 1983). Although some populations have been reduced or even eliminated, this subspecies continues to thrive in many of the central plains states, where population estimates are still in the hundreds of thousands.

The heath hen (*T. cupido cupido*) originally inhabited the scrub oak plains of the

Atlantic coast of the USA from Maine to Virginia, and possibly the Carolinas (Gross, 1963). However, as colonization of the east coast progressed, populations of the heath hen rapidly disappeared. Although conservation measures were enacted at the turn of the 20th century, the subspecies was extirpated by 1932 (Gross, 1963).

The plight of the Attwater's prairie chicken (*T. cupido attwateri*) is similar to that of the heath hen. An estimated one million Attwater's prairie chickens (APC) once inhabited 2.4 million ha of tall grass prairie habitat on the coastal areas of Texas and Louisiana (USA) (Lehman, 1941). By 1967, only 1,070 birds occupied 12 counties in Texas and in 1967 the subspecies was placed on the Federal Endangered Species List (Lawrence and Silvy, 1980). To date, human induced habitat loss and fragmentation have further reduced this subspecies to three small, isolated populations totaling <70 birds (U.S. Fish and Wildlife Service, unpubl. data).

Due to small population sizes, the APC maintains an increased risk of excessive inbreeding and loss of genetic variability due to random genetic drift. Such events can lead to inbreeding depression and a reduced ability to respond to changing environmental conditions, thus promoting the extinction process or, at the very least, inhibiting recovery efforts (Gilpin and Soule, 1986). An effective management and conservation plan for this subspecies, therefore, requires an adequate understanding of their population genetic structure, limiting factors, and an assessment of the feasibility of captive propagation.

Reticuloendotheliosis (RE) is a neoplastic disease of gallinaceous birds caused by a retrovirus, reticuloendotheliosis virus (REV) (Witter, 1991). In poultry, RE causes an acute disease in young birds and chronic neoplasia in adult birds (Witter, 1991). Transmission occurs by horizontal, vertical and, possibly hematophagous insect vectors (Jordan, 1990; Witter, 1991). Natural hosts for REV include domestic chickens, turkeys, ducks, geese, and Japa-

nese quail; pheasants and guinea fowl have been experimentally infected (Dren et al. 1983; Witter, 1991). Other than two wild turkeys (*Meleagris gallopavo*) (Ley et al., 1989; Hayes et al., 1992), RE has not been reported in free-ranging gallinaceous birds in the United States. The purpose of this paper is to document the first known occurrence of RE in captive prairie chickens.

MATERIALS AND METHODS

A breeding flock of GPC was started at Texas A&M University in April 1992 to establish captive rearing techniques that could be applied to APC. Twenty adult birds were captured on booming grounds in Kansas (USA), and three juvenile birds were acquired from a captive flock in Minnesota (USA). The birds were housed in large outdoor pens and breeding activity, egg laying and chick production began in spring of 1993.

In 1994, 23 eggs were taken from nests of two wild APC hens and placed in an incubator at Texas A&M University. Twenty-two eggs hatched and these birds were retained to initiate the APC captive breeding program at Texas A&M University.

At the Texas A&M University facility, adult birds were housed separately by subspecies, in groups in large outdoor pens covered with nylon mesh and chicken wire. During the breeding season, adult birds were kept in pairs, trios or small groups in individual pens by subspecies. Eggs were collected at regular intervals and incubated at 37.5 C and 65 to 70% relative humidity. Chicks were removed from the incubator after internal pipping and placed into a brooder for 24 to 48 hr. Groups of chicks were kept in small pens which gradually increased in size in relation to growth rate, physical size and age. Chicks were moved outdoors near the time of fledging and kept in various sized groups until the next breeding season.

Adult birds were fed either a custom prepared game bird diet (Producers Cooperative, Bryan, Texas, USA) or a commercial pheasant ration (Mazuri Pheasant Breeder, PMI Feeds, St. Louis, Missouri, USA) ad libitum and chicks were fed commercial pheasant starter (Mazuri Pheasant Starter, or Grower and Developer, PMI Feeds, St. Louis, Missouri, USA) beginning at 3 to 4 days of age. The grasses and forbs within each pen was utilized by adult birds. Chicks were offered live field-caught insects and commercially reared crickets and mealworms (Rainbow Mealworms, Compton, California, USA) starting at 1 day of age. Fresh water was provided daily in large shallow bowls.

Complete necropsies were done on prairie chickens that were found dead and in suitable condition or euthanatized during this study. Selected tissues and lesions were submitted for bacterial culture or placed in 10% buffered formalin. Formalin fixed tissues were sectioned and stained with hematoxylin and eosin for histopathological examination.

Infection with REV was confirmed by virus isolation from tumor tissue, previously frozen at -70°C . Tissue samples were inoculated on chicken embryo fibroblasts (Regional Poultry Research Laboratory line 0; Crittenden et al. 1987); 7 to 9 days later cell lysates were assayed for avian leukosis virus and REV by enzyme-linked immunosorbent assay (ELISA) following methods of Cui et al. (1986, 1988). Reticuloendotheliosis virus DNA was detected in tissue using the polymerase chain reaction (PCR) reagents and methods of Aly et al. (1993).

Screening of captive birds at Texas A&M University for evidence of infection with, or antibodies to, REV was done at regular intervals beginning in December 1994. Blood samples were collected by jugular venipuncture, placed in heparinized tubes (Capiject; Terumo Medical Corporation, Elkton, Maryland, USA) and refrigerated until testing was done 48 to 72 hr later. Plasma samples were tested for REV by PCR and virus isolation as described previously for tumor tissue, and for antibodies to REV by virus neutralization tests as described by Witter (1989). Blood samples were collected in February 1995 from 35 APC and 75 GPC in captivity at Fossil Rim Wildlife Center (Glenrose, Texas, USA), Houston Zoological Gardens (Houston, Texas, USA) and the Dakota Zoo (Bismark, South Dakota, USA). Plasma samples from these birds were tested for REV by PCR and virus isolation and antibodies to REV by virus neutralization as described above.

To determine the source of REV for the captive flock at Texas A&M University, six free-ranging wild turkeys, 14 captive Japanese quail and a bantam chicken hen that had direct or indirect contact with the prairie chickens were bled and tested as described above. Serum collected at the time of capture from seven of the 20 wild-caught GPC was tested for evidence of antibodies to REV by virus neutralization.

Frozen serum and plasma from 25 APC and 45 bobwhite quail (*Colinus virginianus*) collected between 1987 to 1993 from the APC National Wildlife Refuge (Eagle Lake, Texas, USA) were tested by virus isolation and virus neutralization to determine the prevalence of infection and antibodies in wild birds. In March 1995, two wild adult male APC captured on the refuge were bled and tested as described above.



FIGURE 1. Multiple firm to fluctuant lesions due to reticuloendotheliosis on the head of a female wild-caught greater prairie chicken (*Tympanuchus cupido pinnatus*).

RESULTS

The index case of RE occurred in September 1993. A wild-caught adult female GPC developed firm subcutaneous facial lesions, approximately 1 cm diameter, involving the upper lids and adjacent skin of both eyes. The provisional clinical diagnosis was avian poxvirus infection. Histopathologic examination of a formalin-fixed biopsy of the eyelid revealed lymphoreticular aggregates with dense infiltration of the dermis by a pleomorphic population of lymphoreticular cells. No evidence of poxvirus infection was found.

Over the next 6 mo, this bird and a second wild-caught adult female GPC developed multiple firm to fluctuant lesions, 1 to 3 cm diameter, on the face, legs, and feet (Fig. 1, 2). The lesions in both birds gradually increased in size, occasionally became ulcerated and eventually interfered with vision and prehension. The two birds were euthanatized on 26 August 1994 and submitted for complete necropsy. Gross necropsy revealed lesions limited to the skin in each bird. Histopathologic examination of the lesions from both birds were similar and consisted of lymphocytic-histiocytic proliferative and infiltrative lesions of the skin and subcutis. Pronounced tumor cell pleomorphism with gradation from small, round lymphoid cells through

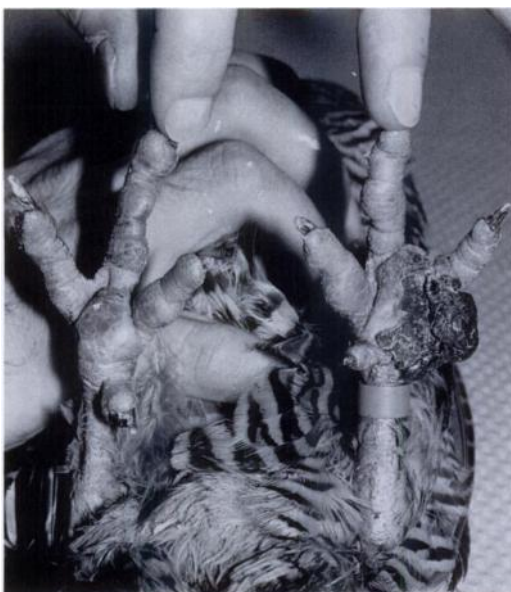

FIGURE 2. Multiple firm to fluctuant lesions of reticuloendotheliosis on the legs and feet of a female wild-caught greater prairie chicken (*Tympanuchus cupido pinnatus*).

plump, cytoplasm-replete, histocyte-like cells (Fig. 3) to elongated, slightly fusiform cells (Fig. 4) was suggestive of lesions of RE infection observed in other species (Li et al., 1983; Witter, 1991). Reticuloendotheliosis virus was isolated and viral antigen was identified by PCR and ELISA in tumors from both birds. Neither of these two birds was tested for REV before euthanasia.

Between September 1994 and June 1995, seven additional birds (two APC and five GPC) died or were euthanatized with lesions suggestive of RE (Table 1). All except one bird were <14-mo-old at the time of death. In these birds, the neoplastic lesions were multifocal, but were more common in the liver and spleen. Histopathologic examination of the neoplastic tissue revealed lymphoreticular proliferation in multiple sites and organs that was compatible with RE. Six of these seven birds were tested and were positive by virus isolation during flock testing 2 to 16 wk prior to death; the remaining bird was not tested prior to death (Table 1).

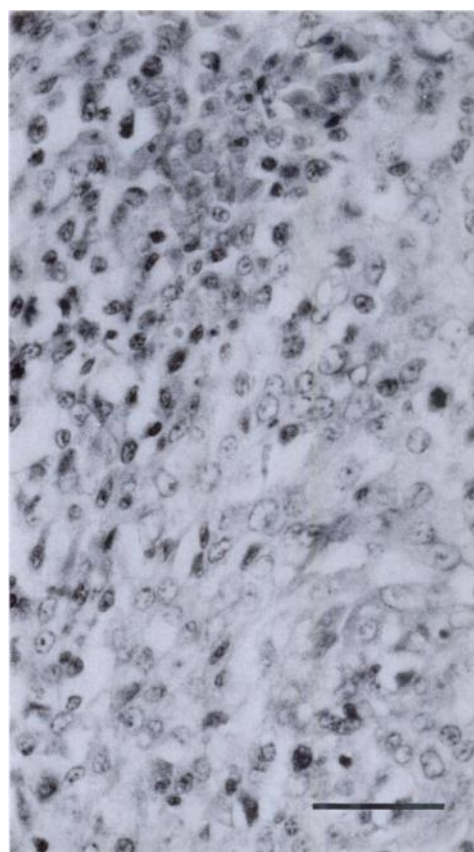


FIGURE 3. Pleomorphic cell types from a lesion of reticuloendotheliosis on a greater prairie chicken (*Tympanuchus cupido pinnatus*) ranging from small, round, lymphoid cells (upper left) to plump cells of a general histiocytic type (lower right) to elongated fusiform cells. Bar = 25 μ m.

Although not all birds in the flock at Texas A&M University were sampled each time, several trends in virus isolation and detection of antibody were identified (Table 2, 3). Once infected with REV, as determined by a positive PCR test, most birds became viremic, based on virus isolation, within 60 days. The clinical signs and course of the disease appeared to vary between APC and GPC. Once infected with REV, APC appeared outwardly healthy despite persistent viremia. Infected GPC had higher morbidity and mortality rates within 60 to 90 days after initial detection of viremia and did not usually develop persistent viremia. Antibodies

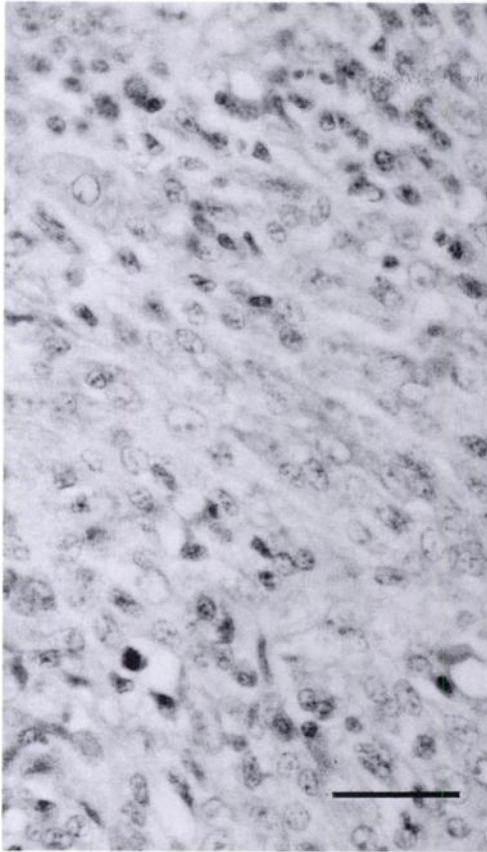


FIGURE 4. Pleomorphic, elongated, fusiform cell types from a lesion of reticuloendotheliosis on a greater prairie chicken (*Tympanuchus cupido pinna-tus*). Bar = 25 μ m.

were detected in only three GPC from the captive flock; all three birds hatched in 1994 and were positive in 1995 (Table 2, 3).

Serological testing and virus isolation from captive and wild birds in other locations were generally negative. None of the APC or GPC from any of the captive breeding facilities other than Texas A&M University were infected with or had antibodies to REV. However, the source of the REV for the captive flock at Texas A&M University was not determined. Ten of 14 quail and the bantam chicken hen were positive for REV antibodies, but virus was not isolated from these birds. Evidence of prior infection with, or exposure to, REV was not found in the seven sam-

ples from the original 20 wild-caught or captive-bred GPC.

Testing of frozen serum and plasma from APC and bobwhite quail from the APC National Wildlife Refuge yielded no evidence of REV infection or antibody. One of the two wild APC trapped in March 1995 was positive for antibody to REV, but no evidence of viremia or clinical disease was found.

DISCUSSION

The diagnosis of REV in APC and GPC represents the first report of this disease in grouse. Although the disease was found in captive birds, the possibility that wild populations of prairie grouse are infected with REV is of concern, since REV was associated with morbidity and mortality in at least nine captive birds between 1994 and 1995.

Due to the nature of the lesions, persistent viremia and lack of antibodies, infection of prairie chickens with RE most closely resembles chronic lymphoid neoplasia associated with an immune-tolerant infection as reported in young chickens and turkeys (Jordan, 1990; Witter, 1991). After exposure, chickens and turkeys can develop a variety of immunological responses which may be dependent on the strain of REV and/or the presence of maternal antibody (Witter, 1991). Some birds overcome the infection and develop antibodies, although the role of antibodies in protection from subsequent infections is unknown. Adult poultry exposed to the virus tend to develop transient viremia followed by development of antibodies. Most young birds that become infected do not develop antibodies and die of acute neoplasia within a few weeks of age (Jordan, 1990). Chronic lymphoid neoplasia develops in birds that do not develop antibodies and become persistently infected with the virus. Age-related resistance to infection with REV also has been demonstrated (Witter, 1991). Horizontal infection occurs readily in recently hatched chicks and poults; many of these chicks develop per-

TABLE 1. Signalment and lesions in captive male (M) and female (F) greater (GPC) and Attwater's (APC) prairie chickens with reticuloendotheliosis at Texas A&M University (College Station, Texas, USA), 1994–95.

Death date	Source ^a	Subspecies	Age	Sex	Lesions	Virus isolation
8-26-94	wild	GPC	>3 yr	F	multiple skin nodules on face, feet	+ ^b
8-26-94	wild	GPC	>3 yr	F	multiple skin nodules on face, feet	+ ^b
9-24-94	captive	GPC	6 mo	M	single skin nodule on face; multiple nodules on lung, liver, spleen	+
2-26-95	captive	APC	10 mo	M	multiple nodules in pharynx, spleen, gastro-intestinal tract	ND ^c
5-10-95	captive	APC	13 mo	F	multiple nodules in esophagus, liver, gastro-intestinal tract	+
5-14-95	captive	GPC	11 mo	M	nodules in lung, liver	+
5-17-95	captive	GPC	11 mo	M	nodules in spleen	+
6-07-95	wild	GPC	>4 yr	F	nodules in spleen	+
6-07-95	captive	GPC	12 mo	F	nodules in liver	+

^a Wild = wild caught in Kansas (USA); captive = hatched at Texas A&M University facility.^b Virus isolated from tumor at necropsy.^c ND = test not done.

sistent viremia without antibody production and are probably immune-tolerant (Witter, 1991), similar to what is described for APC in this study.

Multiple routes of transmission of REV in domestic poultry have been documented. Direct contact with infective virus in feces, ocular and nasal secretions, and litter are the primary modes of transmission in domestic chickens and turkeys (Peterson and Levine, 1971; Paul et al., 1977; Bagust et al., 1981; Witter and Johnson, 1985). Vertical transmission has been documented in turkeys, chickens, and ducks,

particularly in infected immune-tolerant birds (McDougall et al., 1980; Bagust et al., 1981; Motha and Egerton, 1987; Witter, 1991) but the role of vertical transmission and the source of the virus is debated (Witter and Salter, 1989). The role of hematophagous insects in the transmission of REV is unclear (Motha et al., 1983; Witter, 1991).

Avian pox vaccines contaminated with REV have been shown to induce RE lymphoma in broiler breeder chickens (Fadly et al., 1996). None of the prairie chickens in the captive rearing facility, the quail at

TABLE 2. Results of three diagnostic tests for reticuloendotheliosis virus in captive Attwater's prairie chickens at Texas A&M University (College Station, Texas, USA).

Test	Age ^a	Dec 94	Feb 95	Mar 95	Jun 95	Jun 95	July 95	Sep 95	Oct 95	Nov 95
Polymerase chain reaction	Adult	7/14 ^b	—	—	—	1/2	—	7/9	7/9	2/2
	HY95	— ^c	—	—	0/18	0/3	—	—	0/16	3/16
Virus isolation	Adult	8/14	9/11	1/3	—	—	—	—	6/9	8/8
	HY95	—	—	—	—	—	—	—	0/16	0/16
Virus neutralization	Adult	0/14	0/11	0/3	—	—	—	—	—	—
	HY95	—	—	—	—	—	—	—	—	—

^a HY95 = hatched in 1995. Adult = hatched prior to 1995.^b Number positive birds/total number of birds tested.^c No data collected.

TABLE 3. Results of three diagnostic tests for reticuloendotheliosis virus in captive Greater prairie chickens at Texas A&M University (College Station, Texas, USA).

Test	Age ^a	Dec 94	Feb 95	Mar 95	Jun 95	Jun 95	July 95	Sep 95	Oct 95	Nov 95
Polymerase chain reaction	Adult	1/2 ^b	—	—	4/4	2/4	0/2	0/2	0/2	0/2
	HY94	0/1	—	—	0/1	5/10	2/5	2/5	0/3	0/3
	HY95	— ^c	—	—	—	—	0/25	0/1		0/1
Virus isolation	Adult	1/2	5/11	0/4	—	—	—	—	0/2	0/2
	HY94	0/1	1/13	2/12	—	—	—	—	0/3	0/3
	HY95	—	—	—	—	—	—	—	—	0/1
Virus neutralization	Adult	0/2	0/11	0/4	—	—	0/2	—	—	—
	HY94	0/1	2/13	0/12	—	—	1/5	—	—	—
	HY95	—	—	—	—	—	0/25	—	—	—

^a HY94 = hatched in 1994, HY95 = hatched in 1995, Adult = hatched prior to 1995.^b Number positive birds/total number of birds tested.^c No data collected.

the poultry farm or the bantam chicken hen that were in direct or indirect contact with the prairie chickens had been vaccinated against avian pox. Therefore, a contaminated vaccine was not the source of the REV here. However, during the winter months of 1994–1995, an outbreak of avian poxvirus occurred in the captive prairie chicken flock at Texas A&M and several birds developed cutaneous lesions on the face and feet. Several of these lesions were initially suspected to be due to RE; however, the poxvirus etiology was established by histopathology of lesions at biopsy or necropsy. Avian poxvirus could have originated from wild birds in the vicinity of the pens and been transmitted by hematophagous insects. The potential link between avian poxvirus and REV in captive prairie chickens is unclear and requires further study.

The source of the REV for the captive flock at Texas A&M University was not determined. Although 10 of 14 quail and the bantam chicken hen were positive for REV antibodies, virus was not isolated from these birds. The quail were housed at a poultry research facility located about 1 km from the prairie chicken facility. Although an individual involved in the daily care of the quail occasionally assisted with care of the prairie chickens, no direct link between the quail and the prairie chickens

could be established. Since no evidence of prior infection with, or exposure to, REV was found in the seven samples from the original 20 wild-caught or captive-bred GPC, the infection was probably acquired after the birds were in captivity at Texas A&M University. A survey of wild birds in the vicinity of the prairie chicken pens is needed to determine if REV is present and whether these species could act as a reservoir for transmission of REV to the prairie chickens. Since the prairie chicken pens at Texas A&M University are located within 100 m of a small stream, mosquitos may be the vectors between wild birds and captive prairie chickens. Further research to determine routes and methods of transmission to prairie chickens is needed. The effectiveness of a testing and culling program for maintaining a disease-free flock must be evaluated. Given the valuable genetic status of captive APC, methods to hatch and rear non-infected or immune chicks from persistently infected adults is needed.

In wild APC, the lack of evidence for exposure and infection with REV raises the question of the status and importance of RE in APC. We recommend that free-ranging populations of gallinaceous birds, including GPC and APC, should be tested for evidence of exposure to REV using the PCR test to define host range, prevalence

of infection, and potential for spread of the disease during capture and release programs. If the wild populations of GPC and APC are free of the disease, the possibility of introducing the disease, particularly from released captive-reared prairie chickens, to wild populations of prairie chickens is high and potentially devastating. We recommend that all captive GPC and APC that are to be released should be screened for REV at least once monthly for 3 mo prior to their release using the PCR test.

ACKNOWLEDGMENTS

The assistance and support of S. Labuda, M. Morrow, D. Drake, E. Osterndorf, and M. Peterson is gratefully acknowledged. We acknowledge the assistance of many other individuals in many disciplines that have contributed expertise to the captive rearing effort.

LITERATURE CITED

- ALY, M. M., E. J. SMITH, AND A. M. FADLY. 1993. Detection of reticuloendotheliosis virus infection using the polymerase chain reaction. *Avian Pathology* 22: 543–554.
- ALDRICH, J. W. 1963. Geographic orientation of American Tetraonidae. *The Journal of Wildlife Management* 27: 529–545.
- BAGUST, T. J., T. M. GRIMES, AND N. RATNAMOHAN. 1981. Experimental infection of chickens with an Australian strain of reticuloendotheliosis virus. 3. Persistent infection and transmission by the adult hen. *Avian Pathology* 10: 375–385.
- CRITTENDEN, L. B., S. MCMOHN, M. S. HALPERN, AND A. M. FADLY. 1987. Embryonic infection with the endogenous avian leukosis virus Rous-associated virus-0 alters responses to exogenous avian leukosis virus infection. *Journal of Virology* 61: 722–725.
- CUI, Z., L. F. LEE, R. F. SILVA, AND R. L. WITTER. 1986. Monoclonal antibodies against avian reticuloendotheliosis virus: Identification of strain-specific and strain-common epitopes. *The Journal of Immunology* 136: 4237–4242.
- , E. J. SMITH, R. L. WITTER, AND B. CHANG. 1988. Monoclonal-antibody-mediated enzyme-linked immunosorbant assay for detection of reticuloendotheliosis viruses. *Avian Diseases* 32: 32–40.
- DREN, C. N., E. SAGHY, R. GLAVITS, F. RATZ, J. PING, AND V. SZTOJKOV. 1983. Lymphoreticular tumor in pen-raised pheasants associated with a reticuloendotheliosis-like virus infection. *Avian Pathology* 12: 55–71.
- FADLY, A. M., R. L. WITTER, E. J. SMITH, R. F. SILVA, W. M. REED, F. J. HOERR, AND M. R. PUTMAN. 1996. An outbreak of lymphomas in commercial broiler breeder chickens vaccinated with a fowlpox vaccine contaminated with reticuloendotheliosis virus. *Avian Pathology* 25: 35–47.
- GILPIN, M. E., AND M. E. SOULE. 1986. Minimum viable populations: Processes of species extinction. In *Conservation biology: The science of scarcity and diversity*, M. E. Soule (ed.). Sinauer Press, Sunderland, Massachusetts, pp. 19–34.
- GROSS, A. O. 1963. *Tympanuchus cupido cupido* (Linnaeus). Heath hen. In *Life histories of North American gallinaceous birds*, A. C. Bent (ed.). Gloucester, Massachusetts, pp. 264–280.
- HAYES, L. E., K. A. LANGHEINRICH AND R. L. WITTER. 1992. Reticuloendotheliosis in a wild turkey (*Meleagris gallopavo*) from coastal Georgia. *Journal of Wildlife Diseases* 28: 154–158.
- JOHNSGARD, P. A. 1983. *The grouse of the world*. University of Nebraska Press, Lincoln, Nebraska, 413 pp.
- , AND R. E. WOOD. 1968. Distributional changes and interactions between prairie chickens and sharp-tailed grouse in the midwest. *Wilson Bulletin* 80: 173–188.
- JORDAN, F. T. W. 1990. Reticuloendotheliosis. In *Poultry diseases*, F. T. W. Jordan (ed.). Bailliere Tindall, London, England, pp. 118–120.
- LAWRENCE, J. S., AND N. J. SILVY. 1980. Status of the Attwater's prairie chicken—an update. In *Proceedings of the Prairie Grouse Symposium*, P. A. Vohs and F. L. Knopf, (eds.). Oklahoma State University, Stillwater, Oklahoma, pp. 29–33.
- LEHMANN, V. W. 1941. Attwater's prairie chicken: Its life history and management. *North American Fauna* #57. United States Department of Interior, Fish and Wildlife Service, Washington, D. C., 65 pp.
- LEY, D. H., M. D. FICKER, D. T. COBB, AND R. L. WITTER. 1989. Histomoniasis and reticuloendotheliosis in a wild turkey (*Meleagris gallopavo*) in North Carolina. *Journal of Wildlife Diseases* 25: 262–265.
- LI, J., B. W. CALNEK, K. A. SCHAT, AND D. L. GRAHAM. 1983. Pathogenesis of reticuloendotheliosis infection in ducks. *Avian Diseases* 27: 1090–1105.
- MCDougALL, J. S., R. W. SHILLETO, AND P. M. BIGGS. 1980. Experimental infection and vertical transmission of reticuloendotheliosis virus in the turkey. *Avian Pathology* 9: 445–454.
- MOTHA, M. X. J., J. R. EGERTON, AND W. SWEENEY. 1983. Some evidence of mechanical transmission of reticuloendotheliosis virus by mosquitos. *Avian Diseases* 28: 858–867.
- , AND J. R. EGERTON. 1987. Vertical transmission of reticuloendotheliosis virus in chickens. *Avian Pathology* 16: 141–147.
- PAUL, P. S., K. H. JOHNSON, K. A. POMEROY, B. S.

- POMEROY, AND P. S. SARMA. 1977. Experimental transmission of reticuloendotheliosis in turkeys with the cell-culture-propagated reticuloendotheliosis viruses of turkey origin. *Journal of the National Cancer Institute* 58: 1819–1824.
- PETERSON, D. A., AND A. S. LEVINE. 1971. Avian reticuloendotheliosis virus (strain T). IV. Infectivity in day-old cockerels. *Avian Diseases* 14: 874–883.
- WITTER, R. L. 1989. Reticuloendotheliosis. In *A laboratory manual for the isolation and identification of avian pathogens*, H. G. Purchase, L. H. Arp, C. H. Domermuth, and J. E. Pearson (eds.), American Association of Avian Pathologists, Kennett Square, Pennsylvania, pp. 143–148.
- . 1991. Reticuloendotheliosis. In *Diseases of poultry*, B. W. Calnek, H. J. Burns, C. W. Beard, W. M. Reid, and H. W. Yoder, Jr. (eds.), Iowa State University Press, Ames, Iowa, pp. 406–417.
- , AND D. C. JOHNSON. 1985. Epidemiology of reticuloendotheliosis virus in broiler breeder flocks. *Avian Diseases* 29: 1140–1154.
- , AND D. W. SALTER. 1989. Vertical transmission of reticuloendotheliosis virus in breeder turkeys. *Avian Diseases* 33: 226–235.

Received for publication 27 March 1997.