

## **EFFECTS OF EMBEDDED TUNGSTEN-BISMUTH-TIN SHOT AND STEEL SHOT ON MALLARDS (ANAS PLATYRHYNCHOS)**

Authors: Kraabel, Brita J., Miller, Michael W., Getzy, David M., and Ringelman, James K.

Source: Journal of Wildlife Diseases, 32(1) : 1-8

Published By: Wildlife Disease Association

URL: <https://doi.org/10.7589/0090-3558-32.1.1>

---

BioOne Complete ([complete.BioOne.org](https://complete.BioOne.org)) is a full-text database of 200 subscribed and open-access titles in the biological, ecological, and environmental sciences published by nonprofit societies, associations, museums, institutions, and presses.

Your use of this PDF, the BioOne Complete website, and all posted and associated content indicates your acceptance of BioOne's Terms of Use, available at [www.bioone.org/terms-of-use](https://www.bioone.org/terms-of-use).

Usage of BioOne Complete content is strictly limited to personal, educational, and non - commercial use. Commercial inquiries or rights and permissions requests should be directed to the individual publisher as copyright holder.

---

BioOne sees sustainable scholarly publishing as an inherently collaborative enterprise connecting authors, nonprofit publishers, academic institutions, research libraries, and research funders in the common goal of maximizing access to critical research.

## EFFECTS OF EMBEDDED TUNGSTEN-BISMUTH-TIN SHOT AND STEEL SHOT ON MALLARDS (*ANAS PLATYRHYNCHOS*)

Brita J. Kraabel,<sup>1</sup> Michael W. Miller,<sup>1</sup> David M. Getzy,<sup>2</sup> and James K. Ringelman<sup>1</sup>

<sup>1</sup> Colorado Division of Wildlife, Wildlife Research Center, 317 West Prospect Road, Fort Collins, Colorado 80526, USA.

<sup>2</sup> Colorado State University Diagnostic Laboratory, College of Veterinary Medicine and Biomedical Sciences, Colorado State University, Fort Collins, Colorado 80523, USA.

**ABSTRACT:** We assessed the potential for embedded steel and tungsten-bismuth-tin (TBT) shot to adversely affect health of mallards (*Anas platyrhynchos*). Ducks were implanted with three number four steel ( $n = 19$ ) or TBT ( $n = 20$ ) shot pellets in their pectoral muscles. None of seven hematology parameters measured differed in response to treatment ( $P \geq 0.17$ ). At necropsy 1, 2, 4, and 8 wk posttreatment, we observed only localized tissue reactions to embedded steel or TBT shot. Reactions differed grossly: after wk 1, embedded steel shot were enveloped in 0.5 to 2 mm grayish capsules, whereas TBT shot were surrounded by thinner ( $<0.5$  mm), translucent capsules. Corrosion of steel shot was apparent. Microscopic lesions associated with steel shot were characterized by moderate to severe histiocytic and lymphocytic inflammation and considerable particle deposition, whereas histiocytic inflammation was mild and particle deposition minimal in TBT lesions. Overall scores of inflammation at steel shot implant sites were greater ( $P \leq 0.043$ ) than at TBT sites during wk 1 and 8. Inflammation at steel implant sites was relatively consistent over the 8-wk period, but decreased ( $P = 0.0017$ ) at TBT sites by wk 8. Weights of steel shot recovered from muscle tissue declined logarithmically ( $R^2 = 0.978$ ,  $P = 0.0014$ ) over 8 wk, but TBT shot weights remained unchanged ( $P = 0.255$ ). Embedded TBT shot, as compared to steel, resisted corrosion and induced comparatively mild inflammatory responses in mallard muscle tissue. However, inflammatory reactions to both embedded steel and TBT shot were localized and had no detectable systemic effects on mallard health under experimental conditions.

**Key words:** mallard duck, *Anas platyrhynchos*, TBT, tungsten-bismuth-tin shot, steel shot, nontoxic shot, experimental study, hematology.

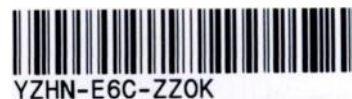### INTRODUCTION

The United States banned lead shot in 1991 for all waterfowl hunting because it is toxic when ingested by waterfowl and other wildlife (Bellrose, 1959; U.S. Fish and Wildlife Service, 1976). Since 1950, more than 30 alternative shot formulations have been tested (Haseltine and Sileo, 1983), but toxicity, ballistic qualities, manufacturing difficulties, or expense have precluded their further development. Presently, steel shot is the only nontoxic shot approved for waterfowl hunting in the United States. However, many hunters are dissatisfied with ballistic qualities of steel shot and believe that shooting steel increases crippling rates (Martin et al., 1991). These attitudes may have contributed to a continuing nationwide decline in waterfowl hunting (Martin et al., 1991), and have motivated a continued search for an alternative nontoxic shot.

A candidate nontoxic shot has been de-

veloped using tungsten (39.05% by weight), bismuth (44.49%), and tin (16.46%). Powdered tungsten, a high density metal, is mechanically suspended in molten tin and bismuth to yield a shot with the same density and hardness as lead (V. C. Oltrogge, Denver, Colorado, patents pending). Tungsten-bismuth-tin (TBT) shot ingested by mallards (*Anas platyrhynchos*) produced no evidence of acute toxicity (Ringelman et al., 1993). However, before a candidate nontoxic shot such as TBT can be approved for use in the United States, it also must undergo corrosion testing as well as chronic and reproductive toxicity testing (U.S. Fish and Wildlife Service, 1989).

Bartels et al. (1991) reported that steel shot embedded in muscles of dogs caused severe inflammatory responses. In contrast, lead caused little inflammation when implanted into muscle, and could be left in place with no adverse affect providing it did not gain access to the blood (Sclafani



et al., 1985). We tested the hypotheses that in vivo corrosion rates of steel and TBT shot, as well as inflammatory responses to embedded steel and TBT shot, would not differ. We also measured indices of overall health to determine whether embedded shot had systemic effects on mallards.

#### MATERIALS AND METHODS

Forty-two 5-wk-old game farm mallards were purchased (Game Birds Unlimited, Inc., Longmont, Colorado, USA) on 27 May 1992 and transported to the Colorado Division of Wildlife's Foothills Wildlife Research Facility (Fort Collins, Colorado; 40°35'N, 105°10'W). For 2 wk they were housed in two adjacent 3 × 4 m outdoor pens. The sex of all ducks was determined at 7 wk of age and they were then paired randomly by sex ( $n = 7$  female and 13 male pairs). We segregated pairs into 20 adjacent 3 × 4 m pens. Water for swimming and drinking was provided by a single flow-through source. Ducks were fed a nutritionally balanced pelletized commercial ration (20% Lay Pellets, RanchWay, Inc., Fort Collins, Colorado) ad libitum during acclimation (27 May to 16 July 1992) and trial period (17 July to 11 September 1992). The guaranteed analysis for this ration was: crude protein  $\geq 20.0\%$ , crude fat  $\geq 2.0\%$ , crude fiber  $\leq 10.5\%$ , calcium 3.0 to 3.5%, and phosphorus  $\geq 1.0\%$ . Grit from natural sources was available in each pen.

We randomly assigned one bird from each pair to be implanted with number four TBT shot and the other with number four steel shot. All shot were individually numbered, weighed, and sterilized with ethylene oxide prior to implantation. We used 25 mg ketamine (Ketaset, Fort Dodge Laboratories, Inc., Fort Dodge, Iowa, USA) and 5 mg xylazine (Rompun, Mobay Corporation, Animal Health Division, Shawnee, Kansas, USA), injected intravenously, to anesthetize the first 24 birds. Due to associated apnea, the remaining 16 ducks were anesthetized with intravenous ketamine (25 mg) alone. After weighing each bird, six implant sites were identified using an acetate template to guide placement of shot or sham stab wounds at cranial, mid, and caudal locations in the pectoral muscles. We prepared sites with betadine ointment, separated feathers, and made a small stab incision through the skin at each site. One TBT or steel shot was implanted into each site in the right pectoral muscle, and a stab wound without shot was made at each site in the left pectoral muscle. We used a commercial implant gun (Ralgrow, Cooper Pittman

Moore, Inc., Mundeline, Illinois, USA) to place shot and make sham stab wounds.

We randomly selected female and male pairs at 1, 2, 4, and 8 wk after implantation for post-mortem evaluations. Two female and three male pairs were examined at each period, except during wk 4 when one female and four male pairs were used. Twenty-four hours prior to euthanasia, we obtained blood samples, body weights, and radiographs; radiographs were used to aid in locating shot at necropsy. We collected 3 ml of blood via jugular venipuncture in ethylenediaminetetraacetic acid (EDTA) vacutainers (Becton-Dickinson and Company, Rutherford, New Jersey, USA) and performed complete white blood cell (WBC) counts and differentials using the eosinophil unopette system (Becton-Dickinson and Company, Rutherford, New Jersey). We measured packed cell volume (PCV), and total protein (mg/dl) (Gornall et al., 1949). We euthanized birds with CO<sub>2</sub> asphyxiation and performed complete necropsies. Implanted shot were recovered and labeled. Tissue surrounding each implant or control site was excised, labeled, placed in 10% neutral buffered formalin, and submitted for histological examination. Samples of control sites were randomly evaluated for histologic changes only during wk 1. Implant sites were dehydrated through a series of increasingly concentrated (70 to 100%) ethanol solutions and then cleared in xylene. They then were embedded in paraffin, sectioned at 4  $\mu$ m, and stained with hematoxylin and eosin.

Slides were evaluated without knowledge of treatment group. Sections of muscle were examined for presence, partial presence, or absence of the implant site. Individual components of inflammation and tissue damage were evaluated using a scoring system adapted from a study of metal implants in rabbit muscle (Laing et al., 1967). The inflammatory response was graded as to the presence and severity of heterophilia, histiocytosis, lymphoplasmacytosis, fibrous tissue proliferation, fibroplasia, hemorrhage, hemosiderosis, multinucleate cell infiltrate, and pseudomembrane formation. The skeletal muscle involvement was scored for the presence and severity of: degeneration, necrosis, atrophy, and fibroplasia. The scores given to each of the above categories was: 0 = none, 1 = minimal, 2 = mild or low number, 3 = moderate, 4 = marked or numerous.

During wk 1 and 2, we cleaned recovered steel and TBT shot in accordance with American Society for Testing and Materials (1990) procedures for steel implants. Each shot was ultrasonically cleaned in 20% glacial acetic acid, rinsed in methanol, dried and weighed. Shot from wk 1 required only 20 min of cleaning to remove adhered residue. Shot from wk 2 were

TABLE 1. Summary of packed cell volumes (PCV), total protein, and complete white blood counts by week and treatment for mallards implanted with either tungsten-bismuth-tin (TBT) or steel shot.

	Week 1		Week 2		Week 4		Week 8	
	TBT <sup>a</sup>	Steel <sup>a</sup>	TBT	Steel	TBT	Steel	TBT	Steel
PCV (%)	43.4 (1.07)	44.0 (1.15)	44.0 (1.30)	44.6 (1.83)	49.2 (1.01)	42.4 (2.60)	48.6 (1.33)	48.3 (1.44)
Protein (mg/dl)	5.04 (0.16)	4.70 (0.06)	5.36 (0.17)	5.26 (0.08)	5.40 (0.09)	5.14 (0.08)	5.40 (0.21)	5.50 (0.22)
White cell count <sup>b</sup>	8.22 (1.61)	10.20 (0.94)	10.10 (2.12)	8.68 (1.79)	8.94 (1.26)	7.58 (1.12)	12.18 (2.18)	20.43 (5.60)
Heterophils <sup>b</sup>	4.50 (0.71)	5.40 (0.44)	5.21 (1.01)	5.32 (1.29)	6.34 (1.19)	4.43 (0.63)	6.73 (1.77)	13.70 (4.40)
Lymphocytes <sup>b</sup>	2.93 (0.84)	4.00 (0.62)	4.08 (1.28)	2.82 (0.59)	1.98 (0.47)	2.61 (0.49)	4.43 (0.42)	3.95 (0.10)
Monocytes <sup>b</sup>	0.19 (0.05)	0.13 (0.04)	0.09 (0.04)	0.11 (0.07)	0.24 (0.11)	0.21 (0.07)	0.81 (0.50)	1.95 (1.23)
Basophils <sup>b</sup>	0.05 (0.04)	0 (0)	0.05 (0.04)	0.10 (0.03)	0.08 (0.04)	0.04 (0.02)	0.04 (0.03)	0.11 (0.06)
Eosinophils <sup>b</sup>	0.51 (0.02)	0.64 (0.02)	0.64 (0.13)	0.34 (0.07)	0.29 (0.14)	0.26 (0.04)	0.12 (0.07)	0.68 (0.28)

<sup>a</sup> Values represented are mean (standard error).<sup>b</sup> Values represented are  $\times 10^3$  cells/mm<sup>3</sup> of blood.

coated with more adherent residue, thereby requiring 8 hr of cleaning. Subsequently, we discovered that some TBT shot had partially dissolved during this extended cleaning. To quantitate these apparent losses, clean steel ( $n = 36$ ) and TBT shot ( $n = 36$ ) were placed in 20% acetic acid and ultrasonically cleaned as described. Six TBT and steel shot were removed after 0.5, 1, 2, 6, 8, and 24 hr. Based on our findings, we continued to clean the steel shot as described, but modified procedures for cleaning TBT shot. Recovered TBT shot from wk 4 and 8 were ultrasonically cleaned in Hepes (N-2[hydroxyethyl] piperazine-N'[2 ethane sulfonic acid]; Research Organics, Inc., Cleveland, Ohio, USA) buffered 1% Tween (polyoxyethylenesorbitan monolaurate; Sigma, St Louis, Missouri, USA) for 8 hr after determining that this method did not dissolve shot.

We compared hematology values, shot mass changes (%), and body mass using ANOVA or paired *t*-tests (SAS Institute, Inc., 1988). Treatment (steel versus TBT), week, and sex were used as main effects and combined as interaction terms in analyses of hematology and shot weight data. Weights of TBT shot from wk 2 were not included in our analysis. Histology scores were ranked and compared using Mann-Whitney and Kruskal-Wallis tests (SAS Institute, Inc., 1988).

## RESULTS

All but one mallard implanted with TBT or steel survived assigned treatment peri-

ods and appeared in good health throughout these periods; a steel-treated hen fractured her left femur on day 5 and was euthanized. All ducks gained body mass during our experiment ( $P = 0.002$ ), and body mass changes did not differ between treatment groups ( $P \geq 0.33$ ). Birds recovered quickly from anesthesia, and showed no signs of discomfort after implantation.

Total white cell and differential blood counts, packed cell volumes, and total proteins (Table 1) did not differ between treatment groups ( $P \geq 0.17$ ). However, total white blood cell count, monocytes, and total protein increased over the 8 wk period in both treatment groups ( $P \leq 0.037$ ).

Shot implant sites and sham stab wounds were relatively difficult to find at necropsy, although steel implant sites were usually palpable in muscles. Sham stab wounds consistently appeared as pale tan streaks through muscle at wk 1, but were indiscernible thereafter. We observed gross differences in local responses to implanted steel and TBT shot (Table 2). Steel implant sites examined at wk 1 were generally characterized by a 0.5 to 2 mm gray to green capsule. By wk 2, pitting and cor-

TABLE 2. Gross and histologic changes associated with implanted tungsten-bismuth-tin (TBT) and steel shot in mallards.

Inflammatory changes	TBT	Steel
Capsule	<1 mm, translucent	0.5 to 2 mm grey-green, with black green debris weeks 4, 8
Visible corrosion of shot	None visible	Pitting visible weeks 2, 4, 8
Lymphoplasmacytic cells	Occasional, surrounded implant sites weeks 1, 2, 4, 8; decreased with time	None seen
Histiocytes with granular brown material	Few seen weeks 1, 2, 4, 8	None week 1, moderate number seen weeks 2, 4, 8
Lymphocytes	Low number weeks 1, 2, 4, 8	Low number week 1, increased with time
Lymphoid aggregates	Low number weeks 1, 2, 4, 8	Moderate number week 1, increased with time
Heterophils	Low number week 1, none weeks 2, 4, 8	Low number weeks 1, 2, 4, 8
Multinucleated giant cells	None seen	Numerous week 1; moderate number weeks 2, 4, 8
Refractile extracellular basophilic material	None seen	Moderate to severe amount present increased with time, decreasing in particle size with time changing from basophilic to golden green material
Skeletal muscle fibroplasia and degeneration	Minimal to mild changes weeks 1, 2, 4, 8	Marked degeneration weeks 1, 2, moderate weeks 4, 8; mild fibroplasia weeks 1, 2, 4, 8
Severity of inflammation	Mild changes weeks 1, 2, minimal weeks 4, 8	Moderate to severe weeks 1, 8, mild to moderate weeks 2, 4

rosion of steel shot were evident. Steel shot implant sites examined at wk 4 and 8 contained black and green debris adhering to both shot and capsule. In contrast, TBT sites were not readily palpated and had thin translucent capsules <1 mm thick. Tungsten-bismuth-tin shot had no evidence of corrosion. After TBT shot were removed, implant sites were difficult to identify. Aside from these local responses, we observed no gross findings attributable to experimental treatments. Draining tracts were not observed with either shot type, and in all cases lesions were entirely localized to tissue immediately surrounding embedded shot.

Gross differences in local tissue responses to implanted shot were supported by histological findings (Table 2). Overall, there was markedly more inflammation and deposition of particulate matter with steel shot when compared with TBT shot. Inflammatory responses to steel were pre-

dominately histiocytic with multinucleated giant cells; lymphocytes and lymphoid aggregates increased over the 8-wk period (Fig. 1). Tungsten-bismuth-tin implant sites were characterized by a minimal number of histiocytes containing small quantities of granular brown material, surrounded by few lymphoplasmacytic cells (Fig. 1). Numbers of heterophils present in all lesions were minimal.

Comparing scores for observed inflammatory changes was used to further differentiate localized responses to implanted steel and TBT shot. Those sections  $\geq 2.5$  mm from implant sites had less inflammation ( $P = 0.003$ ) than those where implant sites were partially or entirely included. Consequently, only the latter categories were included in further comparisons. Inflammatory changes were greater at steel implant sites, when compared to TBT, at wk 1 and 8 ( $P \leq 0.04$ ) (Fig. 2A), and associated muscle damage was greater

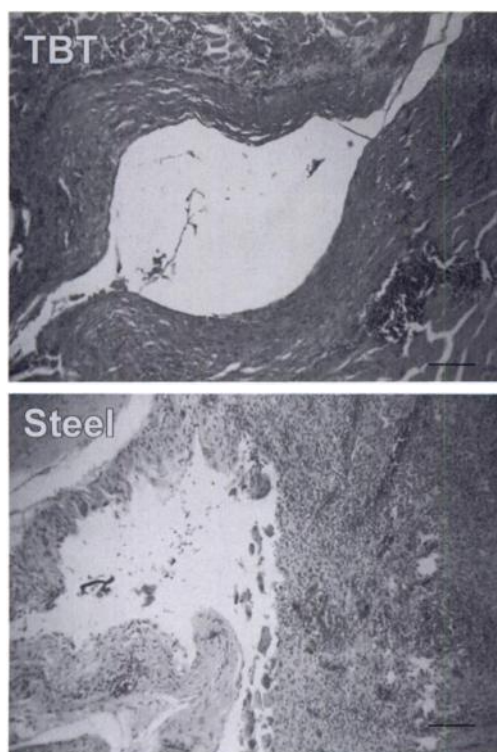


FIGURE 1. Photomicrographs of representative wk 4 shot implant sites at 100 $\times$  magnification in mallards. There is a marked to moderate histiocytic inflammation accompanied by marked adjacent skeletal muscle degeneration and considerable particle deposition at a steel implant site, in contrast to a TBT implant site characterized by mild histiocytic inflammation, skeletal muscle degeneration, and minimal particle deposition. Bar = 120  $\mu$ m.

for steel at wk 8 ( $P = 0.03$ ) (Fig. 2B). Overall response scores, which included skeletal muscle damage and inflammatory changes, were greater for steel implants only at wk 8 ( $P = 0.0007$ ) (Fig. 2C). Inflammatory changes associated with steel implants sites declined between wk 1 and 4 ( $P = 0.01$ ), but wk 1, 2, and 8 did not differ ( $P \geq 0.3$ ). Skeletal muscle and overall response scores for steel implants were greater at wk 1 than at wk 2, 4, and 8 ( $P \leq 0.013$ ). Inflammatory responses at TBT implant sites diminished between wk 1 and 8 ( $P = 0.018$ ). Responses of skeletal muscle to implanted TBT shot were greater for wk 1 than wk 2, 4, and 8 ( $P \leq$

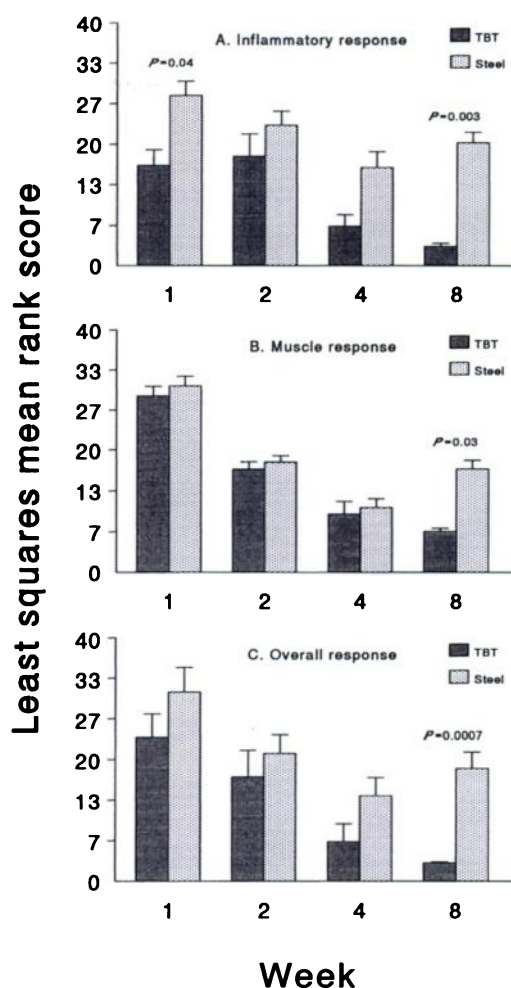


FIGURE 2. Based on least squares mean rank scores, inflammatory (A), muscle (B), and overall (C) responses to experimentally-embedded steel ( $n = 15$ /wk) or TBT ( $n = 15$ /wk) shot diminished over wk 1 to 4, but responses to steel shot were greater ( $P \leq 0.03$ ) than responses to TBT by wk 8. Vertical bars are  $\pm 1$  standard error of least squares mean rank scores.

0.014). Overall tissue responses to implanted TBT shot were greater for wk 1 and 2 than for wk 4 and 8 ( $P \leq 0.017$ ).

All but three implanted shot remained in implant sites and were recovered at necropsy; two TBT shot at wk 8 and one steel shot also during wk 8 were lost to the environment. Weight losses (%) of implanted shot did not differ within weeks ( $P = 0.54$ ), so we pooled within weeks for be-

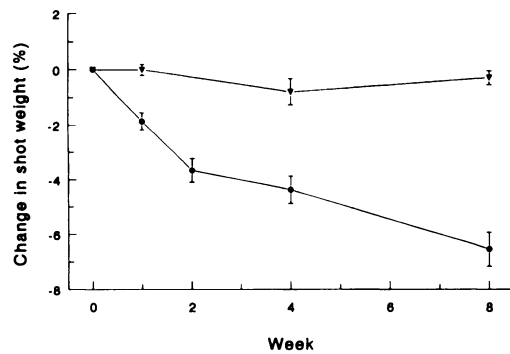


FIGURE 3. Corrosion, as demonstrated by logarithmic ( $R^2 = 0.978$ ,  $P = 0.0014$ ) weight loss occurred in steel shot (●) ( $P = 0.0001$ ); TBT shot (▼) had no evidence of corrosion ( $P = 0.26$ ). Vertical bars are  $\pm 1$  standard error of mean differences in shot weight lost.

tween week comparisons. Steel shot lost weight over time ( $P = 0.0001$ ), and the pattern of weight loss was logarithmic ( $R^2 = 0.978$ ,  $P = 0.0014$ ) (Fig. 3). In contrast, TBT shot did not lose weight ( $P = 0.255$ ) (Fig. 3).

### DISCUSSION

Steel or TBT shot embedded in pectoral muscles of mallards caused only localized tissue reactions and no measurable systemic effects. Muscle tissue within 2.5 mm of, but not including, actual implant sites showed minimal inflammatory changes, thereby underscoring the limited nature of responses we observed. The severity of inflammatory changes associated with implanted steel shot decreased between wk 1 and 4, but increased again by wk 8 after implantation (Fig. 1). These trends may represent renewed inflammatory or immune responses to corrosion and particle deposition at steel implant sites. Whether such trends continued beyond 8 wk was not determined. In contrast, inflammation associated with implanted TBT shot declined over our 8-wk study, and was less than at steel implant sites by wk 8 (Fig. 2C).

Although total WBC counts, monocytes, and total protein all increased over the 8-wk study, we attributed these to the natural growth and development of mallards

used in our experiment, rather than to treatment effects. Absolute leukocyte numbers increase with age in ducks (Hemm and Carlton, 1967), and this phenomenon may have contributed to observed increases in total WBCs and the monocyte subpopulation. Despite these increases, total WBC counts for wk 8 averaged 15,844 cells/mm<sup>3</sup>, well within ranges for normal adult mallards (Hemm and Carlton, 1967; Fairbrother and O'Loughlin, 1990). Aging also affects relative proportions of white blood cell subpopulations in mallards (Fairbrother and O'Loughlin, 1990): between about 60 to 69 days of age and adulthood, circulating heterophils decrease from about 50% to 34% and lymphocytes increase from about 40% to 59%. Ducks used in our experiment were 12 wk old at study initiation and the differential results we observed were consistent with data for healthy juvenile mallards (Fairbrother and O'Loughlin, 1990).

In previous toxicity studies on constituent metals of TBT shot, tungsten and bismuth were inert in tissue, whereas tin was more corrosive (Laing et al., 1967; Venugopal and Luckey, 1978). Inorganic tin and its salts are not highly toxic when ingested because they are absorbed poorly and their oxides are relatively insoluble (Hasset et al., 1984). However, when administered parenterally, tin salts remained at injection sites and caused intense local irritation and tissue damage before being slowly absorbed (Venugopal and Luckey, 1978). Tungsten-bismuth-tin shot contains pure inorganic tin, not tin salts, and we observed only mild inflammatory responses to implanted TBT shot. Although tin oxides may be a breakdown product and subsequent source of chronic irritation, our data offered no evidence of such processes. In light of the relative inertness of embedded TBT shot (Fig. 3), it seems unlikely that appreciable systemic or local absorption of constituent metals would occur; however, neither skeletal muscle nor plasma concentrations of these metals



were measured here. The tissue responses to TBT shot resembled those reported for embedded lead shot, which is rapidly encapsulated, evokes a mild inflammatory response in muscle tissue, and rarely causes clinical effects (Sclafani et al., 1985).

In contrast, Bartels et al. (1991) found that steel shot embedded in dog muscle corroded and resulted in acute, severe, neutrophilic inflammatory response, leading to encapsulation after about 8 wk. They cautioned that likelihood of fistulation and secondary bacterial infection was greater than for embedded lead because initial inflammatory responses to implanted steel appeared quite severe in muscle. In ducks and chickens, however, steel shot implanted into breast muscle for nearly 1 yr apparently caused no ill effects (L. J. Scott, cited in U.S. Fish and Wildlife Service, 1976:45). Our observations support the latter findings. Grossly, we observed encapsulation of steel shot by wk 1; histologically, this was primarily a histiocytic and lymphocytic response. Heterophils, which are analogous to mammalian neutrophils, predominate in acute inflammatory and infectious processes. Few heterophils were observed in response to embedded steel shot in mallards at any point in our 8-wk study, thus we believe that less severe tissue irritation occurred than reported in dogs. Moreover, we detected no evidence of systemic responses to embedded steel shot in mallards. However, we did not measure skeletal muscle nor plasma concentrations of iron. Embedded steel shot apparently has less potential for detrimental effects in mallards than in dogs.

The thickness of the capsule surrounding a human-made material is an indication of its biocompatibility (Gourlay et al., 1978; Black, 1992). The estimated average thickness of capsules surrounding both steel and TBT shot (Table 2) were greater than that regarded as acceptable for human implantation ( $<0.08$  mm; Gourlay et al., 1978). Human implants are tested by aseptically placing the material in a rat,

rabbit, or dog. Shot in this study were sterilized prior to implantation and, although contamination was minimized, they were not implanted surgically. This may have contributed to the extent of observed inflammatory responses, although our control sites had no detectable inflammation after 1 wk. Alternatively, differences between avian and mammalian immune responses may simply preclude reliable application of these human guidelines to mallards. In addition to species differences, motion in tissue surrounding implants can significantly increase the size of fibrotic responses (Black, 1992). Shot in this study were implanted in the pectoral muscles, which are high motion muscles even in captive birds. It follows that although capsule thickness surrounding both shot types was greater than accepted for human use, this study was not designed to test the potential of either shot type for human use. Consequently, making such comparisons seems tenuous at best.

We conclude that neither steel nor TBT shot were acutely toxic when implanted in mallard muscle tissue. Inflammatory reactions to both embedded steel and TBT shot were quite localized, and had no detectable systemic effects on mallard health under experimental conditions. Although local inflammatory responses to embedded steel shot were somewhat more severe than to TBT shot, our interpretation is that embedded steel shot invoked markedly less tissue inflammation and damage in ducks than previously reported in dogs. Our results support further investigation of TBT shot as an alternative nontoxic shot for waterfowl hunting.

#### ACKNOWLEDGMENTS

Our work was supported by Federal Aid To Wildlife Restoration Project Numbers W-153-R 4 and W-166-R 2. V. C. Oltrogge provided TBT shot for use in our experiments. We also thank N. Beckman for assisting with care of experimental birds, J. Ritchie for assisting with blood collection and hematology, J. Van Cleave for radiographing ducks, and M. A. Wild for overseeing housing and management of ducks



and helping conduct necropsies. D. L. Baker, R. M. Bartmann, and M. A. Wild provided helpful reviews on an earlier draft of this manuscript.

#### LITERATURE CITED

- AMERICAN SOCIETY FOR TESTING AND MATERIALS. 1990. Standard practice for preparing, cleaning and evaluating corrosion test specimens. In 1990 annual book of ASTM standards. Vol 03.02. American Society for Testing and Materials, Philadelphia, Pennsylvania, pp. 39–45.
- BARTELS, K. E., E. L. STAIR, AND R. E. COHEN. 1991. Corrosion potential of steel bird shot in dogs. *Journal of the American Veterinary Medical Association* 199: 856–863.
- BELLROSE, F. C. 1959. Lead poisoning as a mortality factor in waterfowl populations. *Illinois Natural History Survey Bulletin* 27: 235–288.
- BLACK, J. 1992. Biological performance of materials. Marcel Decker, Inc., New York, New York, 375 pp.
- FAIRBROTHER, A., AND D. O. O'LOUGHIN. 1990. Differential white blood cell values of the mallard (*Anas platyrhynchos*) across different ages and reproductive states. *Journal of Wildlife Diseases* 26: 78–82.
- GORNALL, A. G., C. J. BARDAWILL, AND M. M. DAVID. 1949. Determination of serum proteins by means of the biuret reaction. *Journal of Biological Chemistry* 177: 751–766.
- GOURLAY, S. J., M. R. RICE, A. F. HEGYELI, C. W. WADE, J. G. DILLON, H. JAFFE, AND R. K. KULKARNI. 1978. Biocompatibility testing of polymers: In vivo implantation studies. *Journal of Biomedical Materials Research* 12: 219–232.
- HASELTINE, S. D., AND L. SILEO. 1983. Response of American black ducks to dietary uranium: A proposed substitute for lead shot. *The Journal of Wildlife Management* 47: 1124–1129.
- HASSET, J. M., D. L. JOHNSON, J. A. MYERS, A. ALMUDAMGHA, M. E. MELCER, C. L. KUTCHER, AND M. M. SEMBRAT. 1984. The exposure of rats to inorganic tin: Behavioral and systemic effects of different levels and modes of exposure. In *Trace substances in environmental health—XVIII*, J. M. Hassett and D. L. Johnson (eds.). University of Missouri Press, Columbia, Missouri, pp. 487–469.
- HEMM, R., AND W. W. CARLTON. 1967. Review of duck hematology. *Poultry Science* 46: 956–962.
- LAING, P. G., A. B. FERGUSON, AND E. S. HODGE. 1967. Tissue reaction in rabbit muscle exposed to metallic implants. *Journal of Biomedical Material Research* 1: 135–149.
- MARTIN, E. M., P. H. GEISSLER, AND A. N. NOVARA. 1991. Preliminary estimates of waterfowl harvest and hunter activity in the United States during the 1990 hunting season. Administration Report, June 1991, U.S. Fish and Wildlife Service, Washington D.C., 33 pp.
- RINGELMAN, J. K., M. W. MILLER, AND W. F. ANDELT. 1993. Effects of ingested tungsten-bismuth-tin shot on captive mallards. *The Journal of Wildlife Management* 57: 725–732.
- SAS INSTITUTE, INC. 1988. SAS/STAT users guide, release 6.03 ed. SAS Institute, Inc. Cary, North Carolina, 1028 pp.
- SCLAFANI, S. J., J. C. VULETIN, AND J. TWERSKY. 1985. Lead arthropathy: Arthritis caused by retained intra-articular bullets. *Radiology* 156: 299–302.
- U.S. FISH AND WILDLIFE SERVICE. 1976. Final environmental statement: Proposed use of steel shot for hunting waterfowl in the United States. U.S. Fish and Wildlife Service, Washington, D.C., 276 pp.
- U.S. FISH AND WILDLIFE SERVICE. 1989. Nontoxic shot. Federal Register 50 Code of Federal Regulations 20.134, 10 October 1989 edition, U.S. Government Printing Office, Washington, D.C., pp. 289–293.
- VENUGOPAL, B., AND T. D. LUCKEY. 1978. Metal toxicity in mammals. 2: Chemical toxicity of metals and metalloids. Plenum Press, New York, New York, 409 pp.

*Received for publication 21 December 1993.*