

Suspected Lysosomal Storage Disease in Kangaroos

Authors: Rothwell, J. T., Harper, P. A. W., Hartley, W. J., Gumbrell, R. C., and Meischke, H. R. C.

Source: Journal of Wildlife Diseases, 26(2) : 275-278

Published By: Wildlife Disease Association

URL: <https://doi.org/10.7589/0090-3558-26.2.275>

BioOne Complete (complete.BioOne.org) is a full-text database of 200 subscribed and open-access titles in the biological, ecological, and environmental sciences published by nonprofit societies, associations, museums, institutions, and presses.

Your use of this PDF, the BioOne Complete website, and all posted and associated content indicates your acceptance of BioOne's Terms of Use, available at www.bioone.org/terms-of-use.

Usage of BioOne Complete content is strictly limited to personal, educational, and non - commercial use. Commercial inquiries or rights and permissions requests should be directed to the individual publisher as copyright holder.

BioOne sees sustainable scholarly publishing as an inherently collaborative enterprise connecting authors, nonprofit publishers, academic institutions, research libraries, and research funders in the common goal of maximizing access to critical research.

Suspected Lysosomal Storage Disease in Kangaroos

J. T. Rothwell,¹ P. A. W. Harper,¹ W. J. Hartley,² R. C. Gumbrell,³ and H. R. C. Meischke,⁴ ¹ New South Wales Agriculture and Fisheries, Regional Veterinary Laboratory, P. M. B. 8, Camden, New South Wales 2570, Australia; ² National Registry of Domestic Animal Pathology, Roy Watts Road, P. M. B. 8, Camden, New South Wales 2570, Australia; ³ Animal Health Laboratory, Box 24, Lincoln, New Zealand; ⁴ Strathallan, Gundaroo, New South Wales 2620, Australia

ABSTRACT: A probable neurovisceral lysosomal storage disease is reported, for the first time, in immature red and grey kangaroos (*Macropus rufus* and *M. giganteus*). Foamy, pale eosinophilic, periodic acid-Schiff positive, intracytoplasmic material was stored in the liver, lymphoid tissue, kidney, adrenal gland, stomach, blood vessels and central nervous system. Extensive Wallerian-type degeneration was present in the central nervous system. Electron microscopic study of one animal revealed electron dense, cytoplasmic lamellar bodies in neurons and foamy visceral cells. The disease differs from other reported storage diseases in the distribution and nature of the lesions.

Key words: Red kangaroo, gray kangaroo, *Macropus rufus*, *Macropus giganteus*, marsupials, lysosomal storage disease, case report.

Lysosomal storage diseases occur when the activity of cellular lysosomal hydrolases are deficient, inhibited by various toxins or overloaded by substrate. Numerous lysosomal storage diseases have been described in humans (Glew et al., 1985) and domestic animals (Sullivan, 1985), but not in marsupials. Here we describe a probable storage disease in two kangaroos.

The first case was an orphaned 12-month-old female eastern grey kangaroo (*Macropus giganteus*) from southern New South Wales, Australia (34°45'S, 149°10'E). The animal had been orphaned at 4 mo of age then hand reared on low lactose, vitamin and mineral supplemented milk powder (Divetelect R, Sharpe Laboratories, Ermington, New South Wales, Australia), some lucerne hay and grass. Despite good care the animal failed to thrive. It became depressed 6 to 7 wk prior to death, and developed diarrhea, anorexia and halitosis. Hematuria and proteinuria were detected 3 wk prior to death (Clinistix, Ames Division, Miles Laboratories, New South Wales, Australia). Convulsions started and became progressively more frequent with

the animal dying during a spasm 1 wk later. At necropsy the carcass was small for the animal's age and the lower incisors had grown inwards and caused malocclusion. Numerous yellow, 1–2 mm, granular lesions were seen in the mesentery, liver, lymph nodes, heart and spleen. The kidneys appeared swollen and pale.

Formalin-fixed spleen, liver, stomach, kidney, adrenal gland, heart and pancreas were processed at the Regional Veterinary Laboratory (Glenfield, New South Wales, Australia) for routine histopathology. The splenic parenchyma was almost completely replaced by large round cells with peripheral ovoid nuclei and vesicular chromatin, containing abundant foamy, pale, eosinophilic cytoplasm. This material was periodic acid-Schiff (PAS) positive, Ziehl-Neelsen negative, Giemsa negative, Luxol-fast blue negative and did not autofluoresce. Similarly, in a mesenteric lymph node, the normal structures were largely displaced by foamy cells. Large aggregates of foamy cells were present throughout the hepatic parenchyma (Fig. 1) and throughout the lamina propria and submucosa of the stomach. The gastric mucosa was atrophic. Small clumps of foamy cells were present in the glomeruli (Fig. 2), renal interstitium and at the junction of the adrenal cortex and medulla. The tunica muscularis of several arteries and arterioles in various organs was distended with foamy cells. There was a segmental renal tubular nephrosis with degeneration and mineralization of tubular epithelial cells and a diffuse, moderate, hepatic lipidosis. Abnormalities were not seen in the myocardium or pancreas. The aggregates of foamy cells seen microscopically corresponded with the granular lesions seen grossly.

The second case was an 8-month-old female

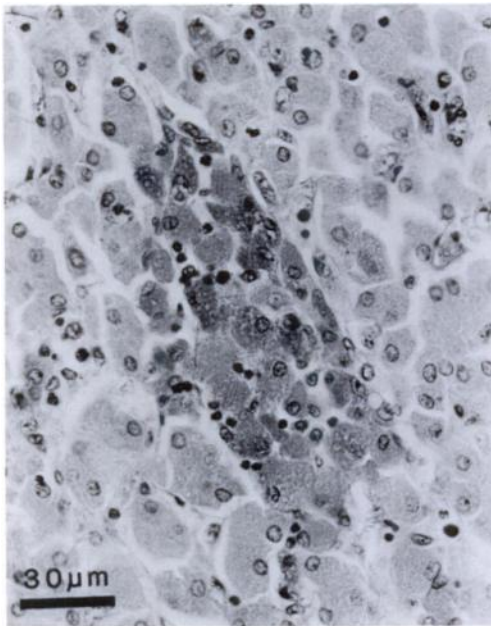


FIGURE 1. Liver of a juvenile grey kangaroo with suspected lysosomal storage disease. Note focal accumulation of cells with PAS positive foamy cytoplasm. PAS.

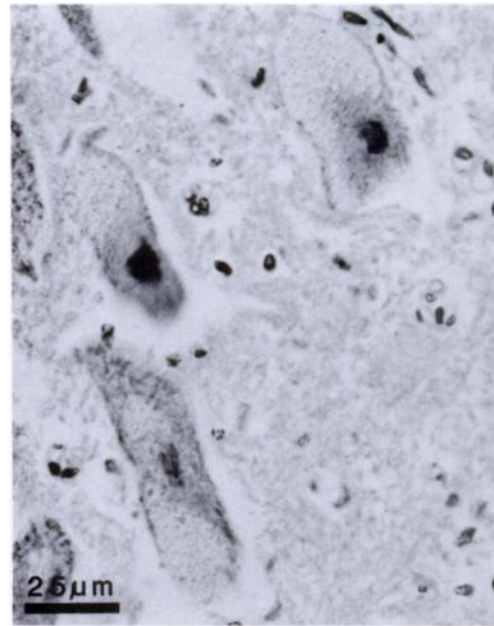


FIGURE 3. Brain of a juvenile red kangaroo with suspected lysosomal storage disease. Note large neurons in the brainstem with foamy vacuolation of their cytoplasm. H&E.

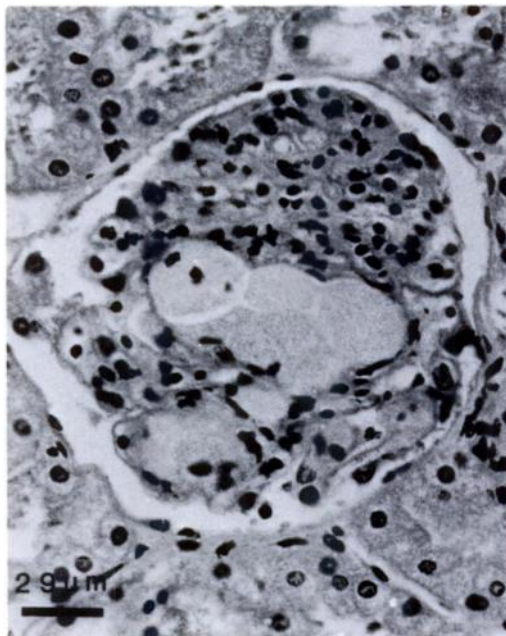


FIGURE 2. Kidney of a juvenile grey kangaroo with suspected lysosomal storage disease. Note foamy cells in renal glomerulus. H&E.

red kangaroo (*Macropus rufus*) reared in Orana Animal Park (Harewood, Christchurch, New Zealand; 43°30'S, 172°30'E). She was the progeny of a park-bred female and a male imported from Dubbo Zoo (New South Wales, Australia). She had been lame prior to veterinary examination. When examined the animal was comatose and febrile. She had tachycardia and pale mucous membranes. Abnormalities were not noted at necropsy. Histopathological examination of liver and kidney revealed similar lesions to those seen in the previous case but with large aggregates of foamy cells in the renal interstitium. In the spinal cord, brain-stem and cerebellar white matter there was a moderate active degeneration of myelin with swelling of axons consistent with Wallerian-type degeneration. The cerebellar Purkinje cells, ventral motor horn neurons and many brain stem neurons exhibited vacuolation of the cytoplasm (Fig. 3) and these vacuoles stained

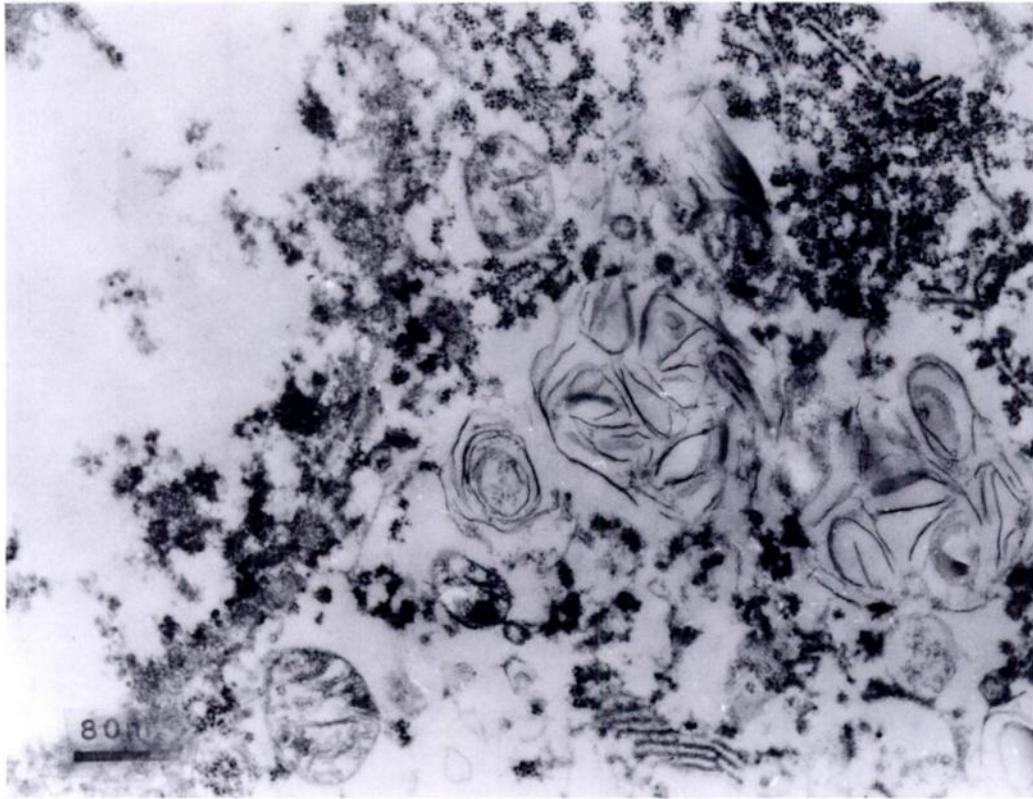


FIGURE 4. Brain of a juvenile red kangaroo with suspected lysosomal storage disease. Transmission electron micrograph of a nerve cell body in the cerebellar white matter showing cytoplasmic lamellar bodies.

PAS positive. There was moderate loss of cerebellar Purkinje cells. Numerous swollen glial cells containing PAS positive material were present in the area of the lateral vestibular nuclei. In the central cerebral white matter, the perivascular spaces of some large blood vessels were dilated and contained some foamy macrophages, which stained PAS positive.

Small blocks of cerebellum, liver and kidney from the second case were selected for transmission electron microscopy. The tissues were postfixed in glutaraldehyde and osmium tetroxide and stained with uranyl acetate. They were embedded in Spurr's resin and ultrathin sections were stained with uranyl acetate and lead citrate. The liver and kidney cells which were foamy at the light microscope level, had few organelles and large electron-lu-

cent spaces in the cytoplasm. These empty spaces were probably areas where storage material had leached away in processing. In some foamy cells disorganized membranous structures and concentric lamellar bodies were present. Nerve cell bodies in the cerebellar white matter contained electron-dense, concentric, lamellar bodies, presumably lysosomal in origin (Fig. 4), and other membranous structures.

On the basis of the clinical and pathological findings we believe that these kangaroos were afflicted with a lysosomal storage disease. The lesions seen in the parenchymal organs of the two animals are very similar so we believe that it is the same or a similar disease despite the difference in species. Alternatively a peroxisomal disorder, could also lead to storage material accumulating in cells (Wanders

et al., 1988) and produce similar findings, although these conditions are very rare. The distribution and nature of the lesions in these two cases, if they are the same entity, differ from any of the reported lysosomal storage diseases. The young age of the animals together with the poor growth and chronic ill-health in the first case suggests a congenital problem. An acquired lysosomal storage disease, such as *Swainsona* spp. poisoning (Dorling et al., 1978), is unlikely considering the differences in environments and the controlled diets. Biochemical analysis of fresh tissue will be required to further classify the disease(s) should any further cases be seen.

We thank the staff of the Histology Department, Liverpool Hospital, New South Wales and S. Wilson and J. Summerfield of the Central Veterinary Laboratory,

Glenfield, New South Wales for assistance with electron microscopy and photography.

LITERATURE CITED

- DORLING, P. R., C. R. HUXTABLE, AND P. VOGEL. 1978. Lysosomal storage in *Swainsona* spp. toxicosis: An induced mannosidosis. *Neuropathology and Applied Neurobiology* 4: 285-295.
- GLEW, R. H., A. BASU, E. M. PRENCE, AND A. T. REMALEY. 1985. Lysosomal storage diseases. *Laboratory Investigation* 53: 250-269.
- SULLIVAN, N. D. 1985. The nervous system. In *Pathology of domestic animals*, Vol. 1, K. V. F. Jubb, P. C. Kennedy, and N. Palmer (eds.). Academic Press, Orlando, Florida, pp. 220-224.
- WANDERS, R. J. A., H. S. A. HEYMANS, R. B. H. SCHUTGENS, P. G. BARTH, H. VANDEN BOSCH, AND T. M. TAGER. 1988. Peroxisomal disorders in neurology. *Journal of Neurological Sciences* 88: 1-39.

Received for publication 19 April 1989.