

HEMATOZOAN PARASITES OF RIO GRANDE WILD TURKEYS FROM SOUTHERN TEXAS

Authors: Castle, Marc D., Christensen, Bruce M., and Rocke, Tonie E.

Source: Journal of Wildlife Diseases, 24(1) : 88-96

Published By: Wildlife Disease Association

URL: <https://doi.org/10.7589/0090-3558-24.1.88>

BioOne Complete (complete.BioOne.org) is a full-text database of 200 subscribed and open-access titles in the biological, ecological, and environmental sciences published by nonprofit societies, associations, museums, institutions, and presses.

Your use of this PDF, the BioOne Complete website, and all posted and associated content indicates your acceptance of BioOne's Terms of Use, available at www.bioone.org/terms-of-use.

Usage of BioOne Complete content is strictly limited to personal, educational, and non - commercial use. Commercial inquiries or rights and permissions requests should be directed to the individual publisher as copyright holder.

BioOne sees sustainable scholarly publishing as an inherently collaborative enterprise connecting authors, nonprofit publishers, academic institutions, research libraries, and research funders in the common goal of maximizing access to critical research.

HEMATOZOAN PARASITES OF RIO GRANDE WILD TURKEYS FROM SOUTHERN TEXAS

Marc D. Castle,¹ Bruce M. Christensen,¹ and Tonie E. Rocke^{1,2}

¹ Department of Veterinary Science, 1655 Linden Drive, University of Wisconsin, Madison, Wisconsin 53706, USA

² Present address: National Wildlife Health Center, 6006 Schroeder Road, Madison, Wisconsin 53711, USA

ABSTRACT: One hundred twenty-three of 300 blood samples (41%) taken from Rio Grande wild turkeys (*Meleagris gallopavo intermedia*) from three locations in southern Texas (Welder Wildlife Refuge, Chaparrosa Ranch, and Campo Alegre Ranch) and subinoculated into domestic broad-breasted white turkey poults were positive for a *Plasmodium* (*Novyella*) sp. Analysis of blood films from 350 turkeys revealed *Haemoproteus meleagridis* in 76% of the birds. A significantly greater mean parasite intensity was observed in birds from Welder Wildlife Refuge. Birds from the Campo Alegre Ranch exhibited a significantly higher prevalence of *H. meleagridis* than birds from Chaparrosa. The *Plasmodium* sp. was infective for canaries (*Serinus canaria*), bobwhites (*Colinus virginianus*), and ring-necked pheasants (*Phasianus colchicus*), but would not produce infection in white leghorn chickens (*Gallus gallus*) or Coturnix quail (*Coturnix coturnix*). Attempts to infect *Culex tarsalis* and *C. pipiens pipiens* were unsuccessful. Asexual erythrocytic synchrony was not observed when blood-induced infections were monitored in two domestic turkey poults every 4 hr for 72 hr. Exoerythrocytic stages were not found upon examination of impression smears and tissue samples taken from brain, liver, spleen, kidney, lung, and bone marrow. The *Plasmodium* sp. is most similar morphologically to three species in the subgenus *Novyella*, *P. hexamerium*, *P. vaughani*, and *P. kempi*. The most striking similarities are to *P. hexamerium*, and involve mean merozoite number, erythrocytic schizont location, and vertebrate host susceptibility. It differs from *P. vaughani* in being able to infect turkeys and in type of parasitized erythrocytes. Differences to *P. kempi* include mean merozoite number, and ability to infect pheasants, and its inability to develop in *C. pipiens* and *C. tarsalis*.

Key words: Rio Grande wild turkeys, *Meleagris gallopavo intermedia*, *Plasmodium* (*Novyella*) sp., *Haemoproteus meleagridis*, hematozoan parasites, natural and experimental infections.

INTRODUCTION

Documentation of *Plasmodium* sp. from wild turkeys in North America began only in the mid-1970's when Forrester et al. (1974) isolated a *Plasmodium* sp. from wild turkeys in Florida. Subsequently, Telford and Forrester (1975) named this species *P. (Huffia) hermani*. In this decade, Christensen et al. (1983) reported a second distinct species from eastern wild turkeys (*Meleagris gallopavo silvestris*) in Iowa, which they named *P. (Novyella) kempi*. Both of these isolations were made by subinoculating collected blood into domestic turkey poults, and not by examination of peripheral blood smears.

Reports of other hematozoan parasites infecting wild turkeys are numerous, but are limited mostly to *Haemoproteus meleagridis* and/or *Leucocytozoon smithi*

(Travis et al., 1939; Mosby and Handley, 1943; Kozicky, 1948; Love et al., 1953; Byrd, 1959; Cook et al., 1966; Goggans, 1966; Roslien and Haugen, 1970; Eve et al., 1972; Stone et al., 1972; Forrester et al., 1974; Noblet and Moore, 1975; Castle and Christensen, 1984). However, a recent report on the recovery of an intraerythrocytic rickettsia (*Aegyptianella pullorum*) from 24 Rio Grande wild turkeys in Texas raised some questions on the possibility of this pathogen infecting domestic fowl as well as indigenous wild birds (Castle and Christensen, 1985).

Herein, we (1) report prevalence data of *H. meleagridis* and a third *Plasmodium* sp. from North American wild turkeys, (2) provide biological information on the *Plasmodium* sp., including vertebrate host specificity, experimental vector studies,

and synchrony data, and (3) discuss the possible taxonomic status of the *Plasmodium* sp.

MATERIALS AND METHODS

Sample collections and parasite isolation

Using a heparinized syringe, blood was taken from the jugular vein of live-trapped Rio Grande wild turkeys from three locations in southern Texas in January and February of 1983 and 1984. Turkeys were captured either by cannon- or drop-net from the Rob and Bessie Welder Wildlife Refuge, San Patricio County; Chaparrrosa Ranch, Zavala County; and, in 1984 only, Campo Alegre Ranch, Willacy County. Thin blood smears were made and the remainder of the collected blood placed on wet ice and shipped to the Department of Veterinary Science (University of Wisconsin, Madison, Wisconsin 53706, USA) for subinoculation into domestic turkey poults (Nicholas broad-breasted white turkeys: obtained at 1 day of age from Jerome Foods, Barron, Wisconsin 54812, USA). Collected blood was inoculated into 5–22-day-old poults either intraperitoneally (i.p.) or intravenously (i.v.) and ranged in volume from 0.5 to 1.0 ml. Times between collection of blood and subinoculation ranged from 1 to 7 days. All recipient birds were housed in the Charmany Farm semi-isolation facilities maintained by the Department of Veterinary Science (University of Wisconsin, Madison, Wisconsin 53706, USA) throughout the course of the investigation. These studies were performed in the winter months when accidental feeding by indigenous mosquitoes would not take place.

Beginning 1 wk postinoculation, blood smears were made twice weekly for 6 wk. A minimum of 20,000 erythrocytes were examined per slide using oil immersion optics (1,250 \times). Erythrocyte numbers were estimated by counting the erythrocytes in a number of random fields, averaging those counts, and then counting the number of fields until a minimum of 20,000 erythrocytes had been viewed. Counts of *H. meleagridis* were all based on 10,000 erythrocytes. Blood smears were stained with Giemsa's at pH 7.2–7.3 (1:10 dilution for 1 hr). Measurements were made using a calibrated ocular micrometer. All measurements are expressed in μ m. Representative specimens of the *Plasmodium* sp. and *H. meleagridis* were deposited in the International Reference Centre for Avian Haematozoa (Memorial University of Newfoundland, St. John's, Newfoundland, Canada A1B 3X9, accession numbers 97607–97608) and in the U.S. National Parasite Collection (Beltsville, Maryland 20705, USA, as USNM collection numbers 79484–79485).

Vertebrate host specificity

Bobwhites, canaries, Coturnix quail, ring-necked pheasants, and white leghorn chickens were inoculated with blood from domestic turkeys with an active parasitemia to determine their susceptibility to the *Plasmodium* sp. Chickens, Coturnix quail, and pheasants were obtained from the Department of Poultry Science (University of Wisconsin, Madison, Wisconsin 53706, USA); bobwhites from Thompson's Quail Farm (Franksville, Wisconsin 53126, USA); and canaries from the laboratory of Dr. R. P. Hanson (Department of Veterinary Science, University of Wisconsin, Madison, Wisconsin 53706, USA).

Birds were inoculated either i.v. or i.p. with 0.2–0.65 ml of heparinized blood and maintained in isolation facilities throughout the study. Beginning 5–7 days postinoculation, blood films were made 2 or 3 times per wk for 4–6 wk. Blood films were stained and examined as previously described.

Laboratory vector studies

Two species of ornithophilic mosquitoes (*Culex pipiens pipiens* and *C. tarsalis*) were obtained from the laboratory of Dr. W. A. Rowley (Department of Entomology, Iowa State University, Ames, Iowa 50011, USA) and tested for their susceptibility to the *Plasmodium* sp. Mosquitoes were reared and maintained as described by Christensen et al. (1983). Sucrose was removed 24 hr prior to blood feeding. All mosquitoes were 4–14 days old when exposed to turkey poults with an active parasitemia.

Blood films were made from infected poults before exposure to mosquitoes, and parasitemia, percentage of gametocytes, and exposure index (parasitemia \times percentage of gametocytes) were determined. The age of turkey poults ranged from 3 to 5 wk. Poults were restrained and placed in mosquito cages for 2–14 hr, depending on the number of mosquitoes blood-feeding to repletion. Blood-fed mosquitoes were removed and placed in 0.473-liter ice cream cartons with a fine-mesh marquisette covering. Mosquitoes were dissected in *Aedes aegypti* saline (Hayes, 1953) using a stereomicroscope. Midguts and salivary glands were examined for oocysts and sporozoites using phase contrast optics.

Synchrony studies

To evaluate whether the *Plasmodium* sp. exhibited any synchrony in its asexual erythrocytic schizogony, two birds were inoculated i.v. with 1.0 ml of infected blood, and once peak parasitemia was reached (approximately 2–3%), the birds were bled every 4 hr beginning at 0900 hr for the next 72 hr. Two blood smears were

TABLE 1. *Haemoproteus meleagridis* and a *Plasmodium* sp. from Rio Grande wild turkeys in southern Texas, 1983–1984.

| Parasite | Trapping site ^a | Prevalence (%) | Intensity (parasites/10,000 erythrocytes) | |
|-----------------------|----------------------------|-------------------------|--|-------|
| | | | Mean (\pm SE) | Range |
| <i>H. meleagridis</i> | WWR—1983 | 75 (61/81) ^b | 10 (1.6) | 1–77 |
| | 1984 | 93 (40/43) | 18 (10.6) | 2–431 |
| | Total | 81 (101/124) | 13 (4.3) | 1–431 |
| | CPR—1983 | 72 (52/72) | 5 (0.8) | 1–24 |
| | 1984 | 61 (64/104) | 4 (0.7) | 1–32 |
| | Total | 66 (116/176) | 5 (0.5) | 1–32 |
| | CAR—1984 | 98 (49/50) | 6 (0.8) | 1–25 |
| <i>Plasmodium</i> sp. | WWR—1983 | 45 (30/67) | ND ^c | ND |
| | 1984 | 18 (8/43) ^d | ND | ND |
| | Total | 34 (38/110) | ND | ND |
| | CPR—1983 | 58 (32/55) | ND | ND |
| | 1984 | 38 (33/87) | ND | ND |
| | Total | 46 (65/142) | ND | ND |
| | CAR—1984 | 41 (20/48) | ND | ND |

^a WWR, Welder Wildlife Refuge; CPR, Chaparrosa Ranch; CAR, Campo Alegre Ranch.^b Number infected/number examined.^c ND, not determined.^d Identified by direct blood smears only.

made from each bird at each bleeding and were stained and examined as previously described.

Trophozoites, immature schizonts, mature schizonts, immature gametocytes, and mature gametocytes were then counted per 10,000 erythrocytes for each blood film, and the data analyzed for any evidence of asexual synchrony.

Determination of exoerythrocytic schizogony

Although no controlled studies were performed, infected turkey poults of various ages and stages of infection (before, during, and after active parasitemia) were necropsied periodically and examined for possible sites of exoerythrocytic schizogony. Impression smears were made and tissue samples were taken from brain, liver, spleen, kidney, lung, and bone marrow. Impression smears were stained with Giemsa's as described previously, and tissues were cut at 5 μ m and stained with haematoxylin and eosin. Both were screened at 500 \times and examined using oil immersion optics (1,250 \times).

Statistical analysis

Prevalence data for *H. meleagridis* and the *Plasmodium* sp. were analyzed using chi-square analysis of 2 \times 2 contingency tables, intensity data analyzed by Student's *t*-test and ANOVA, and synchrony data by ANOVA. Prior to these analyses, intensity data were tested for normal distribution by chi-square analysis. Consequently, log transformations of the data were per-

formed and the data retested for normal distribution. All analyses were done from statistical packages on a Hewlett-Packard HP 86 micro-computer system (Hewlett-Packard Company, 1010 N.E. Circle Boulevard, Corvallis, Oregon 97330, USA). Differences were considered significant at $P < 0.05$.

RESULTS

Prevalence

Data on prevalence and intensity are presented in Table 1. Seventy-six percent of 350 turkeys were positive for *H. meleagridis*. Birds from Welder Wildlife Refuge consistently exhibited a significantly greater mean parasite intensity (number of parasites/10,000 erythrocytes) than birds from Chaparrosa or Campo Alegre Ranches. Although prevalence of *H. meleagridis* in birds from Campo Alegre was significantly higher than those of Chaparrosa, intensity of infection was not statistically different.

Of the 123 samples positive for the *Plasmodium* sp., 15 (12%) were identified by observation of the parasite on direct blood films. The majority of these (eight) were

TABLE 2. Susceptibility of different avian species to a *Plasmodium* sp. from Rio Grande wild turkeys in Texas.

| Blood passage | Number exposed | Species | Age | Route of inoculation | Number infected (%) |
|---------------|----------------|-----------|---------|----------------------|---------------------|
| 3rd | 4 | bobwhites | adult | i.v. | 4 (100) |
| 4th | 8 | Coturnix | 13 days | i.p. | 0 (0) |
| 4th | 5 | chickens | 4 days | i.p. | 0 (0) |
| 4th | 5 | pheasants | 28 days | i.v. | 5 (100) |
| 4th | 3 | canaries | adult | i.p. | 2 (100)* |

* One canary died before it was tested.

from Welder Wildlife Refuge in 1984, when circumstances prevented the subinoculation of blood into domestic poults. The prevalences of *Plasmodium* sp. from the three trapping sites were not significantly different. There was no significant difference in the percentage of positive samples due to the age of collected blood, nor due to the age or sex of the infected wild bird.

Seventy-six percent of the samples positive for *Plasmodium* sp. were infected also with *H. meleagridis* (94/123). *Leucocytozoon smithi* was not observed on any direct smear from wild turkeys.

Vertebrate host specificity

Canaries, bobwhites, and pheasants supported the development of all erythrocytic stages of the *Plasmodium* sp. Development of the parasite did not occur in chickens or Coturnix quail (Table 2).

Laboratory vector studies

Exposure indexes of infected turkey poults, mosquito species exposed, and results are given in Table 3. Neither mosquito species exposed to infective blood meals supported the development of the *Plasmodium* sp. isolate.

Description of *Plasmodium* sp. erythrocytic stages

Trophozoites: Immature trophozoites small, measuring less than 1 μ m, consisting of little more than a light red staining nucleus and a small amount of pale bluish-grey cytoplasm (Fig. 1). As the parasite

matured, a vacuole appeared and pseudopodia were often present and one or two small pigment granules appeared in the older stages (Fig. 2). Trophozoites averaged 1.0×1.5 ($0.7\text{--}1.5 \times 0.7\text{--}2.2$; $n = 20$). Only mature erythrocytes were infected and trophozoites exhibited a general distribution within the cell (polar, subpolar, or lateral). As many as three trophozoites could be found within one cell, with no obvious displacement of the nucleus (Fig. 3).

Schizonts: Immature schizonts typically with plentiful cytoplasm and elongate, with nuclei developing along the periphery (Fig. 4). As they matured the cytoplasm was less obvious, the nuclei condensed and the segmenters took on various shapes; irregular, round or "fan-shaped," rarely in strands, often becoming so condensed the actual number of nuclei was somewhat obscured (Figs. 5–8). Merozoite

TABLE 3. Parasitemia, percentage of gametocytes, and exposure index of turkeys used to expose a *Plasmodium* sp. isolated from wild turkeys in Texas to *Culex tarsalis* and *C. pipiens pipiens*.

| Turkey number | Mosquito species | Parasitemia* | Gametocytes (%) | Exposure index ^b |
|---------------|-----------------------------------|--------------|-----------------|-----------------------------|
| 1 | <i>C. tarsalis</i> ^c | 308 | 10.4 | 3,203 |
| 2 | <i>C. tarsalis</i> ^d | 136 | 4.6 | 625 |
| 3 | <i>C. p. pipiens</i> ^e | 89 | 3.4 | 300 |

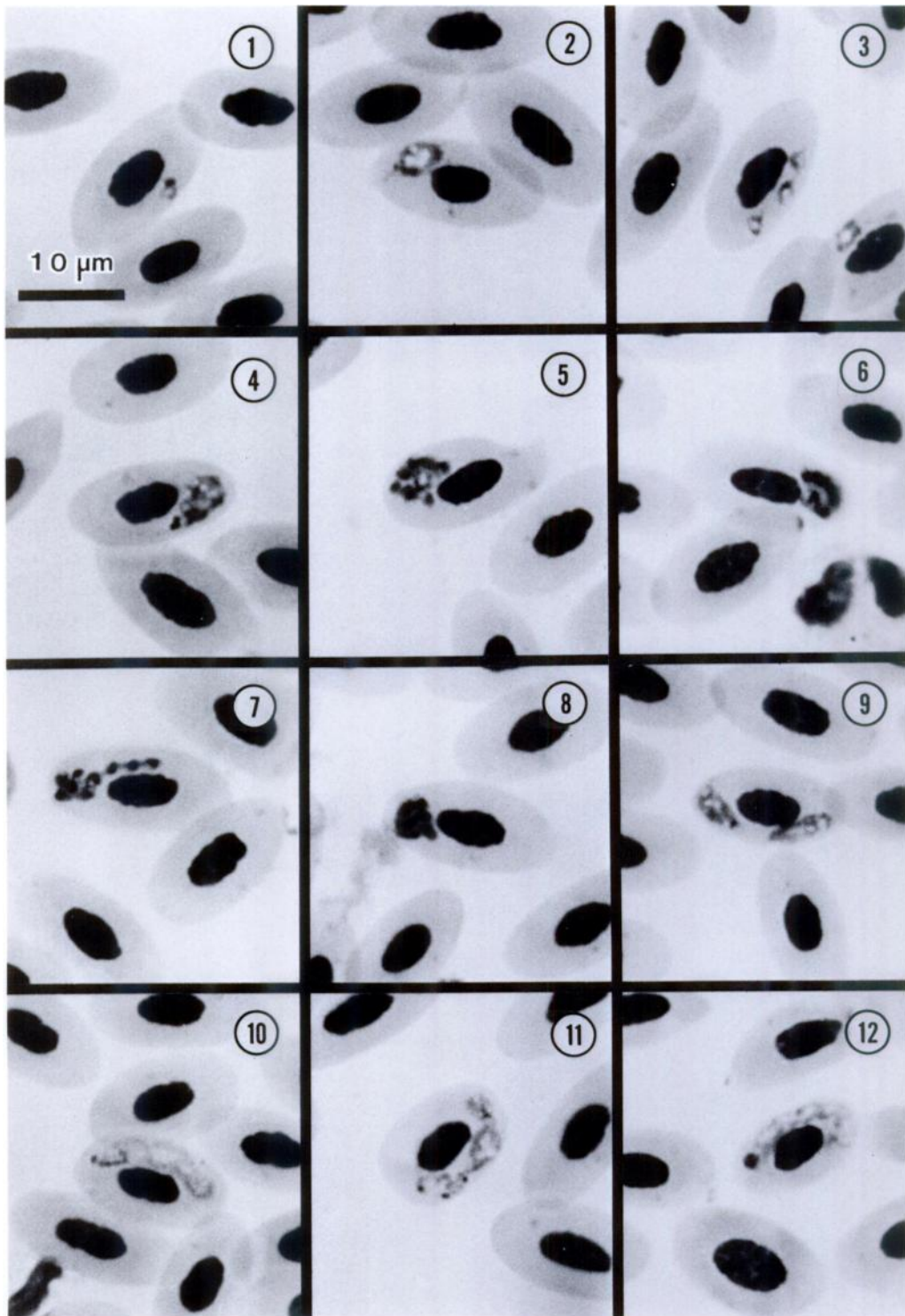
* Parasites per 10,000 erythrocytes.

^b Exposure index = parasitemia \times % gametocytes.

^c Six blood-fed mosquitoes dissected.

^d Seven blood-fed mosquitoes dissected.

^e Ninety blood-fed mosquitoes dissected.



FIGURES 1-12. Erythrocytic stages of *Plasmodium* (*Novyella*) sp. from Rio Grande wild turkeys. 1. Immature trophozoite. 2. Mature trophozoite. 3. Mature trophozoites. 4. Immature schizont. 5-8. Mature schizonts. 9. Immature gametocyte. 10. Mature microgametocyte. 11. Lobulated, mature microgametocyte. 12. Mature macrogametocyte.

number ranged from 5 to 8 with an average of 6.3, the majority possessing six merozoites (50%), while schizonts averaged 2.4×3.3 ($1.5\text{--}2.9 \times 2.9\text{--}4.4$; $n = 20$). Pigment granules were present and ranged from 1 to 5 per schizont. No nuclear displacement was observed.

Gametocytes: Immature gametocytes often were difficult to distinguish from mature trophozoites, assuming a "torpedo-shape" (Fig. 9). Although the cytoplasm of both macro- and microgametocytes stained poorly, macrogametocytes stained a deeper blue than did microgametocytes. When mature, macrogametocytes averaged 8.0×1.8 ($7.3\text{--}8.8 \times 1.5\text{--}2.2$; $n = 20$) and microgametocytes averaged 9.1×1.9 ($7.3\text{--}10.2 \times 1.5\text{--}2.2$; $n = 20$) and usually filled the space between the nucleus and the erythrocyte margin (Fig. 10), although the gametocytes sometimes were highly lobulated (Fig. 11). Pigment granules were present and occupied various positions within the parasite, either scattered or at one or both poles (Fig. 12). There was no evidence of nuclear displacement and the erythrocyte nucleus was rarely pyknotic.

Synchrony studies

Synchrony was not observed in either bird after inoculation with the *Plasmodium* sp.

Exoerythrocytic schizogony

Exoerythrocytic stages were not seen in any impression smear or tissue sample.

DISCUSSION

Cook et al. (1966) examined blood smears from 133 Rio Grande wild turkeys at the Welder Wildlife Refuge and reported an 80% prevalence of *Haemoproteus meleagridis*. Subinoculations of blood were not made and *Plasmodium* sp. were not reported. As stated previously, observations of *Plasmodium* sp. from direct smears were made during this study, but accounted for only 12% of the total recoveries. In contrast, all species of *Plasmodium* from domestic turkeys, *P. durae* by

Herman (1941), *P. griffithsi* by Garnham (1966), and *P. tejaraei* by Gabaldon and Ulloa (1977), were found in direct smears. Again, this demonstrates the importance of using isodiagnosis for examining wild turkeys for *Plasmodium* sp. infections.

Corradetti et al. (1963) published a classification for the avian malaria parasites based on four subgenera, *Haemamoeba*, *Giovannolaia*, *Novyella*, and *Huffia*. The parasite recovered from wild turkeys in Texas is similar to several species found in two of the subgenera, *Novyella* and *Giovannolaia*. Species belonging to the subgenus *Novyella* have small erythrocytic schizonts, elongate gametocytes, with exoerythrocytic schizogony occurring in the mononuclear phagocyte system. Species found in *Giovannolaia* characteristically have large erythrocytic schizonts, elongate gametocytes, and exoerythrocytic schizogony occurs also in the mononuclear phagocyte system.

Our isolate is similar to three species in the subgenus *Novyella*, *P. hexamerium*, *P. vaughani*, and *P. kempi*. The most striking similarities are to *P. hexamerium*, and involve the schizont, merozoite number and vertebrate host susceptibility. Merozoites of *P. hexamerium* can be arranged in a circle, in an irregular formation, laterally positioned, or elongate, and range in number from six to eight, with an average of six (Huff, 1935; Garnham, 1966). The average number of merozoites found in our isolate was slightly over six and the schizont location and formation parallels that of *P. hexamerium*. *Plasmodium hexamerium* also has been transmitted successfully to canaries (Huff, 1935) and turkeys (Manwell, 1952), but will not infect chickens (Garnham, 1966). This is consistent also with the parasite isolated from Texas (Table 2).

A similar species, *P. vaughani* like *P. hexamerium* and this isolate, will infect also canaries and not chickens, but differs in being unable to infect turkeys (Manwell, 1952). In addition, merozoite number ranges from four to eight, very similar to

that of the Texas isolate. Other differences of this isolate with *P. vaughani* include the number of granules found in the gametocytes and in the types of red blood cells the parasites invade. The isolate from Texas is found invariably in mature erythrocytes whereas *P. vaughani* has a tendency to invade erythroblasts and other immature cells (Laird, 1962). Two to 24 pigment granules may be found in the gametocytes of *P. vaughani*, depending on the strain (Garnham, 1966), which is much more than the maximum of 12 seen in our isolate.

A third species, *P. kemp*i, found in eastern wild turkeys from Iowa (Christensen et al., 1983), also shows morphological similarities to the species from wild turkeys in Texas. The number of merozoites is similar for both species (four to eight) although the average for *P. kemp*i is five, compared to an average of six reported here. However, mature schizonts of *P. kemp*i are found most often in a "fan-shape," which was seen only rarely in this study. Both species also will infect canaries and bobwhites, but will not infect chickens or Coturnix quail. One difference is that pheasants were infected readily by the Texas isolate but were not infected by *P. kemp*i.

The one species in the subgenus *Giovannolaia*, *P. polare*, that is similar morphologically to our isolate, has never been isolated before from wild turkeys (Bennett et al., 1982). Other differences include the higher number of merozoites in *P. polare* (eight to 14) and the large amount of cytoplasm in mature schizonts (Manwell, 1935). One similarity was in the "stranded" appearance of the merozoites, although this was observed rarely. The taxonomic position of *P. polare* was debated by Corradetti and Scanga (1973) as to whether it should even be placed in the subgenus *Giovannolaia*, but because it possesses more than eight merozoites and because the mature schizont contains plentiful cytoplasm it remains in *Giovannolaia* (Garnham, 1966).

The characteristics of the parasite described here (scant cytoplasm in the mature schizont, never with more than eight merozoites, and elongate gametocytes) clearly place this species in the subgenus *Novyella*. Additionally, the absence of synchrony in the asexual erythrocytic cycle is common in this subgenus (Seed and Manwell, 1977). However, difficulties arise in attempting to assign this parasite to a particular species. The three species of *Novyella* mentioned already have morphological similarities and also share some biological similarities. Recently, Bennett et al. (1982) reported that they regard *P. hexamerium* as a synonym of *P. vaughani*. Christensen et al. (1983), in naming *P. kemp*i as a previously unreported species, used as their criteria the biological differences mentioned already as well as work with experimental vectors. They reported parasite development to both oocyst and sporozoite stages in *Culex pipiens pipiens*, *C. restuans* and *C. tarsalis*, with the latter species functioning as a slightly better laboratory vector. Studies with *P. hexamerium* and *P. vaughani* were unsuccessful in their attempts to infect the same mosquito species with either species of *Plasmodium* (Manwell, 1947; Huff, 1965), although Janovy (1966) was able to demonstrate parasite development of *P. hexamerium* in *C. tarsalis*. Attempts to infect both mosquito species with the isolate from Texas have been unsuccessful to date, although the number of *C. tarsalis* used in our study was very limited. An attempt was made in August of 1986 to identify the natural vector(s) of the *Plasmodium* sp., but due to dry conditions no mosquitoes were caught.

It is likely that the parasite reported here is a strain or subspecies of *P. vaughani* or *P. hexamerium*, assuming the latter is a valid species. Corradetti et al. (1961) believe that *P. vaughani* is still undergoing speciation to such a great degree that identification of the species is difficult, which could account also for the minor biological differences observed between the two

species. If this is the case, *P. kempti* probably could be included in this species-complex. Elucidation of the complete life cycle of the parasite isolated from Texas, including site of exoerythrocytic schizogony and invertebrate host susceptibility is needed before a more precise identification is possible.

ACKNOWLEDGMENTS

The authors thank James G. Teer and the Welder Wildlife Foundation, the Chaparral Ranch, and the Campo Alegre Ranch for allowing us to collect blood samples; Jerome Foods for donating turkey poult; and Becky Huff, John Gustafson, Carolyn Tiller, Karen Harris and Linda Christensen for their able technical assistance. This study was supported in part by the College of Agricultural and Life Sciences, University of Wisconsin-Madison, Animal Health Project No. 2676, and by a Grant-In-Aid from the National Wild Turkey Federation.

LITERATURE CITED

- BENNETT, G. F., M. WHITEWAY, AND C. WOODWORTH-LYNAS. 1982. A host-parasite catalogue of the avian haematozoa. Memorial University of Newfoundland Occasional Papers in Biology, No. 5, 243 pp.
- BYRD, M. A. 1959. Observations on *Leucocytozoon* in pen-raised and free-ranging wild turkeys. *Journal of Wildlife Management* 23: 145-156.
- CASTLE, M. D., AND B. M. CHRISTENSEN. 1984. Blood and gastrointestinal parasites of eastern wild turkeys from Kentucky and Tennessee. *Journal of Wildlife Diseases* 20: 190-196.
- , AND ———. 1985. Isolation and identification of *Aegyptianella pullorum* (Rickettsiales, Anaplasmataceae) in wild turkeys from North America. *Avian Diseases* 29: 437-445.
- CHRISTENSEN, B. M., H. J. BARNES, AND W. A. ROWLEY. 1983. Vertebrate host specificity and experimental vectors of *Plasmodium* (*Novyella*) *kempti* sp. n. from the eastern wild turkey in Iowa. *Journal of Wildlife Diseases* 19: 204-213.
- COOK, R. S., D. O. TRAINER, AND W. C. GLAZENER. 1966. *Haemoproteus* in wild turkeys from the coastal bend of south Texas. *Journal of Protozoology* 13: 588-590.
- CORRADETTI, A., P. C. C. GARNHAM, AND M. LAIRD. 1963. New classification of the avian malarial parasites. *Parassitologia* 5: 1-4.
- , I. NERI, C. PALMIERI, F. VEROLINI, V. GIULIANI, AND M. SCANGA. 1961. Note su *Plasmodium vaughani* e su un plasmodio con ciclo schizogonico endoemoblastico di tipo *elongatum* rinvenuti in *Turdus merula*. *Parassitologia* 3: 97-100.
- , AND M. SCANGA. 1973. The *Plasmodium vaughani*-complex. *Experimental Parasitology* 34: 344-349.
- EVE, J. H., F. E. KELLOGG, AND F. A. HAYES. 1972. Blood parasitism in wild turkeys in the southeastern United States. *Journal of the American Veterinary Medical Association* 161: 638-640.
- FORRESTER, D. J., L. T. HON, L. E. WILLIAMS, JR., AND D. H. AUSTIN. 1974. Blood protozoa of wild turkeys in Florida. *Journal of Protozoology* 21: 494-497.
- GABALDON, A., AND G. ULLOA. 1977. *Plasmodium* (*Haemamoeba*) *tejarai* sp. n. del pavo domestico (*Meleagris gallopavo*) de Venezuela. *Boletin de la Direccion de Malariologia y Saneamiento Ambiental* 17: 255-273.
- GARNHAM, P. C. C. 1966. Malaria parasites and other haemosporidia. Blackwell Scientific Publications, Oxford, England, 1114 pp.
- GOGGANS, J. G. 1966. A survey of blood parasites in the wild turkey of Alabama. M.S. Thesis. University of Auburn, Auburn, Alabama, 46 pp.
- HAYES, R. O. 1953. Determination of a physiological saline for *Aedes aegypti* (L.). *Journal of Economic Entomology* 46: 624-627.
- HERMAN, C. M. 1941. *Plasmodium durae*, a new species of malaria parasites from the common turkey. *American Journal of Hygiene* 34: 22-26.
- HUFF, C. G. 1935. *Plasmodium hexamerium*, n. sp. from the bluebird, inoculable to canaries. *American Journal of Hygiene* 22: 274-277.
- . 1965. Susceptibility of mosquitoes to avian malaria. *Experimental Parasitology* 16: 107-132.
- JANOVY, J., JR. 1966. Epidemiology of *Plasmodium hexamerium* Huff, 1935, in meadowlarks and starlings of the Cheyenne Bottoms, Barton County, Kansas. *Journal of Parasitology* 52: 573-578.
- KOZICKY, E. L. 1948. Some protozoan parasites of the eastern wild turkey in Pennsylvania. *Journal of Wildlife Management* 27: 261-271.
- LAIRD, M. 1962. Malayan protozoa, 5. Two avian malaria parasites. *Journal of Protozoology* 9: 21-26.
- LOVE, G. J., S. A. WILKIN, AND M. H. GOODWIN. 1953. Incidence of blood parasites in birds collected in southwestern Georgia. *Journal of Parasitology* 39: 53-57.
- MANWELL, R. D. 1935. *Plasmodium vaughani* (Novy and MacNeal). *American Journal of Hygiene* 21: 180-187.
- . 1947. Failure of *Aedes aegypti* and *Culex pipiens* to transmit *Plasmodium vaughani*. *Journal of Parasitology* 33: 167-169.
- . 1952. Turkeys and ducks as experimental hosts for *Plasmodium hexamerium* and *P. vaughani*. *Experimental Parasitology* 1: 274-282.
- MOSBY, H. S., AND C. O. HANDLEY. 1943. The wild turkey in Virginia: Its status, life history, and management. Virginia Commonwealth Game

- and Inland Fisheries, Richmond, Virginia, 281 pp.
- NOBLET, R., AND H. S. MOORE. 1975. Prevalence and distribution of *Leucocytozoon smithi* and *Haemoproteus meleagridis* in wild turkeys in South Carolina. *Journal of Wildlife Diseases* 11: 516-518.
- ROSLIEN, D. J., AND A. O. HAUGEN. 1970. Some blood parasite and disease antibody findings in wild Rio Grande turkeys stocked in Iowa. *Proceedings of the Iowa Academy of Science* 77: 93-96.
- SEED, T. M., AND R. D. MANWELL. 1977. Plasmodia of birds. In *Parasitic protozoa*, Vol. III, J. P. Kreier (ed.). Academic Press, New York, New York, pp. 311-357.
- STONE, W. B., L. W. DEGRAFF, S. W. EATON, AND B. L. WEBER. 1972. Blood parasites of wild turkeys in New York. *New York Fish and Game Journal* 19: 116-122.
- TELFORD, S. R., AND D. J. FORRESTER. 1975. *Plasmodium (Huffia) hermani* sp. n. from wild turkeys (*Meleagris gallopavo*) in Florida. *Journal of Protozoology* 22: 324-328.
- TRAVIS, B. V., M. H. GOODWIN, JR., AND E. GAMBRELL. 1939. Preliminary note on the occurrence of *Leucocytozoon smithi* Laveran and Lucet (1905) in turkeys in the southeastern United States. *Journal of Parasitology* 25: 278.

Received for publication 3 November 1986.