

## **VAGINAL FIBROMAS IN A BEAKED WHALE, *Mesoplodon densirostris***

Authors: FLOM, J. O., BROWNE, R J., JONES, E., and SCHONEWALD, J.

Source: Journal of Wildlife Diseases, 16(1) : 99-102

Published By: Wildlife Disease Association

URL: <https://doi.org/10.7589/0090-3558-16.1.99>

---

BioOne Complete ([complete.BioOne.org](https://complete.BioOne.org)) is a full-text database of 200 subscribed and open-access titles in the biological, ecological, and environmental sciences published by nonprofit societies, associations, museums, institutions, and presses.

Your use of this PDF, the BioOne Complete website, and all posted and associated content indicates your acceptance of BioOne's Terms of Use, available at [www.bioone.org/terms-of-use](https://www.bioone.org/terms-of-use).

Usage of BioOne Complete content is strictly limited to personal, educational, and non - commercial use. Commercial inquiries or rights and permissions requests should be directed to the individual publisher as copyright holder.

---

BioOne sees sustainable scholarly publishing as an inherently collaborative enterprise connecting authors, nonprofit publishers, academic institutions, research libraries, and research funders in the common goal of maximizing access to critical research.

## VAGINAL FIBROMAS IN A BEAKED WHALE, *Mesoplodon densirostris*

J. O. FLOM,<sup>1</sup> R. J. BROWN,<sup>2</sup> R. E. JONES<sup>3</sup> and J. SCHONEWALD<sup>4</sup>

**Abstract:** Necropsy of a mature female Blainville's beaked whale (*Mesoplodon densirostris*) revealed two vaginal fibromas.

### CASE REPORT

Fibromas may occur in any fibrous connective tissue, and are commonly found in the dermis or subcutis.<sup>1</sup> Fibromas usually are found in mature or aged animals and have been reported in a wide variety of species,<sup>3</sup> including marine mammals.<sup>1,2,4</sup> This paper describes two vaginal tumors, diagnosed as fibromas, from a mature female Blainville's beaked whale (*Mesoplodon densirostris*). The authors are unable to find previous reports of neoplasia in this species.

The whale was observed trapped in the rocks near Pescadero State Beach, San Mateo County, California. Profuse bleeding from the snout area prompted a rescue operation, but the whale died before the rescue was completed. The cause of death appeared to be the result of severe trauma to the anterior snout. Extensive soft tissue damage and comminuted fractures of the maxilla and mandible were evident upon examination. The origin of the trauma was not determined. Examination of the urogenital tract revealed two vaginal tumors adjacent to the os cervix. The tumors were removed, fixed in 10% buffered formalin, embedded in paraffin, sectioned and stained with hematoxylin and eosin.

### RESULTS

Both tumors were firm, grayish-white, stalked and pedunculated (Fig. 1). One mass was circular and measured approximately 1 cm in diameter while the second mass was ovoid and measured approximately 4.5 cm × 2.2 cm. Microscopic examination revealed an eosinophilic tissue with low cellularity, comprised mainly of mature collagen. No epidermal covering was evident (Fig. 2) and the cells present had indistinct outlines with a variety of nuclear morphology ranging from oval-tear-drop shapes to elongated and flat, typical of fibroblasts (Fig. 3). Some nuclei which were elongated and flat were also hyperchromic. Mitotic figures were not seen. Numerous neo-capillaries with their endothelial cells sloughed into the lumens were also evident. Based on the gross and microscopic features, the tumors were classified as fibromas.

### DISCUSSION

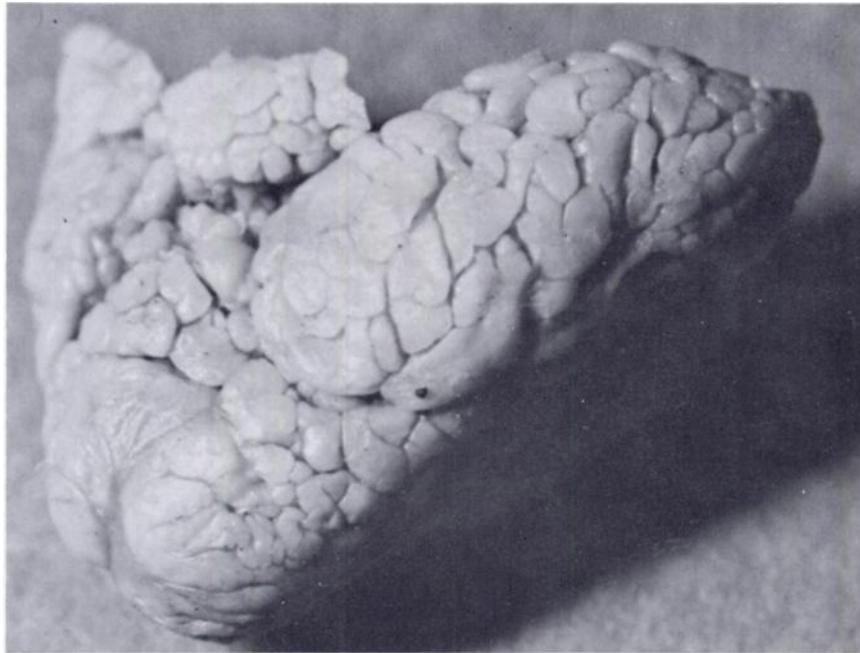
Reports of neoplasia in cetaceans are limited, and of those available, most are from past decades and describe neoplasms in the commercially exploited baleen whales.<sup>2</sup> Only a few recent reports exist, and are primarily from small

<sup>1</sup> Naval Biosciences Laboratory, Naval Supply Center, Oakland, California 94625, USA.

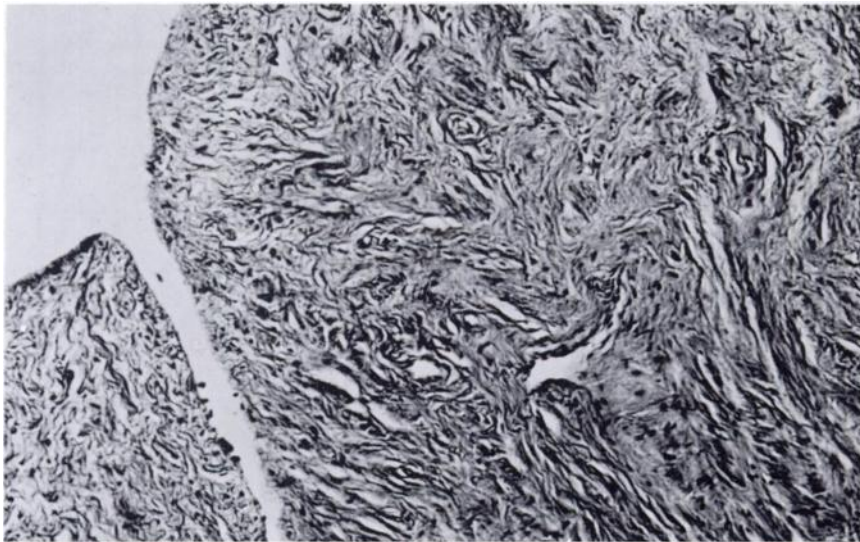
<sup>2</sup> Comparative Pathology Department, Naval Aerospace Medical Research Laboratory, Pensacola, Florida 32512, USA.

<sup>3</sup> Museum of Vertebrate Zoology, University of California, Berkeley, California 94720, USA.

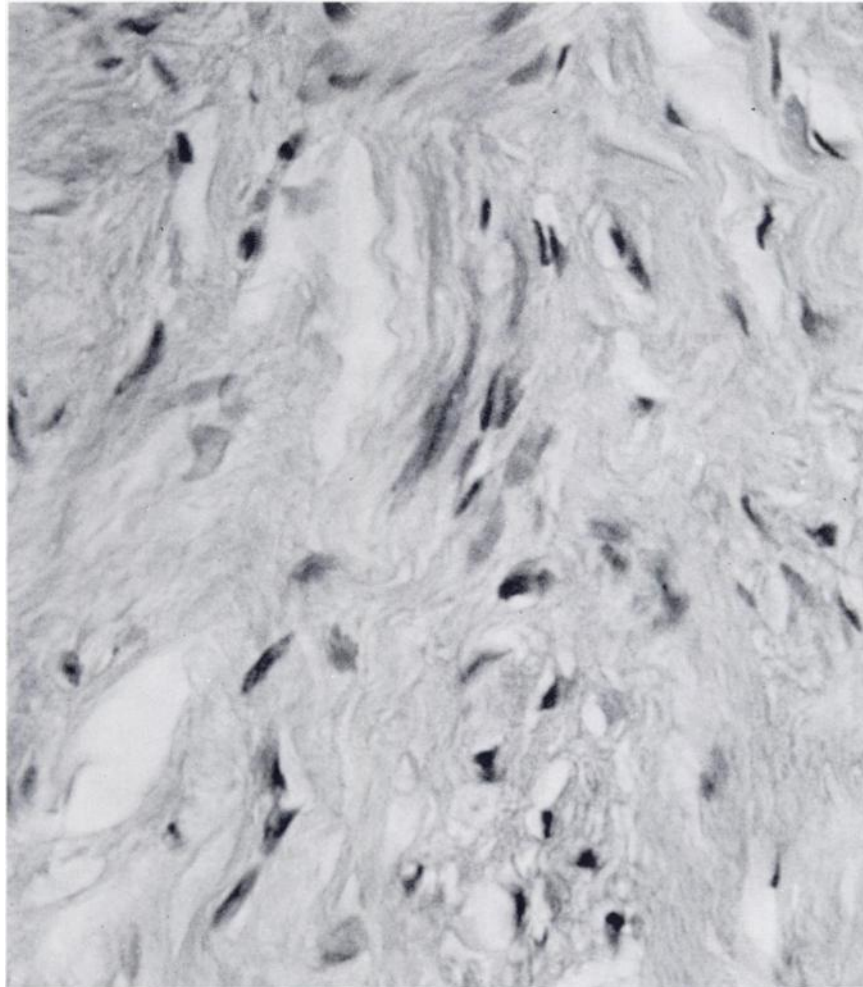
<sup>4</sup> California Academy of Sciences, Golden Gate Park, San Francisco, California 94118, USA.



**FIGURE 1.** Photograph of tumor. Note lobulated appearance.



**FIGURE 2.** Section showing whorls and nests of fibroblasts and collagen. Also note absence of any epidermal covering. 63X.



**FIGURE 3.** Section demonstrating the variety of nuclear shapes and indistinct cell outlines. 400X.

cetaceans held as exhibit animals.<sup>2</sup> Sightings and/or strandings of beaked whales are considered rare occurrences. In fact, the whale in the present report is

the first recorded of this species for the eastern Pacific Coast.<sup>5</sup> This paper is an addition to the limited records of neoplasia in cetaceans.

#### **Acknowledgements**

We would like to thank the California Parks Service, California Marine Mammal Center, California Department of Fish and Game and the San Francisco Office of the National Marine Fisheries Service for making this specimen available for study.

**LITERATURE CITED**

1. BROWN, R.J., A.W. SMITH and M.C. KEYES. 1975. Renal fibrosarcoma in the Northern fur seal. *J. Wildl. Dis.* 11: 23-25.
2. GREENWOOD, A.G., J. HARRISON and H.W. WHITTING. 1974. Functional and Pathological Aspects of the Skin of Marine Mammals. pp. 73-111. In: *Functional Anatomy of Marine Mammals*. R.J. Harrison, Ed. Academic Press, Inc., London.
3. MOULTON, J.E. 1961. *Tumors in Domestic Animals*. pp. 21-23. University of California Press, Berkeley.
4. RIDGWAY, S.H. 1972. Homeostasis in the Aquatic Environment. pp. 590-747. In: *Mammals of the Sea*. S.H. Ridgway, Ed. Charles C. Thomas, Springfield, Ill.
5. SCHONEWALD, J. 1978. Academically speaking: A beaked whale. *Pacific Discovery* 6: 28-31.

*Received for publication 18 January 1979*

---