

Localization of Neuropeptide Y-like Immunoreactivity in the Saccus Vasculosus of Cartilaginous and Bony Fishes

Authors: Chiba, Akira, Sohn, Young Chang, Oka, Shunya, and Honma, Yoshiharu

Source: Zoological Science, 13(3) : 347-350

Published By: Zoological Society of Japan

URL: <https://doi.org/10.2108/zsj.13.347>

BioOne Complete (complete.BioOne.org) is a full-text database of 200 subscribed and open-access titles in the biological, ecological, and environmental sciences published by nonprofit societies, associations, museums, institutions, and presses.

Your use of this PDF, the BioOne Complete website, and all posted and associated content indicates your acceptance of BioOne's Terms of Use, available at www.bioone.org/terms-of-use.

Usage of BioOne Complete content is strictly limited to personal, educational, and non - commercial use. Commercial inquiries or rights and permissions requests should be directed to the individual publisher as copyright holder.

BioOne sees sustainable scholarly publishing as an inherently collaborative enterprise connecting authors, nonprofit publishers, academic institutions, research libraries, and research funders in the common goal of maximizing access to critical research.

Localization of Neuropeptide Y-like Immunoreactivity in the Saccus Vasculosus of Cartilaginous and Bony Fishes

Akira Chiba¹, Young Chang Sohn², Shunya Oka¹ and Yoshiharu Honma²

¹Department of Biology, School of Dentistry at Niigata, Nippon Dental University, Niigata 951, and ²Faculty of Science, Niigata University, Niigata 950-21, Japan

ABSTRACT—The distribution of perikarya and fibers containing neuropeptide Y (NPY)-like immunoreactant was studied in the saccus vasculosus of cartilaginous and bony fishes by immunohistochemistry using streptavidin-biotin technique. NPY-positive fibers were demonstrated in most of the 20 species examined, although the density of the fibers varied among the species. In the white sturgeon, *Acipenser transmontanus*, NPY-positive varicose fibers formed a supraependymal plexus. On the other hand, NPY-positive perikarya could be demonstrated in the ayu, *Plecoglossus altivelis*, in which an NPY-positive, presumed afferent fiber fascicle was encountered. These results suggest an involvement of NPY or related substance in the saccus vasculosus function and its regulation.

INTRODUCTION

The saccus vasculosus (SV), a highly vascularized choroidal organ peculiar to cartilaginous and bony fishes, contains three types of cells: coronet cells, cerebrospinal fluid (CSF)-contacting neurons, and supporting cells. Its precise function is still unsettled, although sensory (receptor), secretory or cation-transporting role has been proposed or hypothesized (Altner and Zimmermann, 1972). In the teleostean SV, the CSF-contacting neurons and their fibers are cholinergic (Zimmermann and Altner, 1970; Vigh *et al.*, 1972). These fibers comprise the afferent pathway known as the tractus sacci vasculosi, which joins the nervus sacci vasculosi to enter the paired nucleus, i.e., the nucleus (ganglion) sacci vasculosi, in the hypothalamus (Vigh *et al.*, 1972). No evidence for the presence of aminergic innervation of the SV has been obtained by the fluorescent histochemical (Fremberg *et al.*, 1977; Terlouw *et al.*, 1978; Watson, 1980) and immunohistochemical (Ritchie *et al.*, 1983; Ekström and van Veen, 1984; Meredith and Smeets, 1989; Roberts *et al.*, 1989; Yamanaka *et al.*, 1990) studies. So far, almost nothing is known on the peptidergic nerve elements in the SV (Chiba and Honma, 1994). In the present study, we examined immunohistochemically whether or not NPY-containing neurons might innervate the SV of cartilaginous and bony fishes.

MATERIALS AND METHODS

Twenty species of cartilaginous and bony fishes were used in this study (Table 1). Except for the white sturgeon, *Acipenser*

transmontanus, and the Senegal bichir, *Polypterus senegalus*, obtained through a local dealer, all the animals were collected from different localities in Japan, the waters of Sado Island on the Sea of Japan, and Sagami Bay in the Pacific. Under anesthesia with *m*-aminobenzoate-methanesulfonate (MS-222), their brains were quickly dissected out, immersed in Bouin's solution without acetic acid, dehydrated with graded ethanols, and embedded in paraffin. The brains were cut at 8–10 µm into sagittal or transverse sections. NPY-expressing perikarya and fibers were immunohistochemically stained by the streptavidin-biotin method with a commercial kit (Nichirei, Tokyo). Antiserum against synthetic porcine NPY (UCB Bioproducts, Belgium) was used as the primary antibody at a dilution of 1:3000. The immunoreaction was visualized by the diaminobenzidine method. The sections were washed, dehydrated, and mounted with Canada balsam. Specificity of the immunoreactions was determined by replacement of the primary antibody with (1) normal rabbit serum, (2) antiserum preabsorbed with the homologous antigen, i.e., synthetic porcine NPY (1 µM, Peninsula Laboratories, USA), or (3) antiserum pretreated with related peptides, i.e., synthetic avian pancreatic polypeptide (APP, 10 µM) and peptide YY (PYY; 10 µM). The immunoreactivity was absent in all sections treated with the control procedures (1) and (2), but was not abolished in those treated with the procedure (3).

RESULTS

NPY-like-immunoreactive (NPY-IR) fibers were demonstrated in the SV of most of the species examined, but their frequency or density showed considerable variation (Table 1). In the SV of two species of squaloid sharks, *Etmopterus brachyurus* and *Centrophorus squamosus*, no NPY-positive structures were detected, although the NPY-IR fibers and perikarya occurred in other brain areas. On the other

Table 1. Occurrence of NPY-like-immunoreactive perikarya and fibers in the saccus vasculosus of cartilaginous and bony fishes

Name of used animals	Number of specimens	Age	NPY-like immunoreactivity	
			Fibers	Perikarya
Chondrichthyes				
<i>Chimaera phantasma</i>	1	Ad	+	—
<i>Scyliorhinus torazame</i>	15	Ad	+	—
<i>Mustelus manazo</i>	4	Ad,Juv	++	—
<i>Etmopterus brachyurus</i>	2	Ad	—	—
<i>Centroscyms coelolepis</i>	2	Ad	+	—
<i>Centroscyms owstonii</i>	2	Ad	+	—
<i>Deania histricosa</i>	1	Ad	+	—
<i>Centrophorus squamosus</i>	1	Ad	—	—
<i>Raja kenojei</i>	6	Ad	+	—
<i>Dasyatis akajei</i>	5	Ad,Juv	+	—
Osteichthyes				
<i>Acipenser transmontanus</i>	3	Juv	+++	—
<i>Polypterus senegalus</i>	4	Ad	+	—
<i>Plecoglossus altivelis</i>	50	Ad	+++	++
<i>Salvelinus leucomaenis</i>	5	Ad	+	—
<i>Oncorhynchus keta</i>	23	Juv	+	—
<i>Oncorhynchus masou</i>	4	Juv	+	—
<i>Gasterosteus aculeatus</i>	7	Ad	++	—
<i>Sebastes oblongus</i>	2	Ad	+	—
<i>Cottus pollux</i>	3	Ad	+	—
<i>Aluterus scriptus</i>	1	Juv	+	—

Ad, adult; Juv, Juvenile

score: +++, frequent; ++, less frequent; +, infrequent; —, not detected

hand, the labeled fibers were common or frequent in the white sturgeon, *Acipenser transmontanus*, and the ayu, *Plecoglossus altivelis* (Table 1, Fig. 1A,B). In the *Acipenser* SV, NPY-IR varicose fibers were widely distributed as single fibers or thin strands within or beneath the epithelial (ependymal) layer, and occasionally found apposed to the vascular wall. Noticeably, the fibers running on or over the epithelial layer formed a plexus structure by joining each other or penetrated the epithelial layer (Fig. 1A). Some of the fibers in the *Acipenser* SV could be traced anteriorly to the hypophysis or dorsally to the posterior recess organ. In the *Plecoglossus* SV, NPY-IR fibers were frequently demonstrated as thin varicose fibers or branching strands of varying caliber (Fig. 1B). In some sections, these fibers and strands were grouped into a thick bundle and could be traced into the ventrocaudal portion of the posterior tubercle (Fig. 1B) including the nucleus sacci vasculosi. This definite pathway was identifiable as the tractus sacci vasculosi. On the other hand, in the SV of the gummy shark, *Mustelus manazo*, NPY-IR varicose fibers were detected in the thick nerve strand chiefly composed of NPY-negative fibers (Fig. 1C). Some labeled fibers ran into the layer of the coronet cells. In other species, NPY-IR fibers were infrequent and dispersed.

NPY-IR perikarya could be demonstrated only in the *Plecoglossus* SV. They were bottle-shaped and occurred solitarily or in loose groups within the epithelial layer (Fig. 1D). Occasionally, their apical swelling projected into the ventricular cavity, displaying a characteristic of CSF-contacting neurons

(Fig. 1E). The NPY-IR perikarya were seen more often in the animals caught in October, so far studied in 50 specimens caught during months from May to November.

DISCUSSION

The present study demonstrated that the SV of cartilaginous and bony fishes contain NPY-IR fibers, although the density of the fibers shows a considerable variation among the species. Factors or background ascribed to this variation is currently unknown, but the following possibilities or interpretations may be possible. First, this variation may represent different degree of innervation of the SV by the NPY-IR fibers, possibly reflecting the species-specific structural design of the SV. Second, this variation may be attributed to different amounts of the tissue antigen, possibly being related to procedures of tissue preparation, particularly the condition of fixation, and/or to physiological states of the animals. These points should be further investigated.

On the other hand, both NPY-IR perikarya and fibers were exceptionally demonstrated in the *Plecoglossus* SV. These perikarya were identified as CSF-contacting neurons as demonstrated in the hypothalamus of the cloudy dogfish and the white sturgeon (Chiba and Honma, 1992, 1994). CSF-contacting bipolar neurons in the SV are generally considered to supply the afferent tract which projects toward the hypothalamus (Altner and Zimmermann, 1972). Furthermore, the anatomical localization of the NPY-IR fiber fascicle in the

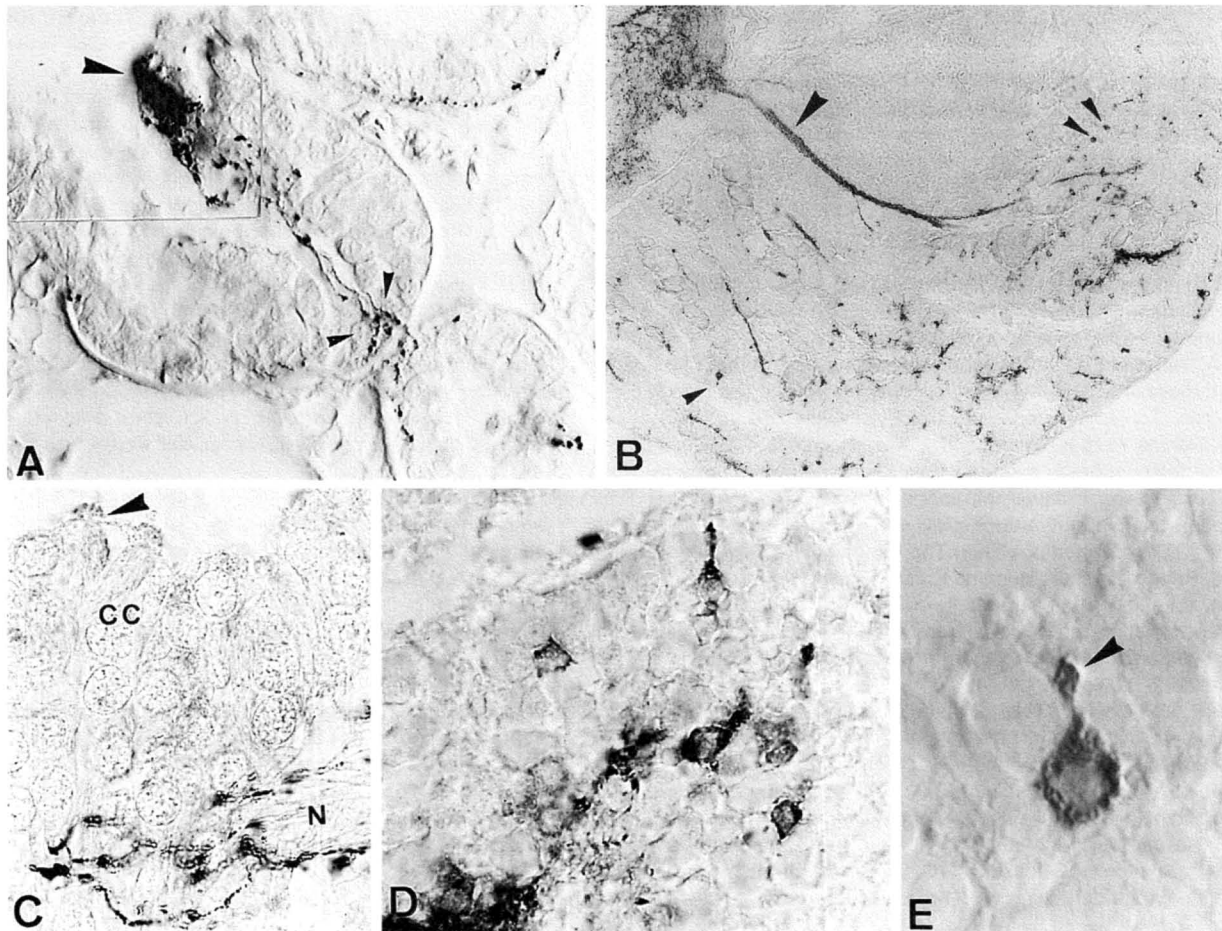


Fig. 1. (A) A part of the SV of the white sturgeon, *Acipenser transmontanus*, showing NPY-IR varicose fibers forming a supraependymal plexus (large arrowhead) or penetrating into the ependymal layer (small arrowheads). $\times 700$. (B) Paramedian section of the SV of the ayu, *Plecoglossus altivelis*, showing NPY-IR fibers and cells. Note a bundle of NPY-IR fibers corresponding to the tractus sacci vasculosi (large arrowhead) and immunostained cells (small arrowheads). Anterior to the left. $\times 200$. (C) A part of the SV of the gummy shark, *Mustelus manazo*, showing NPY-IR fibers arising from a thick bundle of nerve fibers (N). The arrowhead indicates intraventricular processes of the coronet cells (CC). $\times 1200$. (D) A part of the *Plecoglossus* SV showing NPY-IR cells. $\times 1000$. (E) An NPY-IR cell of the CSF-contacting type found in the *Plecoglossus* SV. Note the intraventricular apical swelling of the cell (arrowhead). $\times 1300$.

Plecoglossus SV appears to be identical with the tractus sacci vasculosi, the afferent tract demonstrated by silver impregnation (Altner and Zimmermann, 1972) or enzyme histochemistry (Vigh *et al.*, 1972). Therefore, we consider that in the *Plecoglossus* SV the majority of the NPY-IR fibers represent the afferent tract, although it cannot be ruled out that some of the NPY-IR fibers comprise the efferent tract. According to a review paper (Altner and Zimmermann, 1972), both tracts are common to elasmobranchs and also to teleosts. Additional experiments using the axonal tracers are required to determine whether NPY-IR fibers in the SV form the afferent and/or efferent pathway.

There is a growing body of data to show that NPY is one of the most abundant and widely distributed peptides in the central and peripheral nervous systems of higher vertebrates and acts as transmitter or modulator in the neural networks (Colmers and Whalestedt, 1993). In the light of such data, it is likely that NPY-like substance in the bipolar CSF-contacting

neurons and fibers in the *Plecoglossus* SV may also function as transmitter or modulator in the neuronal pathway of the SV. Thus, NPY-IR CSF-contacting neurons may be involved in the sensory function proposed for the SV (Altner and Zimmermann, 1972). On the other hand, apart from transmitter function of NPY, NPY-like substance in the fibers may be involved in the regulation of the SV function by hormonal action on the vascular system and epithelial (ependymal) layer of the SV. In this connection, recent information on the function of NPY, e.g., vasoconstrictory action reported in the dogfish cardiovascular system (Conlon *et al.*, 1991) and electrophysiological effects shown in the gut epithelium of teleosts (Kiliaan *et al.*, 1993) includes suggestions for future study. Further analyses are required to elucidate functional significance of NPY or related substance in the SV.

ACKNOWLEDGMENTS

We thank Dr. Koji Kobayashi of the Marine Science Museum of Tokai University and Mr. Yukihiro Nakamura, Director of the Johetsu Municipal Aquarium, for supplying materials. Thanks are extended to Mr. Yasuharu Iwata for his assistance in tissue preparation.

REFERENCES

- Altner H, Zimmermann H (1972) The saccus vasculosus. In "Structure and Function of Nervous Tissue Vol 5" Ed by GH Bourne, Academic Press, New York, pp 293–328
- Chiba A, Honma Y (1992) Distribution of neuropeptide Y-like immunoreactivity in the brain and hypophysis of the cloudy dogfish, *Scyliorhinus torazame*. *Cell Tissue Res* 268: 453–461
- Chiba A, Honma Y (1994) Neuropeptide Y-immunoreactive structures in the telencephalon and diencephalon of the white sturgeon, *Acipenser transmontanus*, with special regard to the hypothalamo-hypophyseal system. *Arch Histol Cytol* 57: 77–86
- Colmers WF, Whalestedt C (1993) The Biology of Neuropeptide Y and Related Peptide. Humana Press, Totawa, New Jersey
- Conlon, JM, Balasubramanian A, Hazon N (1991) Structural characterization and biological activity of a neuropeptide Y-related peptide from the dogfish, *Scyliorhinus canicula*. *Endocrinology* 128: 2272–2279
- Ekström P, Van Veen T (1984) Distribution of 5-hydroxytryptamine (serotonin) in the brain of the teleosts *Gasterosteus aculeatus* L. *J Comp Neurol* 226: 307–320
- Fremberg M, Van Veen T, Hartwig HG (1977) Formaldehyde induced fluorescence in the telencephalon and diencephalon of the eel. *Cell Tissue Res* 170: 1–20
- Kiliaan AJ, Holmgren S, Jönsson A C, Dekker K, Groot JA (1993) Neuropeptides in the intestine of two teleost species (*Oreochromis mossambicus*, *Carassius auratus*): localization and electrophysiological effects on the epithelium. *Cell Tissue Res* 271: 123–134
- Meredith GE, Smeets WJAJ (1989) Immunocytochemical analysis of the dopamine system in the forebrain and midbrain of *Raja radiata*: evidence for a substantia nigra and ventral tegmental area in cartilaginous fish. *J Comp Neurol* 265: 530–548
- Ritchie TC, Livingston CA, Hughes MG, McAdoo DJ, Leonard RB (1983) The distribution of serotonin in the CNS of an elasmobranch fish: immunohistochemical and biochemical studies in the Atlantic stingray, *Dasyatis sabina*. *J Comp Neurol* 221: 429–443
- Roberts BL, Meredith GE, Maslam S (1989) Immunohistochemical analysis of the dopamine system in the brain and spinal cord of the European eel, *Anguilla anguilla*. *Anat Embryol* 180: 401–412
- Terlou M, Ekengren B, Hiemstra K (1978) Localisation of monoamines in the forebrain of two salmonid species with special reference to the hypothalamo-hypophysial system. *Cell Tissue Res* 190: 417–434
- Vigh B, Vigh-Teichmann I, Aros B, Varjassy P (1972) Licht- und elektronen mikroskopische Untersuchungen des Saccus vasculosus und des Nervus und Tractus sacci vasculosi. *Z Zellforsch* 129: 508–522
- Watson AHD (1980) The distribution of aminergic neurones and their projections in the brain of the teleost, *Myoxocephalus scorpio*. *Cell Tissue Res* 208: 299–312
- Yamanaka S, Honma Y, Ueda S, Sano Y (1990) Immunohistochemical demonstration of serotonin neuron system in the central nervous system of the Japanese dogfish, *Scyliorhinus torazame* (Chondrichthyes). *J Hirnforsch* 31: 385–397
- Zimmermann H, Altner H (1970) Zur Charakterisierung neuronaler und gliöser Elemente im Epithel des Saccus vasculosus von Knochenfischen. *Z Zellforsch* 111: 106–126

(Received January 19, 1996 / Accepted March 25, 1996)