

Cuterebrosis in a Florida Horse: First Equid Record for North America

Author: Slansky, Frank

Source: Florida Entomologist, 90(4) : 795-797

Published By: Florida Entomological Society

URL: [https://doi.org/10.1653/0015-4040\(2007\)90\[795:CIAFHF\]2.0.CO;2](https://doi.org/10.1653/0015-4040(2007)90[795:CIAFHF]2.0.CO;2)

BioOne Complete (complete.BioOne.org) is a full-text database of 200 subscribed and open-access titles in the biological, ecological, and environmental sciences published by nonprofit societies, associations, museums, institutions, and presses.

Your use of this PDF, the BioOne Complete website, and all posted and associated content indicates your acceptance of BioOne's Terms of Use, available at www.bioone.org/terms-of-use.

Usage of BioOne Complete content is strictly limited to personal, educational, and non - commercial use. Commercial inquiries or rights and permissions requests should be directed to the individual publisher as copyright holder.

BioOne sees sustainable scholarly publishing as an inherently collaborative enterprise connecting authors, nonprofit publishers, academic institutions, research libraries, and research funders in the common goal of maximizing access to critical research.

CUTEREBROSIS IN A FLORIDA HORSE: FIRST EQUID RECORD FOR NORTH AMERICA

FRANK SLANSKY

Department of Entomology & Nematology, Bldg. 970 Natural Area Drive, University of Florida,
Gainesville, FL 32611; Current address: 14107 NW 61st Lane, Gainesville, FL 32653

Larvae of *Cuterebra* spp. (Diptera: Oestridae) typically infest mice, rats, chipmunks, rabbits, hares, and certain other rodents or lagomorphs native to the Americas (Sabrosky 1986). However, non-native members of these orders, as well as mammals in other orders such as artiodactyls (e.g., deer and pigs), carnivores (raccoons, domestic cats and dogs, etc.), and primates (humans), can be parasitized by these bot flies (Hall 1925; Sabrosky 1986; Baird et al. 1989; Glass et al. 1998; Harris et al. 2000; Suedmeyer et al. 2000; Safdar et al. 2003; Slansky & Huckabee 2006; Slansky 2007a). Infestation of these atypical or accidental hosts, an affliction termed cuterebrosis or cuterebriasis, occurs when they contact first instars of *Cuterebra* spp. newly hatched from eggs oviposited in the habitats of the typical hosts (Catts 1982; Slansky & Kenyon 2003).

Published cases of cuterebrosis in perissodactyls (donkeys, horses, zebras, etc.) are few and mostly unsubstantiated. Knipling & Bruce (1937) reported that a second instar of *Cuterebra buccata* (Fabricius), a lagomorph-infesting species, was removed from a mule in South Carolina (16-VII-1935), but they provided no justification for this species assignment. Second instar *Cuterebra* spp. are very difficult to identify visually to species (even currently) and there were no descriptions of second instars of other *Cuterebra* spp. for comparison at the time of Knipling & Bruce's (1937) report. Thus, I consider the assignment of *C. buccata* for their specimen as unsubstantiated. Dalmat (1942) indicated that asses (donkeys) were atypical hosts of *Cuterebra* spp., but no details were given. Similarly, Sabrosky (1986) mentioned mules as atypical hosts of these bot flies, but supportive information was not provided.

During curation of the immature insect collection in the Department of Entomology & Nematology at the University of Florida, an isopropanol-preserved larva that appeared to belong to a *Cuterebra* species was encountered. This specimen had been collected from beneath the hide of a horse in Marion Co., Florida (11-VII-1991). This specimen possesses characteristics typical of a third instar *Cuterebra* spp., including dark brown cuticular platelets covering its body (Fig. 1a), 2 pair of sensory tubercles and 2 sharply pointed mouth hooks on its head (Fig. 1b) and on its anal segment (Fig. 1c), 2 kidney-shaped spiracular plates, each containing 3 wedge-shaped sections with serpentine spiracular slits (Fig. 1c inset). The larva is coated with a substantial amount of

white material, which most likely is purulent matter from the host, as is often seen when these larvae infest atypical hosts (Slansky 2007b).

The species of *Cuterebra* that this specimen belongs to is unclear, as there are no taxonomic keys for species identification of larvae in this genus. However, the platelets covering its exterior either are ovoid, have blunt, single tips, or are multipointed, indicating this is a larva of a rodent-infesting *Cuterebra* species rather than that of a lagomorph-infesting species, third instars of which lack flattened, multipoint platelets and have many single-pointed, spine-like platelets (Knipling & Brody 1940; Dalmat 1942; Bennett 1955; Haas & Dicke 1958; Baird & Graham 1973; Slansky 2007a). There are three rodent-infesting species of *Cuterebra* in Florida: *C. americana* (Fabricius) (its main typical hosts are *Neotoma* woodrats), *C. fontinella* (Clark) (*Peromyscus* mice) and *C. emasculator* Fitch (*Sciurus* squirrels) (Slansky 2006). Cuticular platelet patterns are available only for the latter two species (Bennett 1955; Slansky & Huckabee 2006), and of these, this specimen more closely resembles *C. fontinella* (F.S., unpublished observations). However, determining the species of this specimen must await a morphological description of the third instar of *C. americana*, knowledge of intraspecific variation in morphological characteristics of these larvae (see Slansky & Huckabee, 2006), and/or molecular analyses (Otranto et al. 2003; Noel et al. 2004) of the candidate species.

This appears to be the first record for Florida of cuterebrosis in a horse or other perissodactyl, and the first such record for a horse in North America. Based on the scarcity of published reports, infestation of these animals by larvae of *Cuterebra* appears to be a very rare phenomenon that should pose little concern to horse owners. This contrasts with the common occurrence of larvae of *Gasterophilus* spp. bot flies, which use horses and other perissodactyls as typical hosts and can require treatment to avoid pathological effects (Wall & Shearer 1997; Catts & Mullen 2002). One might expect that these animals would be exposed to *Cuterebra* spp. larvae both while grazing, especially lagomorph-infesting species that likely oviposit in grassy areas (e.g., Suedmeyer et al. 2000), and in their stalls, especially rodent-infesting species that may inhabit barns (F. S., unpublished observations). Thus, the rarity of published reports of cuterebrosis in perissodactyls may indicate that these atypical hosts exhibit resistance to

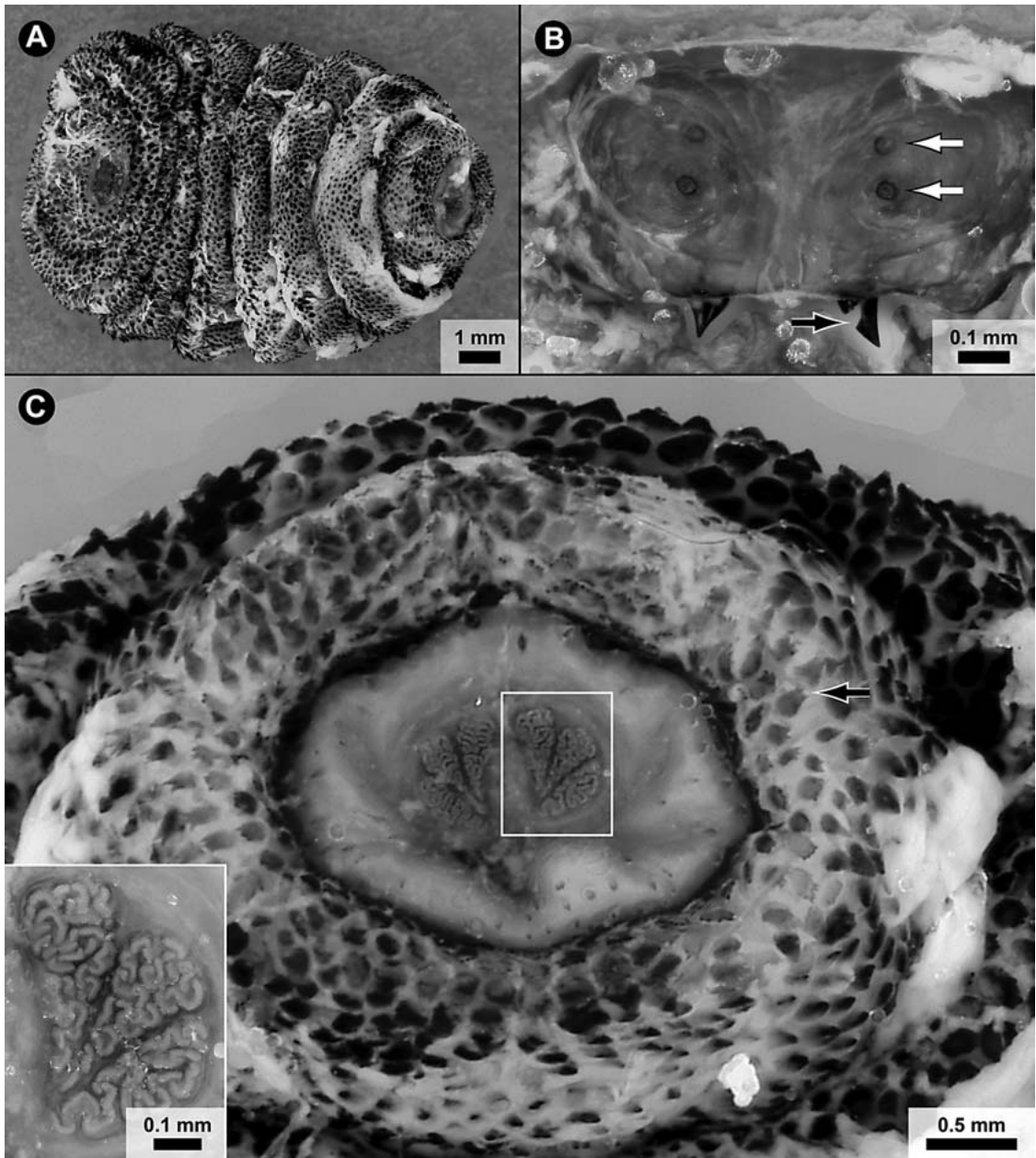


Fig. 1. Third instar *Cuterebra* spp. removed from a horse in Marion Co., Florida. (A) Entire larva (ventral; anterior to left); the white coating likely is purulent matter from the host. (B) Head (dorsal toward top), with 2 pairs of sensory tubercles (white arrows indicate 1 of each pair) on the 2 anterior lobes, and the 2 sharply pointed mouth hooks (black arrow indicates 1 of these). (C) Posterior end (dorsal toward top), with the 2 centrally located, kidney-shaped spiracular plates (the white box surrounds 1 of these) in the anal segment, which is retracted within the penultimate segment. Each spiracular plate contains 3 wedge-shaped sections with serpentine spiracular slits (inset). Arrow indicates 1 of the flat, multipoint cuticular platelets that are visible on the penultimate body segment.

parasitism by *Cuterebra* spp. larvae. Laboratory studies involving controlled infestations have shown that certain mammals outside the typical host spectrum of the *Cuterebra* spp. being tested

can exhibit partial to complete resistance (reviewed in Slansky 2007b). Of course, failure in publishing cases of cuterebrosis involving these animals could also contribute to the scarcity of

reports. A survey of large-animal veterinarians would be required to investigate the prevalence of cuterebrosis in these animals.

I thank Dr. Dale Habeck for bringing this specimen to my attention, Dr. Craig Welch for taking the photomicrographs used in this study, and Douglas Beckner for assistance in preparing the images. This work was supported in part by an instructional improvement grant from the College of Agricultural and Life Sciences at the University of Florida.

SUMMARY

A third instar of a rodent-infesting *Cuterebra* spp. removed from under the hide of a horse in Marion Co., Florida, is described and illustrated. This appears to be the first record for Florida of cuterebrosis in a horse or other perissodactyl, and the first such record for a horse in North America.

REFERENCES CITED

- BAIRD, C. R., AND C. L. GRAHAM. 1973. *Cuterebra tenebrosa*: Description of immature stages and a redescription of the adult (Diptera: Cuterebridae). Canadian Entomol. 105: 1281-1293.
- BAIRD, J. K., C. R. BAIRD, AND C. W. SABROSKY. 1989. North American cuterebrid myiasis. J. American Acad. Dermatol. 21: 763-772.
- BENNETT, G. F. 1955. Studies on *Cuterebra emasculator* Fitch 1856 (Diptera: Cuterebridae) and a discussion of the status of the genus *Cephenemyia* Ltr. 1818. Canadian J. Zool. 33: 75-98.
- CATTS, E. P. 1982. Biology of New World bot flies: Cuterebridae. Annu. Rev. Entomol. 27: 313-338.
- CATTS, E. P., AND G. R. MULLEN. 2002. Myiasis (Muscoidea, Oestroidea), pp. 317-348 In G. Mullen and L. Durden [eds.], Medical and Veterinary Entomology. Academic Press, San Diego. 597 pp.
- DALMAT, H. T. 1942. A new parasitic fly (Cuterebridae) from the northern white-footed mouse. J. New York Entomol. Soc. 50: 45-59.
- GLASS, E. N., A. M. CORNETTA, A. DELAHUNTA, S. A. CENTER, AND M. KENT. 1998. Clinical and clinicopathologic features in 11 cats with *Cuterebra* larvae myiasis of the central nervous system. J. Veterin. Intern. Med. 12: 365-368.
- HAAS, G. E., AND R. J. DICKE. 1958. On *Cuterebra horripilum* Clark (Diptera: Cuterebridae) parasitizing cottontail rabbits in Wisconsin. Parasitology 44: 527-540.
- HALL, M. C. 1925. The occurrence of cuterebrid larvae in dogs and cats, and the possible modes of infection. J. Econ. Entomol. 18: 331-335.
- HARRIS, B. P., P. E. MILLER, J. R. BLOSS, AND P. J. PEL-LITTERI. 2000. Ophthalmomyiasis interna anterior associated with *Cuterebra* spp in a cat. JAVMA 216: 352-355.
- KNIPLING, E. F., AND A. L. BRODY. 1940. Some taxonomic characters of cuterebrine (Diptera) larvae, with larval descriptions of two species from Georgia. J. Parasitol. 26: 33-43.
- KNIPLING, E. F., AND W. G. BRUCE. 1937. Three unusual host records for cuterebrine larvae (Diptera: Oestridae). Entomol. News 48: 156-158.
- NOEL, S., N. TESSIER, B. ANGERS, AND F.-J. LAPOINTE. 2004. Molecular identification of two species of myiasis-causing flies (*Cuterebra*) by multiplex PCR and RFLP. Med. Veterin. Entomol. 18: 161-166.
- OTRANTO, D., D. TRAVERSA, B. GUIDA, E. TARSITANO, P. FIORENTE, AND J. R. STEVENS. 2003. Molecular characterization of the mitochondrial cytochrome I gene of Oestridae species causing obligate myiasis. Med. Veterin. Entomol. 17: 307-315.
- SABROSKY, C. W. 1986. North American Species of *Cuterebra*, the Rabbit and Rodent Bot Flies (Diptera: Cuterebridae). Entomol. Soc. Amer. Thomas Say Foundation Monograph, College Park, MD. 240 pp.
- SAFDAR, N., D. K. YOUNG, AND D. ANDES. 2003. Autochthonous furuncular myiasis in the United States: case report and literature review. Clinical Infect. Dis. 36: 73-80.
- SLANSKY, F. 2006. *Cuterebra* bot flies (Diptera: Oestridae) and their indigenous hosts and potential hosts in Florida. Florida Entomol. 89: 152-160.
- SLANSKY, F. 2007a. Feline cuterebrosis caused by a lagomorph-infesting *Cuterebra* spp. larva. J. Parasitol. 93: 959-961.
- SLANSKY, F. 2007b. Insect/mammal associations: Effects of cuterebrid bot fly parasites on their hosts. Annu. Rev. Entomol. 52: 17-36.
- SLANSKY, F., AND J. HUCKABEE. 2006. First records of rodent-infesting *Cuterebra* bot flies parasitizing raccoons (*Procyon lotor*) in North America. J. Parasitol. 92: 126-130.
- SLANSKY, F., AND L. R. KENYON. 2003. *Cuterebra* bot fly infestation of rodents and lagomorphs. J. Wildlife Rehab. 26 (3): 7-16.
- SUEDMEYER, W. K., E. P. CATTS, AND E. GREINER. 2000. *Cuterebra* myiasis in a group of red kangaroos (*Megaleia rufa*), a Bennett's wallaby (*Macropus rufogriseus fruticulus*) and a Gunther's dik dik (*Malotia guentheri smithi*). J. Zoo Wildlife Med. 31: 124-128.
- WALL, R., AND D. SHEARER. 1997. Veterinary Parasitology. Chapman & Hall, London. 439 pp.